



Case Report

## Gastroschisis with Skeletal Deformities: A Case Report with Review of Literature

Nirmaladevi M<sup>1</sup>, Mathivanan D<sup>2</sup>, Sandhya Kurup<sup>3</sup>

<sup>1</sup>Associate Professor, <sup>2</sup>Postgraduate Student, Dept. of Anatomy, PSG IMS & R, Coimbatore, Tamilnadu, India.

<sup>3</sup>Professor, Dept. of Anatomy, MOSC Medical College, Kolenchery, Kerala, India - 682311

Corresponding Author: Nirmaladevi M

Received: 15/12/2014

Revised: 12/01/2015

Accepted: 19/01/2015

### ABSTRACT

Eviscerated organs not covered by normal skin are known as congenital abdominal wall defects. Among the three types of congenital abdominal wall defects, Gastroschisis is one of the severe forms with an incidence of 1 in 4000 live births. Usually it is not associated with any other major congenital malformations especially skeletal deformities and that is the reason for increase in survival rate after early detection and treatment. Since the case we are presenting had Gastroschisis along with skeletal deformities which are rare we would like to present this along with review of literature.

**Key Words:** Gastroschisis, extragastrintestinal, congenital malformations, skeletal deformities.

### INTRODUCTION

Gastroschisis (gaster+schisis, fissure or division) also known as laparoschisis <sup>(1)</sup> is an anterior abdominal wall defect in the paraumbilical area, mostly on right side with an incidence of 1 of 4000 births. <sup>(1,2)</sup> The defect is not covered by Sac and the rectus muscles meet in the midline at the xiphoid. It is associated with low maternal age (<20 years). <sup>(1,3)</sup> This is an embryological developmental defect with male predominance. <sup>(4)</sup> This condition is usually associated with evisceration of abdominal organs but with rare extragastrintestinal manifestations (10 %- 20%). <sup>(1,3)</sup> If so pentalogy of Cantrell, limb body wall

complex, other cardiac and genitourinary involvement should be considered. <sup>(2)</sup>

During the third week the embryonic disc develops head and tail folds. The organogenesis takes place during this period. There are two theories regarding the formation of gastroschisis. One theory suggests that involution of the right umbilical vein causes necrosis in the abdominal wall when physiological umbilical hernia is formed, leading to a right-sided defect. The second theory states that the right omphalomesenteric or vitelline artery prematurely involutes causing a weakening in the abdominal wall through which the intestinal contents protrudes out. <sup>(1,10)</sup>

The defect usually measures about 3 to 4 cm. The organs are not enclosed in membranes; hence the organs are free floating in the amniotic fluid resulting in perivisceritis, perivisceral adhesions, pseudomembranous covering, short mesentery, poor peristalsis and significant nutrient absorption imbalance. <sup>(1)</sup>

Left sided gastroschisis have also been reported for about 20 cases. <sup>(5,6)</sup> Two types simple and complex gastroschisis have been discussed. <sup>(7)</sup> Simple gastroschisis is uncompromised bowel whereas complex is, bowel with necrosis, atresia and perforation. In this study we aimed at describing a case of right sided gastroschisis which is simple with skeletal deformities.

The presence of Gastroschisis can be diagnosed by elevated levels of  $\alpha$ -fetoprotein in early weeks and by floating bowel loops in abdomen by ultrasound at around 10 weeks of gestation. Use of aspirin, ibuprofen, pseudoephedrine, alcohol, smoking during first trimester period has strong association. No

chromosomal anomalies associated with gastroschisis were reported <sup>(1)</sup> till now.

## CASE REPORT

We received a dead male foetus of 20 weeks gestation from the department of obstetrics and gynaecology. On examining the foetus, we found the defect of gastroschisis with skeletal abnormalities. The abnormalities were studied in detail and photographs were taken. The diagnosis was confirmed with the radiological images showing the right sided gastroschisis with CTEV and kyphoscoliosis. (Fig 3, 4)

## Observation

The defect is paraumbilical with evisceration of stomach, liver, gall bladder, small bowel loops, large bowel loops which were normal, no membranous covering, no cardiac and urogenital involvement but associated with kyphosis and scoliosis towards right side with congenital talipes equino varus (CTEV) on left side. (Fig 1, 2).

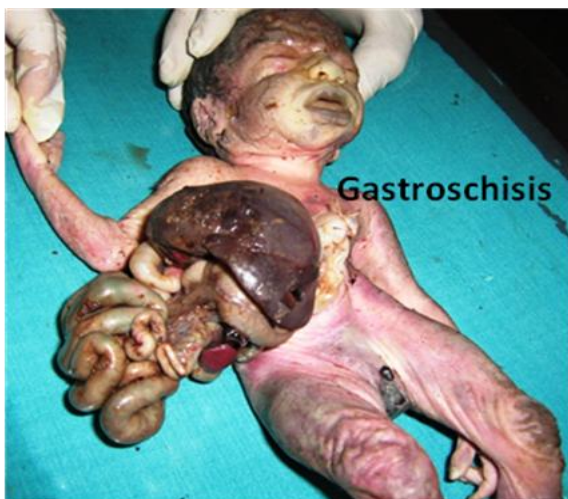

Fig 1: Right sided Gastroschisis.

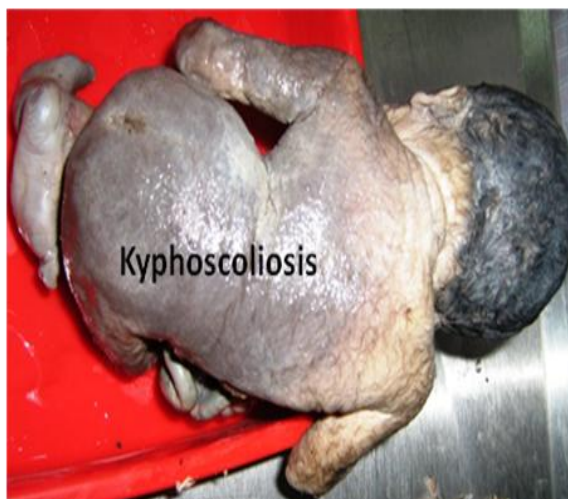

Fig 2: Kyphoscoliosis.

## DISCUSSION

According to Susan Standing in Gray's Anatomy "Gastroschisis is a paraumbilical, anterior abdominal defect,

common among low maternal age group (<20 years) with evisceration of abdominal organs. By USG examination gastroschisis should be differentiated from exomphalos.

The possible etiology may be periumbilical ischemia due to umbilical veins or arteries

infarct". (3)

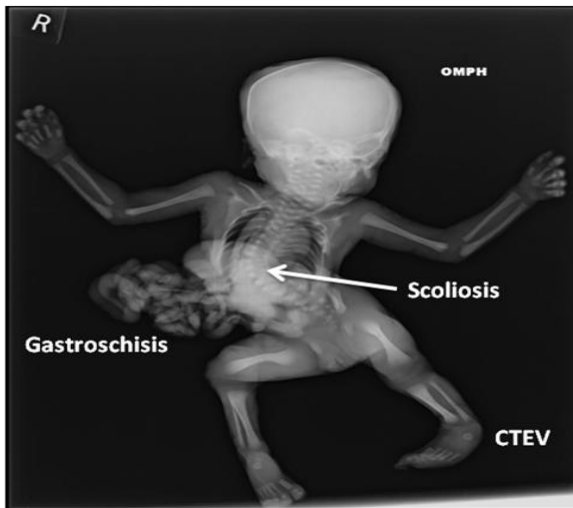


Fig 3: X-ray showing Right sided Gastroschisis, CTEV & Scoliosis.

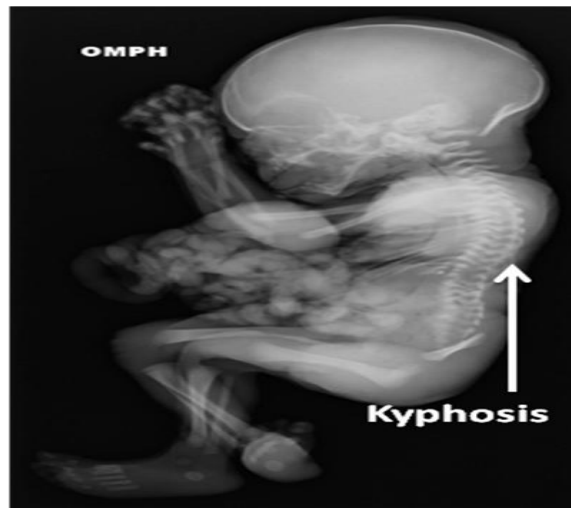


Fig 4: X-ray showing Kyphosis.

Singal R et al (Aug,2011) reported a case of “omphalocele and gastroschisis associated with multiple congenital abnormalities” in which the baby had spinal deformity, imperforate anus, congenital talipes equino varus (CTEV), esophageal fistula, webbing of neck, left upper limb cyanosis with gastroschisis and omphalocele. (8)

In Sep 2011 Bradnock TJ et.al in his study “Gastroschisis : one year outcomes from national cohort study” states that among the two types of gastroschisis , the simple and the complex , the babies with complex gastroschisis suffer longer to reach full enteral feeding and they developed liver failure with intestinal failure and per se the intestinal failure. Simple gastroschisis involved primary fascial closure and preformed silo while complex gastroschisis involves unplanned re-operation and prolonged hospital stay. (7)

Shi Y et al (March 2012) reported a case of “left sided gastroschisis with placenta findings” in which the abdominal wall defect was on the left paraumbilical area with eviscerated liver, stomach, small

intestine, colon and spleen. Post-mortem genomic hybridisation did not reveal any specific genetic abnormality. Left sided gastroschisis may be due to obliteration of left umbilical vein. The organs were not covered by membrane, the defect was paraumbilical not umbilical and so omphalocele was ruled out. Pulmonary hypoplasia, scoliosis and ventricular septal defect were also associated. (6)

In December 2012 Meena D and Verma AP described a paraumbilical defect with herniation of stomach, small and large bowel loops, liver, gall bladder and right kidney. Lower limb anomalies were short thin left femur, left tibia, left fibula and spina bifida of cervical and lumbar vertebrae. Both the feet were rudimentary. Left iliac bone was rudimentary. Umbilical cord was short, had two vessels. This case was confirmed as gastroschisis because of absence of covering and no genetic predisposition. (2)

“Left side gastroschisis: A rare congenital anomaly” a case report by Mandeli A et al (October 2013) states in his discussion that out of 20 reported cases of

left sided gastroschisis, 13 were primarily closed, 9 had major anomalies, 1 had situs inversus, 2 had defect in the flanks and in his case he visualised patent ductus arteriosus associated with left sided gastroschisis. He also added a note on silo procedure. <sup>(1)</sup>

A general report submitted by Ionescu et al (Jan 2014) stated difference between omphalocele and Gastroschisis, because always the two entities are grouped together. They revealed that etiopathology, associated anomalies, therapeutic approach and results were different for the two entities. In exomphalos the defect is central between the rectus abdominus with the umbilical cord inserted to middle. The defect was membrane covered and of 2-3 cm. Gastroschisis the defect is 3-4 cm with paraumbilical location and the organs being not membrane covered. Their study supports the periumbilical ischemia. Omphalocele is associated with many complex anomalies with genetic inclusion where as gastroschisis mostly stands unique. USG in second trimester reveals these defects, AFP is increased in gastroschisis than omphalocele, acetyl choline esterase is an enzyme increased in omphalocele than gastroschisis. Membrane covering is seen in omphalocele whereas it is absent in gastroschisis. <sup>(1)</sup>

Bruck syndrome associated with gastroschisis was reported by Afsarlar et al. A baby girl with gastroschisis associated with jejunal perforation in addition to bone fractures and joint contractures conclusive of bruck syndrome was explained. This is unique because of complex anomalies and genetic leaning of gastroschisis. <sup>(4)</sup>

According to Randall T. Loder and Jean-Paul Guiboux (1993) in their study of 66 cases of gastroschisis & omphalocele, the spinal deformities were present in one child with gastroschisis and three children with omphalocele. The child with a gastroschisis had a thoracolumbar scoliosis (T6-L3)

without any congenital vertebral malformations. <sup>(9)</sup>

In the present case the defect is paraumbilical with evisceration of stomach, liver, gall bladder, small bowel loops, large bowel loops which were normal, no membranous covering, no cardiac and urogenital involvement but associated with kyphosis and scoliosis towards right side with congenital talipes equino varus (CTEV) on left side. Because of its unique presentation and not correlating with the findings of previous studies it is presented.

## CONCLUSION

The presenting case was right sided gastroschisis with skeletal deformities. Prenatal diagnosis of omphalocele and gastroschisis may influence timing, mode and location of delivery. We emphasize routine trimester scan should be done with expertise to rule out the abdominal wall defects diagnostically and for effective mode of termination of pregnancy by avoiding drastic complications.

## REFERENCES

1. Ionescu S, Mocanu M, Andrei B, Bunea B, Carstoveanu C, Gurita A, Tabacaru R, Licsandru E, S tanescu D, Selleh M. Differential diagnosis of abdominal wall defects—omphalocele versus Gastroschisis. *Chirurgia*.2014;109(1):7-14.
2. Dharmraj M and Verma AP. Gastroschisis associated with lower limb and spinal congenital anomalies. *J clin Neonatol*.2012 oct-dec; 1(4);217-220.
3. Gray H. pelvic girdle, gluteal region and thigh. in: Standing S, eds. Gray's anatomy, the anatomical basis of clinical practice, fortieth edition. London: churchill livingstone; 2008. P.1209
4. Afsarlar CE, Kendirci HNP, Erdogan D, Ozguner IF, Cavususoglu YH, Karaman A, Cetinkaya S. The first case of bruck syndrome associated with gastroschisis.

- The Turkish Journal Of Pediatrics 2013; 55:651-654.
5. Mandelia A, Agarwala S, Sharma N, Solanki S, Panda S. Left sided gastroschisis: A rare congenital anomaly. J Clin Diagn Res.Oct 2013;7(10):2300-2302.
  6. Shi Y, Fairnelli CK, Chang MS, Carpenter PM. Left sided gastroschisis with placental findings. Int J Clin Exp Pathol.2012;5(3):243-246.
  7. Bradnoch TJ,Marven S, Owen A, Johnson P, Kurinczuck JJ, Spark P, Draper ES, Knight M. Gastroschisis: one year outcomes from national cohort study.BMJ.2011;343:d67 49.
  8. Singal R, Garg LN, Singal RP, Gupta S, Shahi SR, Singal S, Singh B. Omphalocele and gastroschisis associated with multiple congenital abnormalities. J Med Life. Aug 15 2011;4(3): 295 -296.
  9. Randall T. Loder and Jean-Paul Guiboux Musculoskeletal Involvement in Children With Gastroschisis and Omphalocele *JournalofPediatric Surgery*, Vol28. No 4 (April), 1993: pp 584-590.
  10. Emily R. Christison-Lagay a, Cassandra M. Kelleher b, Jacob C. Langer a, Seminars in Fetal & Neonatal Medicine 16 (2011) 164e172.

How to cite this article: Nirmaladevi M, Mathivanan D, Kurup S. Gastroschisis with skeletal deformities - a case report with review of literature. Int J Health Sci Res. 2015; 5(2):402-406.

\*\*\*\*\*

#### **International Journal of Health Sciences & Research (IJHSR)**

#### **Publish your work in this journal**

The International Journal of Health Sciences & Research is a multidisciplinary indexed open access double-blind peer-reviewed international journal that publishes original research articles from all areas of health sciences and allied branches. This monthly journal is characterised by rapid publication of reviews, original research and case reports across all the fields of health sciences. The details of journal are available on its official website ([www.ijhsr.org](http://www.ijhsr.org)).

Submit your manuscript by email: [editor.ijhsr@gmail.com](mailto:editor.ijhsr@gmail.com) OR [editor.ijhsr@yahoo.com](mailto:editor.ijhsr@yahoo.com)