



Case Report

## Giant Cell Tumor of Proximal Fibula Treated With En Block Resection: A Case Report

Rohan S. Patil<sup>1</sup>, K. A. Saindane<sup>2</sup>, Ajay P. Surwade<sup>1</sup>, Sagar S. Chinchole<sup>1</sup>

<sup>1</sup>Resident, <sup>2</sup>Associate Professor,  
Department of Orthopaedics, ACPM Medical College, Dhule, Maharashtra, India

Corresponding Author: Rohan S. Patil

Received: 27/11/2014

Revised: 25/12/2014

Accepted: 29/12/2014

### ABSTRACT

A 37 year old female with pain & swelling in left knee since 3 months, suggestive of Giant cell tumor was treated with En block resection of proximal fibula. GCT is locally aggressive and destructive lesion. Tumor is notorious for high recurrence rates. To reduce the high recurrence rate the tumor can be treated with En block resection if the site is located in expendable bones such as proximal fibula, distal ulna, proximal radius, coccyx & sacrum. Sample sent for Histopathology examination was consistent with diagnosis of giant cell tumor. Patient started weight bearing 3 weeks after surgery. No recurrence has been noticed in 5<sup>1/2</sup> year of follow up.

**Keywords:** Giant cell tumor, Proximal fibula, En block resection

### INTRODUCTION

Giant cell tumor is seen in 3% to 5% of all bone tumors. It occurs in age group between 20 to 40 years. More common in females. Its activity ranges from borderline to malignant lesion. It is locally aggressive and destructive lesion. Giant cell tumor arises from epiphyses of long bones. Most common sites being proximal tibia, distal femur, distal radius. Radiographically its seen as expansile exophytic mass. <sup>[1]</sup> GCT is notorious for high recurrence rates. To reduce the high recurrence rate the tumor can be treated with En block Resection if the site is located in expendable bones such as proximal fibula, distal ulna, proximal radius, coccyx & sacrum. <sup>[2-5]</sup> Here is such one case of giant cell tumor of proximal fibula treated

with En block resection. After 5<sup>1/2</sup> year of follow up no recurrence has been seen with normal range of motion at knee joint.

### CASE REPORT

37 year old female presented to the OPD with complaints of pain & swelling in left knee for 3 months. There was no history of trauma or fever. On local examination there was a firm non tender well defined swelling arising from proximal fibula. There was no crepitus, no tenderness and knee range of movement was slightly restricted. On X ray eccentric exophytic epiphyseal mass was seen in proximal aspect of left fibula (figure 1). There was no joint invasion. Chest x ray of the patient was normal. We advised MRI of Knee joint to

the patient, but she was not affording the investigation. An Incisional Biopsy (figure 3) confirmed the diagnosis of Giant Cell tumor of Proximal Fibula. With this diagnosis, treatment of giant cell tumor was planned. Tumor was treated with resection of proximal fibula. Sample was sent for histopathological examination.

thereafter for every 3 months. X ray knee was taken on every follow up to see any evidence of recurrence. No recurrence has been seen in 51/2 years of follow up (figure 4).

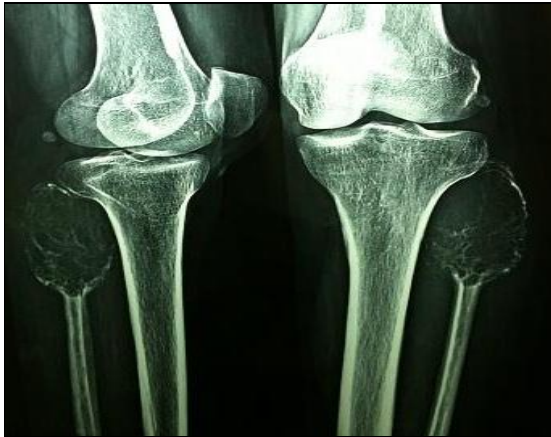

Figure 1 Pre Op X-Ray

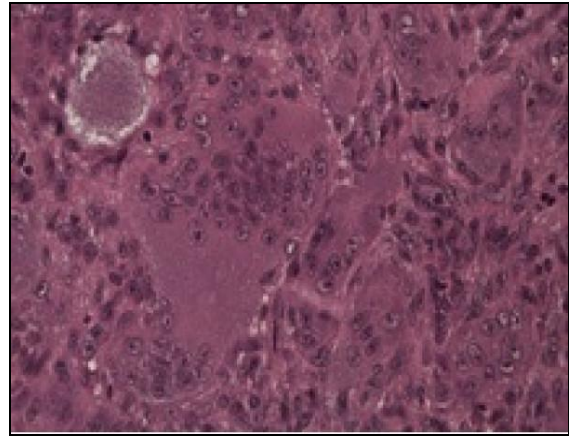


Figure 3 Biopsy Image

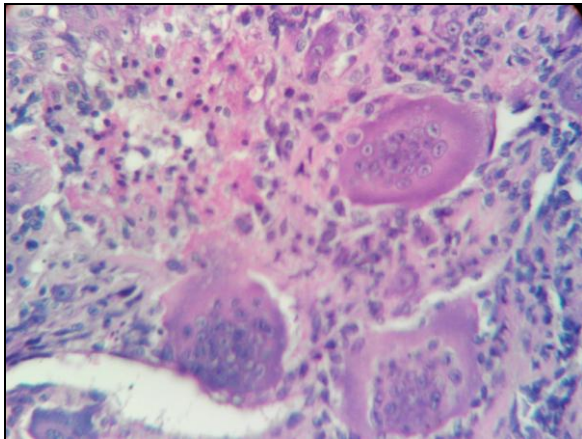


Figure 2 Microscopic Picture

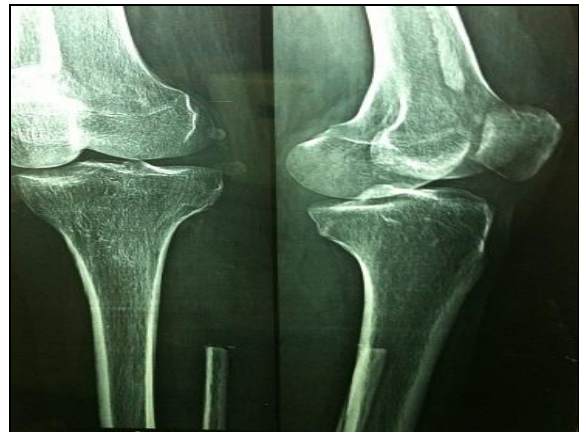

Figure 4 Post Op X-Ray

Microscopy was consistent with the diagnosis of giant cell tumor. Multinucleated giant cells with oval shaped stromal cells were seen (figure 2). There was no evidence of wound infection in post operative period. Patient was discharged after suture removal. Patient could comfortably bear weight after 3 weeks of surgery with full range of knee movement (figure 5 & 6). Patient was followed up every month for 3 months and

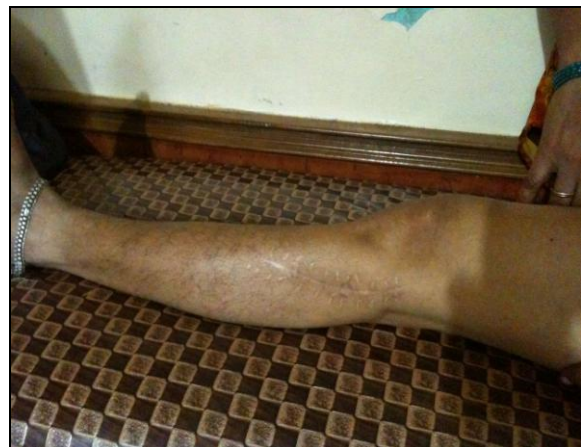

Figure 5 Range Of Motion at Knee (Full Extension)

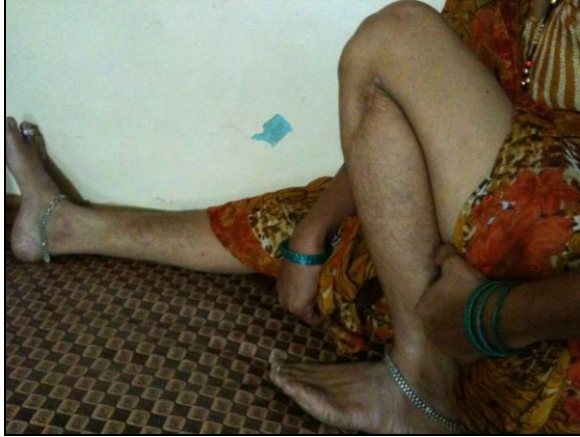

Figure 6 Range Of Motion at Knee (Full Flexion)

## DISCUSSION

Giant Cell Tumor is a rare tumor, which is essentially benign but may behave unexpectedly, regardless of radiological or histological examinations. [6] GCT represents 3 to 5% of all tumors of bone and 21% of benign bone tumors. In 70% cases, tumor involves women in 3<sup>rd</sup> or 4<sup>th</sup> decade of life. The tumor arises from the meta-epiphysis of long bone, grows as an expansile exophytic mass. [6,7] Being grey to reddish brown in colour, it is composed of soft vascular friable tissue. Microscopically it consists of Multinucleated Giant Cells scattered in vascularised network of proliferating round, oval or spindle shaped cells surrounding by indistinct cytoplasm. Tumor is notorious for recurrences, for this reason there are various modalities of treatment available for tumor to prevent re occurring it. [6-8]

In case distal ulna, proximal radius, proximal fibula, coccyx, sacrum; resection of involved bone is performed. [10]

For distal femur, proximal tibia, distal radius; Bone cement or Bone graft or combination is used. For larger tumours around knee joint reconstruction with technique like Turn O Plasty is used. [10,11]

Some aggressive and recurrent tumours may require amputation. Chemotherapy and Radiotherapy is used for unresectable malignant tumours. [12]

Adjuvant therapies used to reduce recurrences.

All methods have their own advantages & disadvantages. Surgical resection of the tumor has shown low recurrence rate compared to other modalities with no requirement of any secondary surgical procedure. [13,14]

While drawback of resection are, possibility of post operative peroneal nerve palsy and knee instability because of proximity of peroneal nerve & lateral collateral ligament with head of fibula.

## CONCLUSION

The main primary treatment of GCT is Surgery, the type of which depends on following variables:

1. Location of tumor
2. Size of tumor
3. Biological activity of tumor
4. Recurrence
5. Evidence of pathological fracture [9] along with the investigations like plain X-Ray, MRI or Biopsy to define tumor grade.

Resection is recommended for stages I B and II B, extremely large lesions and in cases of expendable bones where resection results in no significant morbidity like proximal fibula, distal ulna and flat bones. Curettage alone results in high recurrence. Amputation is preserved for massive recurrence and malignant transformation.

## REFERENCES

1. Canale ST, Beaty JH. Campbells Operative Orthopaedics. 11<sup>th</sup> edition. 2007. Volume 1, page no 883-886.
2. Erler K, Demiralp B, Ozdemir T, Basbozkurt M. Treatment of proximal fibular tumors with en bloc resection. *Knee*. 2004;11: 489-496.
3. Malawer MM. Surgical management of aggressive and malignant tumors of the proximal fibula. *Clinical Orthopaedics Related Research*. 1984;186: 172-181

4. Dr Ajay Purie, Dr. M.G.Agrawal. Current concepts in bone and soft tissue tumor. first edition.
5. Faezypour H, Davis AM, Griffin AM, Bell RS. Giant cell tumor of the proximal fibula: surgical management. *Journal Surgery Oncology*. 1996; 61:34–37.
6. Samuel L Turek. *Tureks Orthopaedis Principles and their Application*. 4<sup>th</sup> edition 2000. Volume 1, page no 615-620.
7. Enneking WF. A system of staging musculoskeletal neoplasms. 1986, 204: 9-24
8. Tunn PU, Schlag PM. Giant cell tumor of bone, An evaluation of 87 patients. *Z Orthop Ihre Grenzgeb*. 2003 Nov-Dec. 141(6):690-8.
9. Sung HW, Kuo DP, Shu WP, Chai YB, Liu CC, Li SM: Giant-cell tumor of bone: analysis of two hundred and eight cases in Chinese patients. *Journal Bone Joint Surgery Am*. 1982, 64:755-761.
10. Daniele Vanni, Andrea Pantalone, Elda Andreoli, Patrizio Caldora, Vincenzo Salini. Giant Cell Tumor of distal ulna a case report. *Journal of Medical case reports*. 2012. 6:143.
11. Dahlin DC. Caldwell Lecture. Giant cell tumor of bone: Highlights of 407 cases. *AJR Am J Roentgenol*.1985, 144: 955-60.
12. Bennet Jr CJ, Marcus Jr RB, Million RR, Enneking WF. Radiation therapy for giant cell tumor of bone. *Int J Radiat Oncol Biol Phys*. 1993, 26: 299-304.
13. Campanacci M, Baldini N, Boriani S, Sudanese. A.Giant cell tumor of bone. *J Bone Joint Surg Am*. 1987,69: 106-14.
14. Dahlin DC, Cupps RE, Johnson EWJr. Giant cell tumor: A study of 195 cases. *Cancer*. 1970, 25: 1061-70.

How to cite this article: Patil RS, Saindane KA, Surwade AP et. al. Giant cell tumor of proximal fibula treated with en block resection: a case report. *Int J Health Sci Res*. 2015; 5(1):398-401.

\*\*\*\*\*