

Case Report

Extra-Ocular Sebaceous Carcinoma: A Case Report

Nidhi Awasthi

Former Assistant Professor (Pathology), Hind Institute of Medical Sciences, Barabanki, UP, India.

Received: 25/11/2014

Revised: 15/12/2014

Accepted: 17/12/2014

ABSTRACT

Skin adnexal neoplasms constitute a diverse group of benign and malignant tumors derived from one or more types of adnexal epithelium found in normal skin: pilo-sebaceous units, eccrine and apocrine glands. Sebaceous carcinoma is a rare aggressive cutaneous malignancy seen predominantly in and around the ocular region. Extra ocular sebaceous carcinoma is rarer and presents a diagnostic challenge for both the clinicians as well as the pathologists. However, diagnosing these tumors has important implications because of its close association with Muir Torre Syndrome.

Key Words: Extra-ocular Sebaceous Carcinoma, Adnexal tumor, Muir Torre Syndrome.

INTRODUCTION

Sebaceous carcinomas are uncommon cutaneous appendageal tumors occurring most commonly in the ocular region, the extra ocular variant is much rarer. These tumors are known for their varied presentations both clinically and histologically which is a major cause of delayed diagnosis and management of these cases. I, hereby present a case of an Extra-ocular Sebaceous Carcinoma which masqueraded clinically as a benign cystic lesion along with a brief review of literature.

CASE REPORT

A 63 year old male presented to the surgical outpatient department with a 3 year history of a gradually increasing swelling over the left lateral chest wall. It was causing discomfort in lying down position but was otherwise asymptomatic. His past medical and family history were unremarkable. Local examination revealed a

soft to firm, non-tender, mobile swelling measuring approximately 6x5 cm. Overlying skin was unremarkable. There was no evidence of any lymphadenopathy. A clinical diagnosis of benign cystic lesion was made. The swelling was completely excised and sent for histopathological examination.

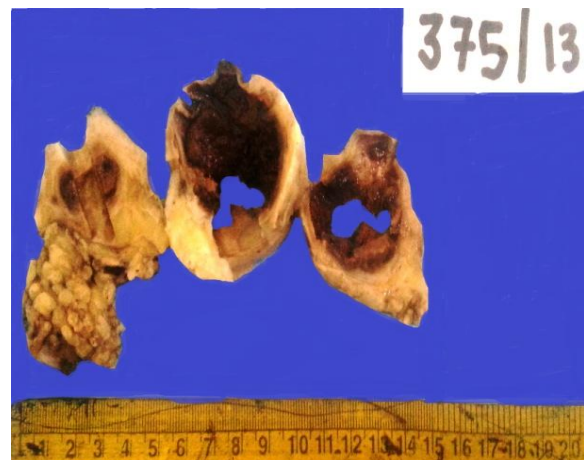

Figure 1: Gross Appearance

Macroscopic examination showed a single globular skin covered mass measuring 8x5x3 cm. Overlying skin was unremarkable. Serial cuts showed a reddish brown hemorrhagic lesion with a small tan white area at periphery measuring 5x4x2 cm. All resection margins appeared grossly free. [Fig.1]

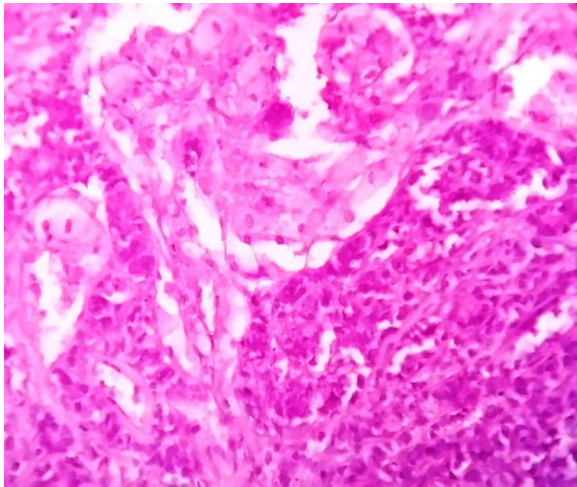


Figure 2: tumor composed predominantly of undifferentiated basaloid cells with focal sebocytic differentiation. haematoxylin and eosin x 400.

Microscopic examination showed a partially encapsulated solid-cystic neoplasm in the dermis composed predominantly of lobules of proliferating undifferentiated basaloid cells with abrupt differentiation into cells with copious amounts of vacuolated cytoplasm characteristic of sebocytes in the centre of the lobules. [Fig.2] Mild cytological atypia was evident in both components along with few mitoses. Large areas of necrosis and hemorrhage were seen along with fair number of cystic spaces containing eosinophilic material. Local invasion of deeper dermis was evident along with perineural invasion. [Fig.3] Periodic acid Schiff stain was negative. Immunohistochemistry for EMA showed focal immunoreactivity. [Fig.4] Considering the histomorphological and immunohistochemistry features a diagnosis of low grade sebaceous carcinoma was rendered and screening was advised to

rule out any underlying visceral malignancy due to close association of sebaceous neoplasms with Muir-Torre Syndrome. The post operative period was uneventful and the patient was doing well after 3 months of surgery.

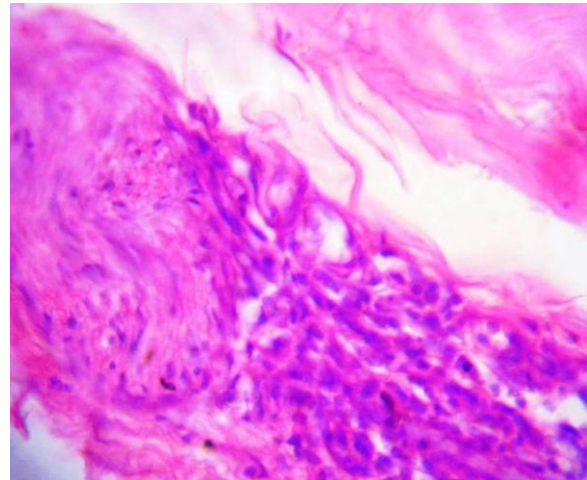


Figure 3: perineural invasion. Haematoxylin and eosin x 400.

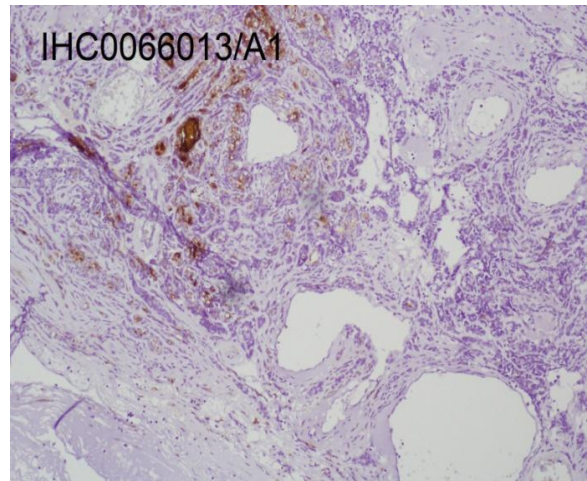


Figure 4: focal immunoreactivity for EMA on IHC.

DISCUSSION

Sebaceous carcinoma first described by Allaire in 1891, [1,2] is an aggressive uncommon adnexal tumor constituting less than 1% of all cutaneous malignancies. [1,3,4] Historically they have been separated into ocular and extra-ocular classes with the former accounting for about 75% of all reported cases. [1-3] It predominantly

involves elderly male ^[5,6] population with a median age of 73 years at the time of diagnosis. ^[3,6] Extra-ocular sites of disease from the most common to the least common include the skin of face, trunk, scalp and neck, upper limb and shoulder, external ear, lower limb and hip, lip, parotid gland, descending colon, nasal cavity, genitals and reproductive organs. ^[6] In the present case patient was a 63 year old male who presented with a lesion over the left lateral chest wall.

The etiology of sebaceous carcinoma is not entirely known. Cases may occur sporadically, ^[3] follow ionizing radiation therapy and may occur in patients with the familial autosomal dominantly inherited disorder Muir-Torre Syndrome characterized by hereditary association of sebaceous neoplasms and internal malignancy. ^[1-3,5,7,8] Screening of our patient was advised to rule out any underlying visceral malignancies.

The clinical presentation of sebaceous carcinoma is not pathognomonic and a pre-operative clinical diagnosis of sebaceous carcinoma is made initially in only one-third of cases. ^[9] Histologically, sebaceous carcinoma may present a variable morphologic spectrum including basaloid, squamoid, organoid, pseudo-neuroendocrine, carcinoid like and more recently rippled. ^[1,2,4,8] The diagnostic feature however is the presence of sebocytic differentiation characterized by the presence of foamy, multi-vacuolated cytoplasm ^[8] and demonstration of fat in vacuolated tumor cells ^[9] on frozen sections by means of special stains such as Oil red O and Sudan Black. ^[10] This was not performed in our case as the specimen had already been fixed in formalin. The differential diagnosis included Sebaceoma, Basal Cell Carcinoma with sebaceous differentiation, Clear cell SCC and metastatic clear cell tumors. Periodic acid Schiff stain was done which

was negative which ruled out SCC with hydropic change.

Sebaceous carcinoma cells express IHC markers such as CK, BerEP4, EMA, CAM 5.2, androgen receptor and adipophilin. ^[3] The current case showed focal immunoreactivity for EMA in cells with sebaceous differentiation. The vacuolated cytoplasm accentuated by the EMA stain is a characteristic feature of sebaceous carcinoma. ^[1,8,10]

Sebaceous carcinoma is an aggressive malignancy with local recurrence rates ranging between 9 to 36 % in 5 years with surgical excision. Nodal metastases have been described in approximately 8-28% of cases ^[3] with distant metastases occurring in about 20 – 25 % of cases. ^[8] Mortality rate varies from 9 to 50%. ^[1] Surgical excision with wide margins is the standard treatment. ^[3,7,8] In cases of regional lymph node or distant metastases radiotherapy used alone or associated with neoadjuvant chemotherapy may limit morbidity.

CONCLUSION

Extra-ocular Sebaceous Carcinoma is a rare, aggressive and invasive malignancy known for mimicking other benign diseases both clinically and histologically. An accurate preoperative diagnosis is rarely made leading to inadequate excision and increased chances of recurrence. The importance of preoperative fine needle aspiration cytology in these cases cannot be over-emphasized. Histomorphological variations and unusual sites of occurrence can be a source of diagnostic dilemma for the pathologists as well. A high index of suspicion and demonstration of sebocytic differentiation are the crucial features. EMA immunostain is a useful marker in doubtful cases. An accurate and prompt diagnosis is of utmost importance because of its association with

MTS and considerable propensity for regional and distant metastases.

REFERENCES

1. Natarajan K, Rai R, Pillai SB. Extra ocular sebaceous carcinoma: A rare case report. *Indian Dermatol Online J.* 2011; 2: 91-3.
2. Bhatia SK , Atri S , Anjum A , Sardha M, Ali SA , Zaheer S, Bhatia R, Singla P. Postauricular Sebaceous Carcinoma. *International Journal of Case Reports and Images* 2012; 3(9):29-32.
3. Torres JS, Amorim AC, Hercules FM, Kac BK. Giant extraocular sebaceous carcinoma: case report and a brief review of literature. *Dermatology Online Journal* 18 (11): 7
4. Amita K, Vijayshankar S., Shobha SN. Rippled Pattern Extraocular Sebaceous Carcinoma: A Rare Case Report with Brief Review of Literature. *Journal of Clinical and Diagnostic Research.* 2013; Vol-7(10): 2280-2281
5. Dores GM, Curtis RE, and Fraumeni JF. Incidence of cutaneous sebaceous carcinoma and risk of associated neoplasms: Insight into Muir-Torré syndrome. *Cancer.* 2008; 113(12): 3372–3381.
6. Dasgupta T, Wilson LD and Yu JB. A retrospective review of 1349 cases of sebaceous carcinoma. *Cancer;* 115: 158–165.
7. Gavriilidis P, Barbanis S, Theodorou V, Christoforidou B. Extraocular sebaceous carcinoma mimicking benign sebaceous cyst. *BMJ Case Reports* 2013.
8. Panjwani PK, Tirumalae R, Crasta JA, Manjunath S, Rout P. Extraocular sebaceous Carcinoma: a series of three cases with varied presentation. *Dermatol Pract Conc.* 2012;2(1):7.
9. F Bir, M Akbulut, N ?en, C Kelten, B Topuz, D Ne?e Çalli. Sebaceous Carcinoma Of The Nasal Vestibule: A Case Report. *The Internet Journal of Pathology.* 2006 Volume 5.
10. McCalmont TH, et al. Adnexal neoplasms. In: Bologna JL, et al., eds. *Dermatology.* London: Mosby, 2003: 1735.

How to cite this article: Awasthi N. Extra-ocular sebaceous carcinoma: a case report. *Int J Health Sci Res.* 2015; 5(1):386-389.
