



Case Report

Transitional Cell Carcinoma with Glandular Differentiation - A Rare Variant of Urinary Bladder Carcinoma

Sunil Vitthalrao Jagtap¹, Atul Beniwal¹, Swati S Jagtap², Anil D Huddedar³

¹Department of Pathology, ²Department of Physiology, ³Department of Urology, Krishna Institute of Medical Sciences University, Karad, 415110, India,

Corresponding Author: Sunil Vitthalrao Jagtap

Received: 28/08/2014

Revised: 12/12/2014

Accepted: 18/12/2014

ABSTRACT

Invasive urothelial carcinoma with glandular differentiation is a distinct variant of urinary bladder tumor. It has predominant features of urothelial carcinoma but with distinct glands. Herewith we report a case in a 72 yrs male patient presented with hematuria. Radiological examination showed mass on posterior wall of urinary bladder with thickening. Transurethral resection of bladder tumor was done and sent for histopathological examination which showed high grade transitional cell carcinoma with 30% areas showing glandular component of – papillary, tubular & flat pattern. These types of urinary bladder carcinoma variants are important in clinical practice since they simulate various benign to complex lesion.

Keywords: Bladder Cancer, Urothelial Carcinoma, Hematuria.

INTRODUCTION

Urothelial cancer which represents more than 80% of bladder cancer is mostly found in its pure form. However urothelial cancer is known to show variant histological features. Glandular differentiation is an infrequent variant of urothelial carcinomas. It has an incidence of 7-16 %. ⁽¹⁾ On histopathology tumor with only glandular differentiation should be labeled as adenocarcinoma, rather than urothelial cancer with glandular differentiation. There is very paucity of literature on this variant.

CASE REPORT

A 72 year old patient came to urology department for complaints of 3 months hematuria associated with pain.

Ultrasonography showed well defined heterogeneous mass measuring approximately 69x47 mm in posterior wall of urinary bladder. No evidence of cystic change or calcification. No evidence of extra urinary bladder lesion. Other pelvi-abdominal organ showed normal study. Radiologically it was suspected of malignant urinary bladder tumor. Transurethral resection of bladder tumor (TURBT) was done and sent for histopathological examination.

On light microscopy histopathological examination showed a tumor composed of neoplastic cells arranged in large fronds, papillae, nest, glandular and solid pattern (Figure:1). Individual cells were large pleomorphic, having mildly

pleomorphic hyperchromatic to vesicular nuclei with 1 to 3 prominent nucleoli and moderate amount of cytoplasm (Figure-2,3) Multi-layering, stratification was also noted. Areas of necrosis and frequent mitotic activity were noted. Tumor was infiltrating the stromal tissue and moderate diffuse mononuclear cell infiltration. In areas glandular differentiation was noted (30%) which shows papillae, tubular, irregular and flat pattern. Superficial muscle tissue of bladder wall showed tumor invasion.

Impression of transitional cell carcinoma with glandular differentiation was given. The superficial muscle showed invasion. Deeper muscle was free from tumor

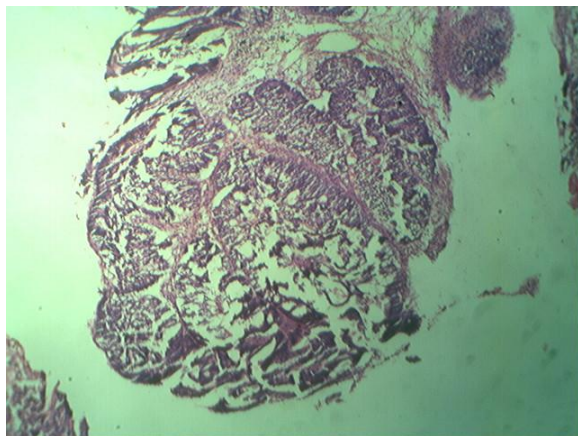


Figure-1: Photomicrograph showing neoplastic cells arranged in papillae, nest, glandular and solid pattern. (H and E,x40).

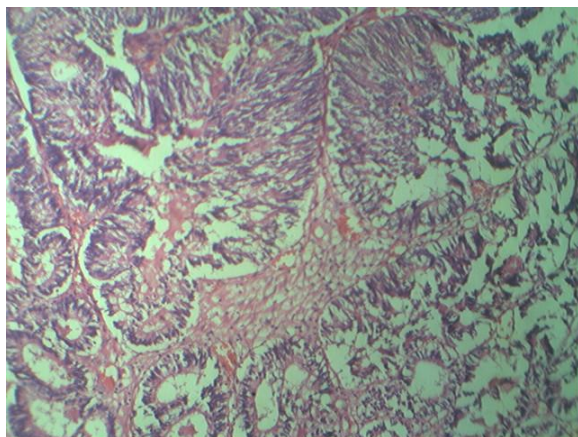


Figure-2: Photomicrograph showing transitional cell carcinoma with glandular differentiation (H and E,x100)

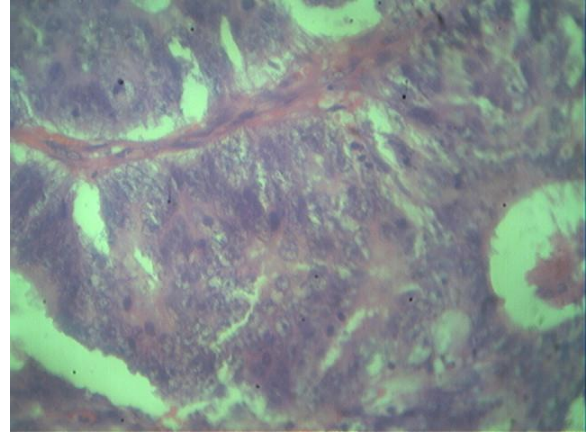


Figure-3: Photomicrograph showing high grade Transitional Cell Carcinoma. (H and E,x400)

DISCUSSION

In recent years with increasing experience of bladder neoplasms, the histomorphological spectrum has been expanded to include several new variants. Urothelial carcinoma is well known for its divergent differentiation, which shows mainly as foci of glandular or squamous differentiation. In the recent World Health Organization (WHO) classification many such variants are classified. (2,3) Urothelial cancer with squamous differentiation is commonly noted and it occurs in up to 21% of cases. (4)

The glandular differentiation is noted in both papillary and non-papillary urothelial neoplasms and in non invasive carcinoma. In our case it was invasive transitional cell carcinoma of bladder having predominant component and in areas showing glandular differentiation. Very few cases of such lesion are described in literature. Glandular differentiation is defined in presence of well formed glands. The glands are variable in appearance. They range from small and tubular and relatively evenly spaced to closely packed, irregular and of moderate to large size. Cytoplasmic mucin can be found in up to 63% of high grade carcinomas and should not be diagnosed as glandular differentiation. (4)

In our case it showed high grade transitional cell carcinoma with 30% areas showing glandular component of papillary, tubular, irregular and flat pattern. So this urinary bladder carcinoma with glandular differentiation on histopathology simulates benign, metastatic to malignant lesions which should be diagnosed properly to treat the patients in clinical practice.

These lesions should be carefully differentiated from other lesions like adenocarcinoma of urinary bladder, cystitic cystic glandularis with intestinal metaplasia, endometriosis in urinary bladder, nephrogenic adenoma, metastatic adenocarcinoma and urothelial carcinoma-microcystic variant.

This entity has a clinical significance as these tumors are associated with higher stage and grade at presentation and poor prognosis. ^(1,5) Also 50% of non invasive tumors with glandular differentiation became invasive but none developed adenocarcinoma. ⁽⁶⁾

In our case it showed invasion into the superficial muscle of urinary bladder. There was no other spread of tumor detected on clinical and radiological examination.

CONCLUSION

In urothelial carcinoma of urinary bladder the histological differentiation is highly variable and their presence should be carefully reported for patients' better management and prognosis.

REFERENCES

1. Billis A, Schenka AA, Ramos CC, et al. squamous and/or glandular differentiation in urothelial carcinoma: prevalence and significance in transurethral resection of bladder. *Int Urol Nephrol*. 2001;33(4):631-3.
2. Eble JN, Sauter G, Epstein JI, et al. Editors Pathology and genetics of the Tumors of the Urinary System and Male Genital Organs. IARC, Lyon France: 2004. WHO classification of tumors; P-359.
3. Amin MB, Murphy WM, Reuter VE, et al, eds. Controversies in Pathology of Transitional Cell Carcinoma of the Urinary Bladder, Chicago: ASCP Press;1996:1.
4. Lopez - Beltran A, Cheng L. Histologic variants of urothelial carcinoma: differential diagnosis and clinical implications. *Hum Pathol* 2006;37:1371-88.
5. Erdermir F, Tunc F, Ozcan F, et al. The effect of squamous and glandular differentiation on recurrence, progression and survival in urothelial carcinoma of bladder. *Int Urol Nephrol* 2007;39(3):803-7.
6. Miller JS, Epstein JI. Non invasive urothelial carcinoma of bladder with glandular differentiation- report of 24 cases. *Am J Surg Pathol* 2009;33 (8):1241-8.

How to cite this article: Jagtap SV, Beniwal A, Jagtap SS et. al. Transitional cell carcinoma with glandular differentiation - a rare variant of urinary bladder carcinoma. *Int J Health Sci Res*. 2015; 5(1):374-376.
