

Case Report

Management of Anaphylaxis in a Case of Renal Hydatid Cyst

Pote Kedareshwar G¹, Gadre Sanjay P², Lanje Shrikant G¹, Bhadane Sushil V³¹Third Year Postgraduate Student, ²Associate Professor, ³Senior Resident,
Dept. of Anaesthesiology, ACPM Medical College, Dhule, Maharashtra, India.

Corresponding Author: Pote Kedareshwar G

*Received: 13/10/2015**Revised: 02/11/2015**Accepted: 05/11/2015*

ABSTRACT

Hydatid disease manifest in humans as hydatid cyst. It is a cyclozoonotic disease endemic in cattle and sheep raising areas in world including India. The tapeworm commonly involved is echinococcus granulosus. Hydatid disease can occur in any part of body most common organs are liver and lungs. Renal involvement is seen in 2% to 3% of patients. Rarely other organs like muscle, cardiac, bone, buccal mucosa can also be involved. The intraoperative risk of anaphylaxis during operation though rare can occur. Necessary management plans must be kept in mind to take appropriate steps in time to avoid catastrophic damage.

Key words: hydatid, kidney, anaphylaxis, treatment.

INTRODUCTION

Hydatid disease is a zoonotic disease transmitted by ingestion of ova of echinococcus granulosus eliminated from infected dog faeces. The disease is having worldwide distribution but it is endemic in some regions such as Asia, Australia, New Zealand and Africa. [1] Though the anaphylaxis during anesthesia is rare event it can vary from mild urticaria to life threatening circulatory shock. [2] The overall incidence of anaphylaxis during anesthesia range between 1 in 5000 to 1 in 20000. [3] With mortality ranging from 3% to 6%. [4] Here we report a case of renal hydatid cyst that developed intraoperative anaphylaxis which was managed successfully with crystalloids, vasopressor, adrenaline and steroids.

CASE REPORT

24 years female with left renal hydatid cyst was posted for excision of cyst. She presented with a history of lump in left hypochondriac region since 2 months gradually increasing in size. Patient also complained of dull aching pain in abdomen since 15 days. Her weight was 54kg & height 168cm. Patient had history of LSCS 3 years back. Computerized tomography scan of the abdomen demonstrated large cystic lesion with multiple internal septations/peripheral cysts within arising from anterior cortex of upper/mid pole of left kidney. All laboratory test (BUN, Cr, Na, K, CBC, FBS, AST, and ALT) and coagulation test gave normal results. Cardiac ejection fraction (EF) was 60% with normal left and right ventricular size and function. No further diagnostic tests for hydatid cyst was done.

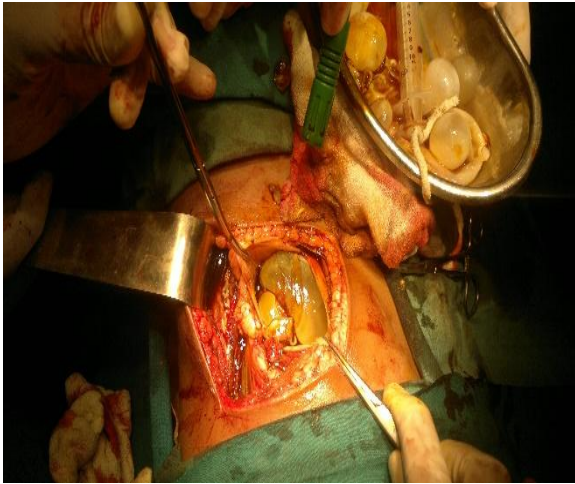


Fig.1: Incision on kidney

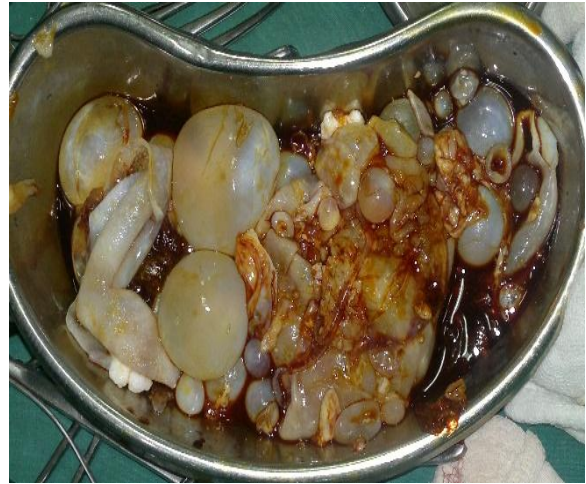

Fig 2: Hydatid cyst

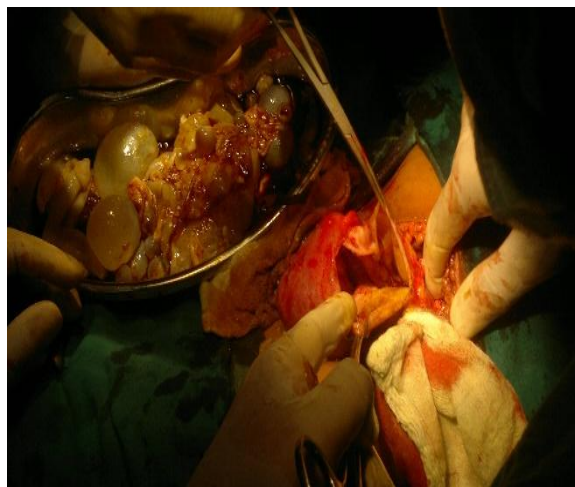


Fig 3: Kidney after complete cyst removal

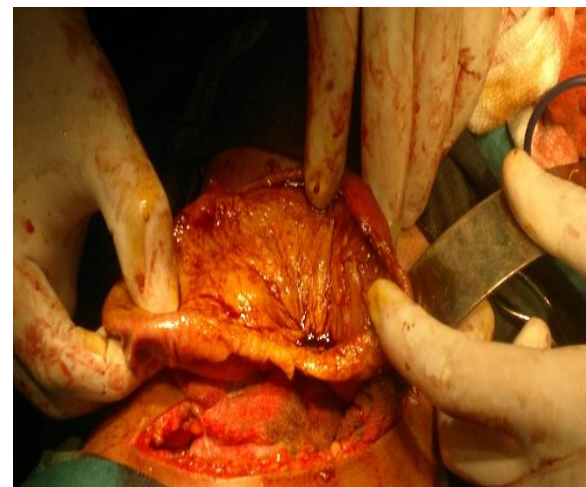


Fig 4: Marsupialization of kidney

In the operating room and after placement of standard monitoring (ECG monitoring, pulse-oximetry, Non-invasive blood pressure monitoring) heart rate 86 beats/minute, blood pressure 132/86 mmHg and O₂ saturation 100% in room air were observed. Two IV lines using 20G intracath was secured one on each hand considering risk of anaphylaxis due to rupture of cyst. Under all aseptic precaution in sitting position in L3-L4 space Tuohy's needle 18 G was inserted and epidural space was reached using loss of resistance technique. Epidural catheter was inserted and test dose 3cc LOX+adrenaline was injected to confirm proper placement of catheter. Epidural catheter fixed by means of tape for post-operative analgesia. After premedication with ondansetron 4mg, glycopyrrolate 0.2

mg, midazolam 1mg and tramadol 100mg iv patient was induced with propofol 100mg and atracurium 25 mg intravenously and airway was secured with cuffed portex Endotracheal tube number 7.5. Air entry was checked bilaterally equal and tube was fixed, connected to ventilator and anesthesia was maintained with sevoflurane 2% MAC with O₂ and N₂O along with atracurium 5mg top up doses three times at interval of 25-30 minutes. The patient was turned to right lateral decubitus position and the surgery was initiated. After cyst got ruptured during dissection sudden severe hypotension occurred(drop in systolic blood pressure to 60 mm Hg), tachycardia 112/min , airway pressure increased to 50mm H₂O with tidal volume 400ml and respiratory rate of 16/min . Surgery was stopped immediately

and volatile anesthetic was discontinued. Fluid resuscitation was given with 500ml Ringer lactate and patient was turned to supine position. Adrenaline 2ml diluted till ten cc i.e. 1:100000 were administered. Inj mephentermine 3mg was given IV bolus. Inj hydrocortisone 200 mg IV, inj ranitidine 50 mg IV was given. Patient was stabilized and surgery was then continued. Suctioning of cystic fluid was done and all hydatid cysts were removed carefully. Intraoperative decision was made by the surgeon to do marsupialization and save the kidney. The vitals parameters of the patient at the end of surgery were pulse 92/min, blood pressure 108/68mm hg. Patient was extubated and was transferred to ICU for 48hrs with stable hemodynamics to observe for any delayed anaphylactic reaction if any. After 48hrs patient was transferred to ward. Post op analgesia was given with injection tramadol through epidural catheter.

DISCUSSION

The *Echinococcus* have a complex life cycle involving two hosts, one is a definitive carnivore host mainly dog and other is intermediate herbivore host. Intermediate hosts like sheep, goats and camel become infected by ingesting the parasite's eggs, which are released in the faeces of definitive hosts. The eggs hatch in the gastrointestinal tract and become activated larvae which penetrate the intestinal wall and enter the bloodstream, eventually locating in internal organs where they develop into hydatid cysts. [5] Humans are accidental hosts. Cyst can develop in different organs of body. Liver is most common followed by lungs. These two organs act as natural filter so they get commonly infected. Other rare locations include cardiac, bone, muscle, tendon etc.

Diagnosis and classification of cyst can be done by using ultrasonography, computerized tomography, magnetic resonance imaging. The disease remains silent most often and the diagnosis is

reached following anaphylactic shock of following accidental rupture. [6-8] blood test like ELISA or Immunoelectrophoresis can confirm the diagnosis of echinococcal disease. [9] The diagnosis can also be supported by positive immunofluorescence antibody technique and indirect haemagglutination test. [10] Current treatment modalities include surgery, PAIR i.e. punctures aspiration injection and reaspiration, percutaneous drainage without reaspiration, absolute ethanol and polidocanol injection into cyst cavity and medical management is given with benzimidazole derivatives. [11] albendazole and mebendazole prevent entry of tubulin into mitochondria, inhibit glucose uptake with suppression of glycogen deposits in the cyst, and disruption of cyst homeostasis via reduced production of adenosine triphosphate. [12] According to recent study combination treatment with albendazole and praziquantel was found to be superior to albendazole monotherapy. [13]

Anaphylaxis can occur from many substances used during anesthesia and surgery like muscle relaxant, latex, antibiotics etc. The symptoms can range from mild urticaria to severe anaphylactic shock. The rate of serious complication can be variable. [14] 10% of anaphylaxis cases present without urticaria and angioedema. [15] The severe reaction can occur due to hypersensitivity reaction type 1 associated with immunoglobulin E response due to high concentration of antigens. There are two types of antigens responsible for the reaction antigen B (AgB) and Protoscoleces antigen (PSC Ag). [16] Anaphylactic or anaphylactoid reactions can also be there secondary to liberation of anaphylatoxins and complement activation. [17] The anaphylaxis can range from rash and urticaria typically over the face, upper limbs, neck and anterior chest wall. Hypotension, tachycardia, bronchospasm can occur. Bronchospasm in our case was

suggested by sudden rise in airway pressure to 50mm H₂O. [18] The other substances causing anaphylaxis like muscle relaxant, antibiotics were eliminated during the time of administration. There are different reactions to allergens due to difference in amount of IgG and IgE production. [19]

Our patient was given crystalloids, epinephrine and corticosteroids. Hemodynamic response was good which led to continuation of surgery. Prevention of anaphylaxis is surgical. It can be carried out by gentle manipulation of cyst and avoiding over distension and spillage during PAIR technique. The key factor of successful management in our case was predetermination of anaphylactic shock, securing two IV access and early timely resuscitation. In most of the guidelines epinephrine is the vasopressor of choice during shock. [20] Steroids do play a role but the effects of them are delayed. We use them in acute phase to prevent the recurrence of symptoms in the late phase of such event. [2] Studies have demonstrated use of H1 and H2 receptor blockers to attenuate hemodynamic response of rupture of hydatid cyst. [21]

CONCLUSION

Anaphylaxis during hydatid cyst surgery is a rare entity, it should always be anticipated. Hemodynamic compromise after ruling out hypovolemia and bleeding should suggest diagnosis of anaphylaxis. Prompt diagnosis and treatment with epinephrine, vasopressors, crystalloids, glucocorticoids, and H1 & H2 blockers can be lifesaving during catastrophic event.

REFERENCES

1. Eckert J. WHO/OIE manual on echinococcosis in humans and animals: a public health problem of global concern. *WHO/OIE*. 2001
2. Bensghir M, Fjouji S, Bouhabba N, Ahtil R, Traore A, Azendour H, Kamili ND. Anaphylactic shock

- during hydatid cyst surgery. *Saudi J Anaesth* 2012;6:161-4
3. Harboe T, Guttormsen AB, Irgens A, Dybendal T, Florvaag E. Anaphylaxis during anesthesia in Norway: A 6-year single center follow-up study. *Anesthesiology* 2005; 102:897-903.
4. Fisher MM, Baldo BA. The incidence and clinical features of anaphylactic reactions during anesthesia in Australia. *Ann Fr Anesth Reanim* 1993; 12:97-104
5. Zhang W, Wen H, Li J, Lin R, McManus DP. Immunology and immunodiagnosis of cystic echinococcosis: an update. *Clin Dev Immunol*. 2012; 2012:101895. doi: 10.1155/2012/101895
6. Boyano T, Moldenhauer F, Mira J, Joral A, Saiz F. Systemic anaphylaxis due to hepatic hydatid disease. *J Investig Allergol Clin Immunol* 1994; 4:158-9.
7. Shameem M, Akhtar J, Bhargava R, Ahmed Z, Khan NA, Baneen U. Ruptured pulmonary hydatid cyst with anaphylactic shock and pneumothorax. *Respir Care* 2011; 56:863-5.
8. Tonnelet R, Jausset F, Tissier S, Laurent V. Spontaneous rupture of a hydatid cyst and anaphylactic shock]. *J Radiol* 2011;92:735-8
9. Rando K, Harguindeguy M, Zunini G. Echinococcal disease with bronchobiliary fistula. *Can J Surg*. 2008 Dec;51(6):E117-8.
10. Özdemir A, Bozdemir ŞE, Akbiyik D, Daar G, Korkut S, Korkmaz L, Baştuğ O. Anaphylaxis due to ruptured pulmonary hydatid cyst in a 13-year-old boy. *Asia Pac Allergy*. 2015 Apr; 5(2):128-31. doi: 10.5415/apallergy.2015.5.2.128.
11. Ormeci N, Idilman R, Akyar S, Palabiyikoğlu M, Coban S, Erdem H, Ekiz F. Hydatid cysts in muscle: a modified percutaneous treatment approach. *Int J Infect Dis*. 2007 May; 11(3):204-8.
12. Senyuz OF, Yesildag E, Celayir S. Albendazole therapy in the treatment of hydatid liver disease. *Surg Today* 2001;31:487-91

13. Dziri C, Haouet K, and Fingerhut A. Treatment of hydatid cyst of the liver: where is the evidence? *World J Surg* 2004; 28:731-6.
14. Jakubowski MS, Barnard DE. Anaphylactic shock during operation for hydatid disease. *Anesthesiology* 1971; 34:197-9.
15. Simons FE, Arduzzo LR, Bilo MB, El-Gamal YM, Ledford DK, Ring J, Sanchez-Borges M, Senna GE, Sheikh A, Thong BY; World Allergy Organization. World Allergy Organization anaphylaxis guidelines: summary. *J Allergy Clin Immunol* 2011;127:587-93.e1-22
16. Haghpanah B, Mosavat B, Ghayour Z, Oreizi F. Diagnostic value of hydatid cyst antigens using western blotting method. *Jundishapur J Microbiol.* 2010; 3(4): 175-85
17. Perricone R, Fontana L, De Coralis C, Ottaviani P. Activation of alternative complement pathway by fluid from hydatidcysts. *N Engl J Med* 1980; 302:808-9.
18. Marashi S, Hosseini VS, Saliminia A, Yaghooti A. Anaphylactic shock during pulmonary hydatid cyst surgery. *Anesth Pain Med.* 2014 Jun 23; 4(3):e16725. doi: 10.5812/aapm.16725. e Collection 2014 Aug.
19. Li Y, Zheng H, Cao X, Liu Z, Chen L. Demographic and clinical characteristics of patients with anaphylactic shock after surgery for cystic echinococcosis. *Am J Trop Med Hyg.* 2011; 85(3):452–5.
20. American Heart Association: Guidelines for Cardiopulmonary Resuscitation and Emergency Cardiovascular Care Anaphylaxis: 10.6. *Circulation* 2005; 112:143-5.
21. Kambam JR, Dymond R, Krestow M, Handte RE. Efficacy of histamine H1 and H2 receptor blockers in the anesthetic management during operation for hydatid cysts of liver and lungs. *South Med J* 1988; 81:1013-5.

How to cite this article: Pote KG, Gadre SP, Lanje SG et al. Management of anaphylaxis in a case of renal hydatid cyst. *Int J Health Sci Res.* 2015; 5(12):428-432.
