

Original Research Article

Assessment of Healing Potential of Colostrum against Incisional Wound Model in Mice

Patil S U¹, Deshpande P.K², Ghongane B.B³, Rane S.R⁴

¹Ex-PG Student, ²Associate Professor of Pharmacology, ³Professor and Head of Pharmacology,

⁴Associate Professor of Pathology,

Department of Pharmacology and Pathology, Byramjee Jijibhoy Government Medical College, Pune 411001

Corresponding Author: Patil S U

Received: 29/10/2015

Revised: 24/11/2015

Accepted: 27/11/2015

ABSTRACT

Treatment of local wounds has been a therapeutic challenge even though many new agents that improve the tissue repair process are being evaluated and used. The present study assesses the wound healing potential of topical application of Colostrum (lactating human mother's milk) as compared to that of Phenytoin sodium cream (1%), Epidermal growth factor cream (30µg/gm), Dimethyl sulfoxide cream (60%) and normal wound healing process in incisional wound model in mice.

Swiss albino mice were divided into 5 groups (n=6). An incision wound was inflicted on their backs using ketamine anesthesia, taking aseptic precautions. Full thickness wounds of 1 cm length were made on the back and sutured. The above preparations were applied daily topically for 13 days. The tensile strength was estimated by tensiometry on day 14. The histopathological assessment and hydroxyproline estimation in the healing tissue was also done.

Colostrum application shows promising results in wound healing. It appears to be as good as topical Phenytoin and better than DMSO AND EGFR.

Keywords: Colostrum, Phenytoin, EGFR, DMSO, incisional wound, mice.

INTRODUCTION

In an attempt to reduce the wound burden, much effort has focused on understanding the pathophysiology of healing and wound care with an emphasis on new therapeutic approaches and the continuing development of technologies for acute and long-term wound management. [1] In addition to a high number of acute wounds, there are also a large number of chronic, hard-to-heal wounds due to diseases and abnormalities that directly or indirectly culminate in damage of the cutaneous coverage, including arterial, venous, diabetic and pressure ulcers. The prevalence of these chronic wounds increases with age.

Furthermore, due to the complications that accompany acute wounds, when their healing does not progress in a timely and orderly manner, they get converted into chronic wounds, which are more difficult to manage. [1]

Despite advances in wound healing treatments, new therapeutic agents that improve the tissue repair process are needed to reduce the healing time, the formation of keloids and retractile scar tissue. So new drugs which enhance healing by altering collagen synthesis are required which will lead to enhanced cosmetic appearance and take shorter time to heal.

A particularly interesting adverse effect of systemic administration of Phenytoin namely gingival hyperplasia; due to its stimulatory effect on collagen metabolism suggests an exciting possibility as a topical agent for wound healing. [2,3,5-7] Also topical application of epidermal growth factor in a timely manner alters wound healing by acting on their receptors in granulation tissue and thus positively affects scar remodeling. [8-11] Many studies with animals demonstrated that Dimethyl Sulfoxide has several pharmacological actions such as membrane penetrant, anti-inflammatory and local analgesic so it was tested for its effects on wound healing as a topical agent. [12-16]

After topical application of colostrum the defensins, macrophages, and more prominently the stem cells in colostrum may provide an impetus for quick wound healing by affecting collagen metabolism. Till recently, we could not find any study testing the effect of topical application of colostrum on wound healing. [7,17-19] Our earlier study has shown that Phenytoin and Colostrum have promising wound healing potential against excisional wound model in mice. [7]

The purpose of the present study was to assess the wound healing potential of Colostrum as compared to that of Phenytoin, Epidermal Growth Factor and Dimethyl Sulfoxide against incisional wound model in mice; since the healing process depends on the type of wound.

MATERIALS & METHODS

This study was conducted after getting an approval from Animal Ethics Committee. Swiss albino mice of either sex and of same age i.e. 10 days old were kept in single cages separately. They were provided with normal diet and water ad libitum. The animals were randomly allocated to 5 different groups. All the experiments were performed between 10 a.m. to 4 p.m.

Drugs:

1) Phenytoin cream- Pure Phenytoin powder was procured from National Chemicals Laboratory, Pune. After dissolving it in lanolin and mixing it with hot cocoa butter, a cream was prepared in the concentration of 1% w/w.

2) EGFR Gel-Recombinant human Epidermal growth factor gel. (30µg/gm) Expiry date-1/2014 Batch no-55AL1, Manufacturing date: 02/2012 Marketed by: Maxter, lupin ltd.

3) Dimethyl sulfoxide cream: After dissolving it in lanolin and mixing it with hot cocoa butter, a 60% w/w cream was prepared.

4) Colostrum was collected from Human Milk Bank. After obtaining consent from the concerned in charge doctor, 1st day milk was collected from the bank in 2ml containers. It was refrigerated at -18°C. On each day of the study 2 ml of milk was applied from one container and the rest of the milk was discarded. The pasteurized milk was obtained from mother's who were tested for absence of infections that could be transmitted through milk (HIV, Syphilis, Malaria, Toxoplasmosis).

Groups: The animals were randomly allocated to 5 different groups, each group containing 6 animals (n=6). 1st, 2nd, 3rd and 4th groups were treated with topical applications of Phenytoin cream, EGFR cream, Dimethyl sulfide cream and colostrum, once daily 13 days. The 5th group was left untreated and served as control.

Incisional Wound Model:

A full thickness wound of 1 cm length on the back were made and sutured.

Tensiometry:

The tensile strength was estimated by tensiometry on day 14. It was estimated by noting the load applied in terms of volume of water required to disrupt the incised re-sutured wounds.

Hydroxyproline (HP) Content

Hydroxyproline (HP) content per 10mg of dried granulation tissue from edges was assessed.

Hydroxyproline was estimated calorimetrically by using UV spectrophotometer at 540 nm as suggested by NEUMAN and LOGAN. [20]

Histopathological Assessment:

Histopathological assessment of wound edges was done on day 10 and 14. All the slides were graded by 2 independent observers after blinding for the treatment to avoid any kind of bias.

The scoring system used has been described in detail earlier. [7, 19] The score for each parameter ranges from 0 to 2 and includes five parameters like Epidermal structure, Dermo-Epidermal junction and micro blisters, Collagen bundles and dermal organization, Epidermal regeneration and Leucocyte infiltration. The maximum total score of 10 indicates maximum healing process while 0 indicates minimum healing or no healing.

Statistical Analysis:

The results are expressed as mean ± 2SD and analysed using SPSS software. The analysis between the groups was done initially using the ‘ANOVA’ test. Any

significant difference was further evaluated using the ‘Unpaired t’ test. All qualitative data was evaluated using the ‘Chi Square’ test. The result was considered statistically significant if p value was less than 0.05. The power of the study to detect false negative or β error was 80%. The histopathological data was analysed by Kruskal Wallis and Mann-Whitney Z test.

RESULTS

TABLE 1: The tensiometry readings (ml of water) in incisional wound model on day 14 as compared to control (n=6)

Group	Water (ml)		Unpaired ‘t’ test	p
	Mean	SD		
Phenytoin	240.00*	17.889	3.024	0.013
EGFR	215.00	18.708	0.183	0.858
DMSO	185.00*	18.708	3.114	0.011
Colostrum	250.00***	10.954	5.500	<0.001
Control	213.33	12.111		

Table 1 shows that the tensile strength was maximum in Colostrum and minimum in DMSO group. It was significantly more with Colostrum (P ≤0.001) and Phenytoin (p =0.013) as compared to control while that of DMSO (p =0.011) was significantly less. It was not significant with EGFR (p =0.858) as compared to control.

TABLE 2: The intra-group comparison of tensiometry readings (ml of water) in incisional model on day 16 (n=6)

Group	Phenytoin		EGFR		DMSO	
	t	p	t	p	t	p
Phenytoin						
EGFR	2.366	0.040*				
DMSO	5.205	<0.001***	2.777	0.020*		
Colostrum	1.472	0.172	4.454	0.001***	8.098	<0.001***

Table 2 shows that the tensile strength of Colostrum treated group was significantly more as compared to EGFR (p =0.001) and DMSO (p =0.001) treated groups. But it is not significantly different as compared

to Phenytoin (p =0.172) treated group. The tensile strength of Phenytoin treated group is significantly more than that of EGFR (p =0.040) and DMSO (p =0.001) treated groups.

TABLE 3: The hydroxyproline content (µg/10 mg of dried tissue) in incisional model on day 14 as compared to control

Comparison with control	Hydroxyproline(µg)		Unpaired t	p
	Mean	SD		
Phenytoin	75.869231***	23.0864775	6.065	<0.001
EGFR	26.708333**	4.8743386	3.293	0.008
DMSO	35.594872***	3.1417429	7.669	<0.001
Colostrum	72.348718***	12.6918533	9.893	<0.001
Control	17.443333	4.8728746		

Table 3 shows that the hydroxyproline content of the wound was maximum with Phenytoin treated group and minimum in

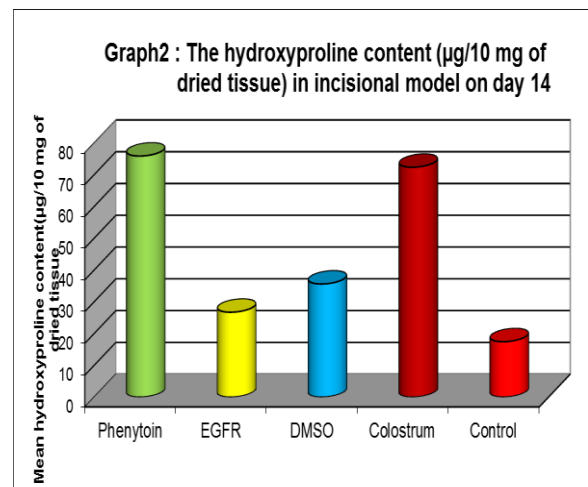
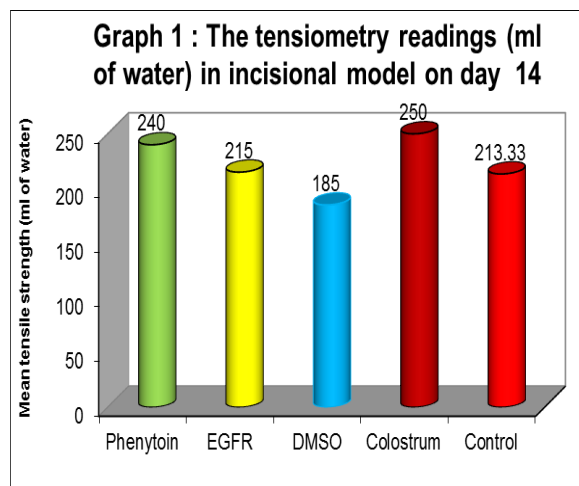
control group. It has increased significantly to a variable degree with all four drugs as compared to control group.

TABLE 4: The intra-group comparison of hydroxyproline content ($\mu\text{g}/10 \text{ mg}$ of dried tissue) in incisional model on day 14

Group	Phenytoin		EGFR		DMSO	
	t	p	t	p	t	p
Phenytoin						
EGFR	5.103	<0.001**				
DMSO	4.234	0.002*	3.754	0.004*		
Colostrum	0.327	0.750	8.223	<0.001**	6.886	<0.001**

Table 4 shows that the hydroxyproline content of the wound in Colostrum and Phenytoin treated groups is significantly more as compared to EGFR and DMSO treated groups. The Colostrum treated group does not significantly differ from Phenytoin treated ($p=0.750$) group.

Graph 1 shows that the tensile strength was maximum in Colostrum and minimum in DMSO group.



Graph 2 shows that the hydroxyproline content of the wound was maximum with Phenytoin treated group and minimum in control group.

TABLE 5: The intra-group comparison of Total histopathological score in incisional model on day 14 (n=6).

Group	Score	Control		EGFR		DMSO		Phenytoin	
		Mann-W Z	P	Mann-W Z	P	Mann-W Z	P	Mann-W Z	P
Control	3.500±0.7071	-							
EGFR	3.167±1.505	1.135	0.256	-					
DMSO	4.500±1.0488	1.702	0.089	1.777	0.076	-			
Phenytoin	5.15±1.169	2.913	0.004*	2.751	0.006*	2.756	0.006*	-	
Colostrum	5.75±0.9354	2.913	0.004*	2.837	0.005*	2.842	0.004*	0.087	0.930

TABLE 5: shows that the Total histopathological score was maximum in Colostrum treated group and minimum in EGFR treated group. The extent of healing process in Colostrum and Phenytoin treated groups is nearly similar and it significantly more as compared to EGFR and DMSO treated groups.

series of co-ordinated events including bleeding-coagulation, initiation of an acute inflammatory response to the initial injury, regeneration, migration and proliferation of connective tissue and parenchymal cells, as well as synthesis of extracellular matrix proteins, remodeling of new parenchyma and connective tissue and collagen deposition. Finally, increasing wound strength takes place in an orderly

DISCUSSION

Normal wound healing is a dynamic and complex process involving a

manner and culminates in repair of severed tissue. [1]

Phenytoin cream and Colostrum application has led to increase in collagen content and tensile strength as seen by tensiometry and hydroxyproline estimation in the present study. There was significant healing as is evident from histopathological score

In another study, assessing effect of phenytoin on cutaneous healing on excision of melanocytic naevi on face and back it was found that Phenytoin 0.5% cream accelerated skin wound healing with good cutaneous tolerability in human patients and cosmetic outcome. [4]

Topical application of phenytoin significantly accelerated wound healing and improved the quality and vascularity of granulation tissue, possibly by increasing fibroblast proliferation, maturation of collagen content on one hand and decreasing collagenase activity on the other hand. [5]

In another study it was found that the effect exerted by phenytoin in fracture healing is probably in the early inflammatory stage during mesenchymal differentiation. Differences in phase of cell cycle, cell type and cell density between the cell pools of the central callus and peripheral callus could influence the difference in response. There appears to be a positive influence of phenytoin in fracture healing in the whole periosteal callus, especially in the already hyper-vascular zones like the sub-periosteal location. [6]

The author in their previous study reported that topical application of phenytoin has led to earlier wound healing with improved cosmetic appearance and also increased collagen formation due to effect of phenytoin on collagen metabolism. [7]

EGFR has led to increase in collagen content but no others parameters appear to have been significantly affected. In healthy human epidermis, EGFR can be

localized throughout the entire epidermis, although its membranous presence is most prominent in the basal layer. There are also ligands for other receptors, such as b-AR agonists (catecholamines), angiotensin II, and antimicrobial hCAP- which can trans-activate EGFR. Ultimately this signaling pathway leads to the activation of a number of converging pathways promoting cell migration and proliferation. [9] In vitro studies, show that activation of the EGFR plays an important role in re-epithelialization by increasing keratinocyte proliferation and cell migration in acute wounds. [10] One mechanism through which EGF functions is by increasing the expression of keratins K6 and K16, involved in the proliferative signaling pathway. One in vitro study demonstrated that in the epidermis of non-healing edges of chronic wounds EGFR was found in the cytoplasm of keratinocytes instead of the membrane. This suggests that the receptor's down-regulation and mis-localization may participate in inhibition of epithelialization in patients with chronic wounds. Other in vitro studies demonstrate substantial degradation of exogenous EGF and the EGFR reversible with the addition of metalloproteinase (MMP) inhibitors in chronic ulcers. [9,10]

Also, DMSO did not lead to any significant changes in parameters tested and in fact it has led to decrease in tensile strength. So it can be concluded that topical DMSO did not seem to have any significant role in wound healing as compared to the rest,

Colostrum which contains lactoferrin, PDGF and also stem cells was proposed to help in wound healing and the same was tested in present study. It was observed that Colostrum led to increase in tensile strength, collagen content of wound, acceleration of epithelialization as well as improvement in Histopathological scoring. On Day 14 there was predominance of fibroblasts and new blood vessels and a more systematic

arrangement of collagen fibers. In conclusion, Colostrum due to presence of lactoferrin or stem cells may be effectively used in wounds of different etiologies.

The authors in their previous study have got similar observations in excisional model. In this study colostrum has led to increase in collagen content, orderly arrangement of collagen fibres and enhanced cosmetic appearance. The author also reported early wound healing by histopathological assessment and planimetry. [7]

In another study combination of milk and honey when topically applied showed anti-staphylococcal activity as compared to any of the 2 components used singly as it is shown that honey leads to proteolysis of some of the biogenic peptides of milk that have antimicrobial property. [15]

Colostrum growth factors also play a role by keeping the intestinal mucosa sealed and impermeable to toxins. This is evidenced by colostrum's ability to control chronic diarrhea caused by gut inflammation related to dysbiosis. Healing leaky gut syndrome reduces toxic load and helps in the reversal of many allergic and autoimmune conditions. [16] In another study, milk fat globule factor 8 /lactadherin plays an important role in maintaining intestinal homeostasis and promotion of mucosal healing and suggest that recombinant MFG-8 may be beneficial for the treatment of bowel injuries. [17]

Lactoferrin (Lf), a mammalian iron scavenging defense protein, constitutively is present in exocrine secretions that consistently are exposed to microbial flora: milk, tears, tubo-tympanum and nasal exudate, saliva, bronchial mucus, gastrointestinal fluids, cervico-vaginal mucus, and seminal fluid. Additionally, Lf is promptly delivered by circulating neutrophils to sites of microbial invasion. At these sites, the protein effectively

scavenges iron at pH values as low as 3.5. [18]

In conclusion, as Colostrum and Phenytoin cream improved all the parameters of wound healing in incisional wound model. They appear to be cheap and safe alternatives to costly therapies like growth factors.

Conflicts of Interest: The author expresses no conflicts of interest.

REFERENCES

1. Natarajan S, Williamson D, Stiltz AJ, et al: Advances in wound care and healing technology. *Am J ClinDermatol*2000; 1: 269 –275.
2. Shafer WG, Beatty RE, Davis WB. Effect of Dilantin sodium on tensile strength of healing wounds. *ProcSoc Exp Biol Med* 1958; 98:348-50
3. Pendse AK, Sharma A, Sodani A, Hada S. Topical Phenytoin in wound healing. *Int J Dermatol* 1993; 32:214-7.
4. Masgrau-Peya E, Lacour M, Salomon D. Topical phenytoin accelerates healing in EpidermolysisBullosa Simplex. *Dermatology* 1995; 190: 254.
5. Mcanally Le, Thompson D. Use of phenytoin for Wound Healing. *Hospital Pharmacy* 1992; 27:649-50.
6. Manoj Mathew, Mandeep S. Dhillon The effect of local administration of Phenytoin on fracture healing: An Experimental Study *ActaOrthop. Belg.*, 2006, 72, 467-473
7. Patil SU, Deshpande PK, Ghongane BB: Comparative Wound Healing Potential of Topical Application of Phenytoin, Epidermal Growth Factor, Dimethyl Sulfoxideand Colostrum Against Excisional Wound Model in Mice. *Research Journal of Pharmaceutical, Biological and Chemical Sciences* October 2015 6(5):661-66
8. Oda K, Matsuoka Y, Funahashi A, Kitano H. A Comprehensive pathway map of Epidermal Growth Factor receptor signaling. *MolSyst Biol* 2005; 1–17

9. Yahata Y, Shirakata Y, Tokumaru S, Yang L, Dai X, Tohyamam, Tsuda T, Sayama K, Iwai M, Horiuchi M, Hashimoto K. A novel function of Angiotensin II in skin wound healing-Induction of fibroblast and keratinocyte migration by Angiotensin II via heparin-binding epidermal growth factor(Egf)-like growth factor mediated Egf receptor transactivation. *J Biol Chem* 2006; 281: 13209–16.
10. Nanney Lb. Epidermal and dermal effects of Epidermal Growth Factor during wound repair. *J Invest Dermatol* 1990;94: 624–9
11. Franklin Jd, Lynch Jb. Effects of topical applications of Epidermal Growth Factor on wound healing. Experimental Study On Rabbit Ears. *Plastic And Reconstructive Surgery* 1979; 64(6):766-770.
12. Carpenter J. R., Angel M. F., Morgan R. F. Dimethyl sulfoxide increases the survival of primarily ischemic skin flaps. *Otolaryngol Head Neck Surg*, 1994, 110:228-31.
13. Luby L. R., Pommier R. F., Shauna T. W., Woltering E. A.,Kweren A. S., Fletcher W. S. Improved outcome of surgical flaps treated with topical Dimethyl sulfoxide. *Ann Surg*, 1996, 224:583-90.
14. O. Celen, E. Yildirim, U. Berberog̃lu. Prevention of Wound Edge Necrosis by Local Application of Dimethyl -sulfoxide; *Actachirbelg*, 2005, 105: 287-290.
15. Jabri; S A Al Hosni; B Nzeako; H Nsanze, Antistaphylococcal activity of Omani honey in combination with bovine milk *British Journal of Biomedical Science*; 2005; 62, 2; Pro-Quest Pharma Collectionpg. 92
16. Marchbank T, Playford RJ. Bovine colostrum or TGFb (a major bioactive constituent of colostrum) were prophylactic against indomethacin induced injury. *Gut* 1998; 42(suppl): A68 (abstr).
17. Heng-Fu Bu; Xiu-Li Zuo; Xiao Wang; Michael A Ensslin; VjolaKoti; Wei HsuehMilk fat globule-EGF factor 8/lactadherin plays a crucial role in maintenance...;*Journal of Clinical Investigation*; Dec 2007; 117,
18. Eugene D. Weinberg Antibiotic Properties and Applications of Lactoferrin, *Current Pharmaceutical Design*, 2007, 13:801-81
19. HideyoshiToyokawa, Yoichi Matsui et al, Promotive Effects of Far-Infrared Ray on Full-Thickness Skin Wound Healing in Rats; *Exp Biol Med* June 2003, 228(6):724-729
20. Robert.e. Neuman, Milan. A. Logan, The determination of Hydroxyproline, *J BIOL CHEM* 1950;299-306.

How to cite this article: Patil SU, Deshpande PK, Ghongane BB et al. Assessment of healing potential of colostrum against incisional wound model in mice. *Int J Health Sci Res.* 2015; 5(12):197-203.
