

Case Report

Heterotaxy Asplenia Syndrome

Budensab A H¹, Ravindra Kumar Charan², Fouad Ali Al Ghazal³¹Consultant Neonatologist, MCH Hospital Al Hassa KSA.²Consultant Pediatric Cardiologist, MCH Hospital Al Hassa KSA.³Consultant Neonatologist and Head of Neonatology, MCH Hospital Al Hassa KSA.

Corresponding Author: Budensab A H

Received: 26/08/2015

Revised: 27/09/2015

Accepted: 01/10/2015

ABSTRACT

Introduction: Heterotaxy asplenia syndrome (right isomerism or bilateral right-sidedness), which is associated with a centrally located liver, absent spleen, and two morphologic right lungs usually associated with dextrocardia and cyanotic congenital heart disease.

Case Presentation: We report the case of dextrocardia with heterotaxy syndrome who presented with respiratory distress soon after birth. A chest X-ray showed dextrocardia, cardiomegaly with pulmonary congestion. The findings of an electrocardiogram and echocardiography confirmed dextrocardia and an abdominal Ultrasound showed liver central more on right side with mild hepatomegaly, no spleen visualized, stomach on left side, pancreas both kidneys urinary bladder normal with free minimal fluid.

Conclusions: Heterotaxy asplenia syndrome a rare group of congenital malformations that must be fully evaluated. There is need for a complete and elaborate diagnostic work up of suspected cases by using various imaging modalities so that they are not missed. Doctors should encourage routine medical examination for their patients which could help identify this anomaly, thereby preventing wrong diagnosis and possibly death due to delay in management.

Keywords: Dextrocardia; heterotaxy; asplenia syndrome.

INTRODUCTION

Heterotaxy asplenia syndrome (right isomerism or bilateral right-sidedness), which is associated with a centrally located liver, absent spleen, and two morphologic right lungs usually associated with dextrocardia and cyanotic congenital heart disease. ⁽¹⁾

CASE PRESENTATION

Full Term male Baby delivered to Gravida 4 Para 3 mother with no history of any maternal illness presented with respiratory distress. Baby cried well after birth with good apgar score but developed respiratory distress at 22 hours of age with

tachypnea and grunting respiration baby was started on oxygen 2Liter/min by nasal prong. On examination baby had birth weight of 3.25 kg with stable vital signs SPO2 96%. Baby had respiratory distress, tachypnea and chest retractions, air entry equal, no crepitations with no dysmorphic features. CVS: All peripheral pulses felt, no radio femoral delay, heart sounds better heard on right side, heart sounds normal with III/VI systolic murmur in the right sternal border Abdomen: Soft and lax, liver 3 cm below right costal margin, bowel sounds normal, normal male genitalia. CNS: normal.

Investigations: CBC biochemistry within normal limits.

Chest X- ray: dextrocardia, cardiomegaly with pulmonary congestion. ECG showed inverted P waves in lead 1.

Abdominal Ultrasound showed liver central more on right side with mild hepatomegaly, no focal lesions seen, Gall bladder normal location and morphology, no spleen visualized, stomach on left side, pancreas both kidneys urinary bladder normal with minimal fluid in abdomen.

Echocardiography revealed situs ambiguous, dextrocardia, IVC connected to large common atrium, Right atrial isomerism, only one coronary sinus seen. Pulmonary veins connected to large common ambiguous atrium and 2 small muscular VSD, large perimembranous VSD, single common AV valve with pulmonary hypertension, right ventricle larger than left and both vessels arising from right ventricle with transposition of great vessels. No aortic stenosis or pulmonary stenosis, pulmonary valve larger than aortic valve, ascending aorta and proximal aortic arch normal, distal arch and preductal descending aorta narrowed. PDA moderate size with left to right shunt. Normal coronaries and postductal descending aorta.

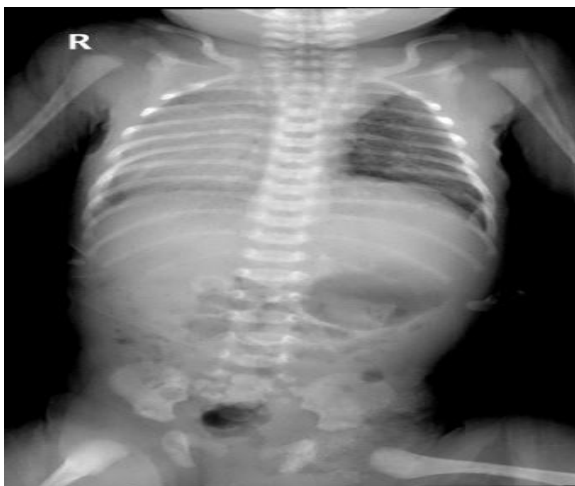

Figure 1 chest x ray

Progress - Baby developed increasing respiratory distress, and CO₂ retention so ventilated on day 4 of life and

referred to higher centre for surgical management.

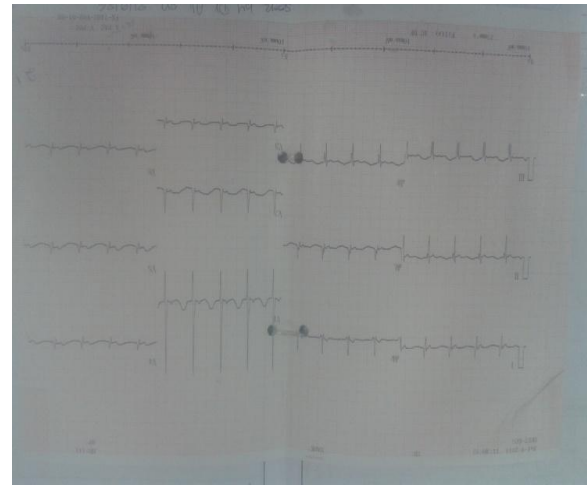


Figure 2 ECG

DISCUSSION

Heterotaxy syndromes are rare occurring in 1/10,000 live births (Lin et al, 2002) with male female ratio 2:1. ^(1,2) If the viscerotaxial situs cannot be readily determined, a condition known as situs ambiguous or heterotaxia syndrome. ⁽²⁾ The two major variations are ⁽¹⁾ asplenia syndrome (right isomerism or bilateral right-sidedness), which is associated with a centrally located liver, absent spleen, and two morphologic right lungs, and ⁽²⁾ polysplenia syndrome (left isomerism or bilateral left-sidedness), which is associated with multiple small spleens, absence of the intrahepatic portion of the inferior vena cava, and bilateral left lung morphology (i.e., in both lungs). The heterotaxia syndromes are usually associated with conduction defects and severe congenital heart lesions: ASD, VSD, atrioventricular septal defect, single functional ventricle, transposition of great arteries, pulmonary stenosis or atresia, and anomalous systemic venous or pulmonary venous return. ^(1,2)

In our patient situs ambiguous was associated with asplenia and dextrocardia. Cardiac anomalies identified on echocardiography were dextrocardia, IVC connected to large common atrium, Right atrial isomerism, only one coronary sinus

seen. Pulmonary veins connected to large common ambiguous atrium and 2 small muscular VSD, large perimembranous VSD, single common AV valve with pulmonary hypertension, right ventricle larger than left and both vessels arising from RV with transposition, pulmonary valve larger than aortic valve, ascending aorta and proximal aortic arch normal, narrowing of distal arch and preductal descending aorta. PDA moderate size with left to right shunt. Normal coronaries and post ductal descending aorta. In the vascular anomaly IVC and aorta were both on left side of vertebral column. However, dextrocardia with situs inversus is associated with a lower incidence of congenital heart disease (0 to 10%). Presentation of cause varies depending on associated malformation. (1-4) Situs inversus may be associated with other congenital anomalies such as duodenal atresia, asplenism, multiple spleens, ectopic kidney, horseshoe kidney and various pulmonary and vascular abnormalities. (5,6) Situs inversus totalis that is associated with primary ciliary dyskinesia is known as Kartagener syndrome. (7) Patients with primary ciliary dyskinesia have repeated sinus and pulmonary infections. (8) The arrangements of the position of the abdominal viscera in dextrocardia may be normal (situs solitus), reversed (situs inversus), and indeterminate (situs ambiguous or isomerism) in 32 to 35%, 35 to 39% and 26 to 28% of cases respectively. (8)

Dextrocardia with a normal abdominal situs has a high incidence of associated congenital cardiac anomalies including among others, transposition of the great vessels and ASDs (9) and VSDs (9) in 90 to 95% of cases. Diagnosis of dextrocardia is usually confirmed by several modalities which include chest radiography, ECG, echocardiography, computed tomography, magnetic resonance imaging and abdominal ultrasonography. Echocardiography is one

of the modalities for making the diagnosis. Of interest, this patient had situs ambiguous with complex cardiac anomalies. This case is reported because of situs ambiguous, dextrocardia and asplenia with early symptomatic presentation due to complex pattern of cardiac malformation.

CONCLUSIONS

Heterotaxy asplenia syndrome a rare group of congenital malformations that must be fully evaluated when noticed because in rare instances it may result in fatal outcome. There is need for a complete and elaborate diagnostic work up of suspected cases by various imaging modalities so that they are not missed. Surgeons, radiologists and radiographers should look out for this anomaly during preoperative and surgical management of their patients. Doctors should encourage routine medical examination for their patients which could help identify this anomaly, thereby preventing wrong diagnosis and possibly death due to delay in management.

Competing Interests: The authors declare that they have no competing interests.

No funding was done.

REFERENCES

1. Richard E. Behrman: Nelson text book of paediatrics 19th edition chapter 424.11 abnormal positions of heart and heterotaxy syndromes
2. Taeusch H William, Ballard Robert A, Gleason Christine A Avery's diseases of the newborn 8th edition chapter 57.858 heterotaxy syndrome
3. Holzmann D, Ott PM, Felix H: Diagnostic approach to primary ciliary dyskinesia: a review. Eur J Pediatr 2000, 159(1-2):95-98
4. Madan Kumar K, Irineu, Babu C, Chander S, Kumar A, Balchander J, Nachipaan M: Complete A-V canal defect with dextrocardia with CCTGA – A case Report. JTCVS 2003, 19:55.
5. Kulkarni PR, Inamdar VV: Situs inversus with dextrocardia associated with ventricular septal defect – a case

- report, Abstract. J Anat Soc India 2005., 54(1)
6. Piryani RM, Shukla A, Prasad DN, Kohli SC, Shrestha G, Singh D: Situs inversus with dextrocardia with multiple cardiac lesions in adult. Kathmandu Univ Med J 2007, 5(2):247-249.
 7. Ortega HA, Vega Nde A, Santos BQ, Maia GT: Primary ciliary dyskinesia: considerations regarding six cases of Kartagener syndrome. J Bras Pneumol 2007, 33(5):602-608.
 8. Isezuo SA, Ma'aji SM, Isah U, Makusidi A: Dextrocardia with situs viscerum inversus totalis in a 65 year old man: a case report. Niger J Clin Pract 2010, 13(1):98-100.
 9. Iino K, Watanabe G, Ishikawa N, Tomita S: Total endoscopic robotic atrial septal defect repair in a patient with dextrocardia and situs inversus totalis. Interact Cardio Vasc Thorac Surg 2012, 14(4):476-477.

Authors' Contributions: BAH made substantial contributions to observations and acquisition of data BAH and RKC was involved in revising the manuscript for important intellectual content. FAG gave final approval of the version to be published. All authors read and approved the final manuscript.

Abbreviations: CVS: cardiovascular system, CNS: central nervous system, CBC: complete blood count, ECG: electrocardiography ASD: Atrial septal defect; VSD: ventricular septal defect; PDA: patent ductus arteriosus IVC: Inferior vena cava, CO2: carbon dioxide SpO2: haemoglobin oxygen saturation.

How to cite this article: Budensab AH, Charan RK, Al Ghazal FA. Heterotaxy asplenia syndrome. Int J Health Sci Res. 2015; 5(11):396-399.
