

Case Report

Cervical Rib - Two Case Reports with Review of Literature

R. Chandra Sekhar¹, K. Lakshmi Kumar²¹Post Graduate in Orthopaedics, KIMS, Amalapuram.²Assistant Professor, Dept of Anatomy, Andhra Medical College, Visakhapatnam.

Corresponding Author: K. Lakshmi Kumar

*Received: 31/07/2015**Revised: 02/09/2015**Accepted: 11/09/2015*

ABSTRACT

Cervical rib is a supernumerary rib arising from transverse process of 7th cervical vertebra. Cervical rib is normally asymptomatic, unless there is a formation of fibrous band compresses brachial plexus and vessels around thoracic outlet. The presence of cervical rib is clinically important than being Anatomical curiosity alone. In this we are discussing two different cases of cervical rib with mild symptoms.

Keywords: cervical rib, supernumerary rib, brachial plexuses compression.

INTRODUCTION

The cervical rib is supernumerary rib developed from 7th cervical vertebra and this is sometimes known as Neck Ribs. Cervical ribs occur commonly, but they are asymptomatic. If symptoms occur in a patient with bilateral cervical ribs, they are usually present on the side of the smaller rib. Cervical ribs are rarely symptomatic in early childhood, in older syndrome. ⁽¹⁾ A fibrous band as a variant of cervical rib often cause of symptoms than is an actual rib which is normal and symptomless. It may take the form of a fibrous band stretching down to the first rib. It lies either behind or below the brachial plexus and vessels and exerts pressure on them by movements of the upper limb. Symptoms are usually delayed until adolescence because pressure on the brachial plexus by the rib is not felt until a lowering of the shoulder girdle, which occurs about that age. It is seen especially in

females who have an adolescent increase in weight of the shoulders and breasts. Symptoms are commoner in people with long necks and sloping shoulders than in those of square build. The rib is not as a rule palpable, and the larger it is the less commonly does it produce nervous symptoms. Vertebral column in the embryo grows faster than the spinal cord, nerves and plexus issuing from the latter assumes an oblique course to reach the extremities. They thus interfere with growth of ribs. Consequently in newborn in the cervical region it will be represented by the transverse processes of the vertebral bodies. The Distal parts of costal processes in seventh cervical vertebra which do not develop normally occasionally develop into cervical rib. The Cervical Rib may extend beyond the transverse process or even touch the first rib. It may reach the cartilage of first rib as either fibrous band or true

cartilage. If the ribs attain sufficient length the subclavian artery or brachial plexus may be compressed between the angle formed by the rib and Scalenus anterior muscle giving rise to nervous or circulatory disturbances.

(2) If the upper extremity descends too fast and too far, it shears off the upper thoracic ribs as well, if it descends too slowly, the seventh cervical rib is permitted to develop.

(3) Vascular symptoms result from irritation of sympathetic fibres in the lowest trunk of Brachial plexus. The costal element of the seventh cervical vertebra may be a mere epiphysis on its transverse process but more often has a head, neck and tubercle with or without a shaft extends into the posterior triangle of neck where it may end freely or join the first rib or costal cartilage or even the sternum which may be partly fibrous or osseous. Mutations in Hox genes have been shown to cause the development of cervical ribs from the costal or ventral processes of the primitive vertebral arches. (4,5) These can be associated with stillbirths and childhood malignancies. (6,7) Indian population showed an overall incidence of 0.6% as compared to the London population showing an overall incidence of 0.74%. (8) At first it was

thought that the circulatory changes were caused by stretching or kinking of the subclavian artery over the cervical rib or by thrombosis within the artery, but Todd advanced a theory of nervous origin of vascular changes in the hands. Surgical treatment is proven to be successful with long term follow up data showing 65-70% success rate. There is much room for improvement in the surgical technique and diagnostic stratification. (9,10)

CASE REPORT

A 36 year old female patient attended to orthopaedic o.p with features of disabling pain and paresthesia of right upper limb. After examination she found symptoms of weakness of muscle in hand and muscles around thumb which is indicating Brachial plexus compression. On examination there is no loss of radial pulse. Second case is a 21 year female student complaining of pain at right side of neck for 2 months associated with swelling of neck at right side. She also complained of tingling sensation at the inner aspect of right upper limb. After radiological examination both were diagnosed with cervical rib.

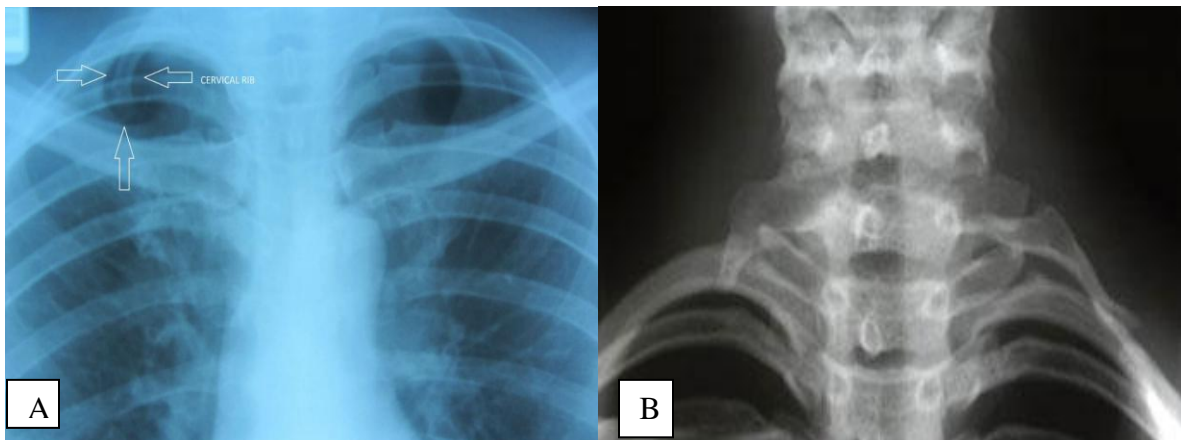


Fig A & B: X-ray showing cervical rib of both cases.

DISCUSSION

Cervical rib may be a fully formed bony rib or just a thin strand of tissue fibers,

which will not always show up on any X-ray or MRI scans. If the extra rib is only partially formed, it may either end in a

swelling that shows as a lump in the neck or it may tail off into a fibrous band of tissue that connects to the first proper rib. There is evidence to prove that long continued pressure of the cervical rib on the brachial plexus brings about a chronic aseptic inflammatory reaction which, if continued long enough, may bring about a permanent fibrosis. ⁽⁸⁾ According to Schein et al ⁽¹⁰⁾ a cervical rib is present in 0.5-0.7% of the population and appears more commonly in females than males, in a ratio of 2:1. The deformity is usually bilateral (twenty-four out of thirty-one cases). It is estimated that only 10 per cent of cervical ribs cause symptoms. ⁽¹¹⁾ Halstead (as cited by Connell et al ⁽¹²⁾ was the first to report that when an artery is subjected to incomplete pressure an aneurysm develops distal to the point of pressure Isolated fracture of a cervical rib producing symptoms of thoracic outlet compression has been reported ⁽¹³⁾ Cervical rib fracture due to neck trauma is an extremely rare cause of Thoracic outlet syndrome. ⁽¹⁴⁾ The first unsuccessful resection of Cervical rib in a patient with thoracic outlet syndrome was performed by Coote in 1861 ⁽¹⁵⁾ In 1905 Murphy first made a successful resection of Cervical rib in the patient with thoracic outlet syndrome and he removed the first rib using supraclavicular approach for the first time. In 1927, Adson Coffey emphasized the role of ligaments, soft tissues and scalenus muscle in producing thoracic outlet syndrome and made the first successful resection of the scalenus anticus muscle ⁽¹⁶⁾ The symptoms associated with a cervical rib must be distinguished from Ulnar neuritis, in which there is no shoulder pain, no thenar flattening, and no relief on abducting the arm. Herniated cervical disc produces radiculitis. This usually appears at a later age. X-ray may show a narrowed disc space. The pain is intense in the shoulder region.

CONCLUSION

Anatomically the lowest trunk of plexus was usually in closer apposition to the first thoracic rib or the cervical rib than the subclavian artery. Changes in the arteries were trophic in nature and due to pressure causing paralysis of the sympathetic fibers which enter the arm in the lowest trunk of the brachial plexus. In the present two case reports the presence of cervical rib leads to pressure over brachial plexus. Anatomic variations like cervical rib are worthy to consider in cases of vascular disorders of the upper extremities.

REFERENCES

1. Durham JR, Yao Js, Pearce WH, Nuber GM, Mc Carthy WJ, 3rd Arterial injuries in the thoracic outlet syndrome. *J Vasc Surg* 1995;21; 57-69.
2. Adson, A.W, Aand Coffey, J.R. Cervical Rib. *Ann Surg* 1927 (109); 85; 839-877.
3. Jones, F.Wood. Discussion on Cervical Rib. *Lancet* 1913; 609-611.
4. Brewin J, Hill M, Ellis H. The prevalence of cervical ribs in a London population. *Clin Anat* 2009; 22:331-36.
5. Galis F. Why do almost all mammals have seven cervical vertebrae? Developmental constraints, Hox genes, and cancer. *J Exp Zool* 1999; 285:19-26.
6. Bots J, Wijnaendts LC, Delen S, et al. Analysis of cervical ribs in a series of human fetuses. *J Anat* 2011; 219:403-09.
7. Merks JH, Smets AM, Van Rijn RR, et al. Prevalence of rib anomalies in normal Caucasian children and childhood cancer patients. *Eur J Med Genet* 2005; 48:113-29.
8. Antima Gupta, DP Gupta, Cervical Rib: Its prevalence in Indian population around Lucknow, *Journal of Anatomical Society of India*, vol 61(2),2012,189.
9. Le Forestier N, Mouton p, Maisonobet Fournier E , Mouloguet A , Willer JC

- etal. True neurological thoracic outlet syndrome. *Rey neurol (paris)* 2000;156:34-40
10. Seror p Medical antibrachial cutaneous nerveconduction study, a new tool to demonstrative mild lower brachial plexus lesims. A report of 116 cases, *clin neuro physiol.* 2004;115:2316-22
 11. C. J. Schein, H. Haimovici, and H. Young. Arterial thrombosis associated with cervical ribs: surgical considerations. *Surgery* 1956;40(2):428-443
 12. M.S. Handerson. CERVICAL RIB Report of Thirty-one Cases. *J Bone Joint Surg Am* 1914 Jan 01; s2- 11(3); 408-430.
 13. J. L. Connell, J. C. Doyle, and J. F. Gurry. The vascular complications of cervical rib. *Australian and New Zealand Journal of Surgery* 1980; 50(2): 125-130.
 14. Rayees Ahmad Dar, Sabiya Hamid Wani, and Majid Mushtaque. Isolated Cervical Rib Fracture: A Rare Etiology of Thoracic Outlet Syndrome. *Case Reports in Surgery*, vol. 2011, Article ID 163792, 2 pages, 2011
 15. S. R. Sabapathy, H. Venkatramani, and P. Bhardwaj. Pseudarthrosis of cervical rib: an unusual cause of thoracic outlet syndrome. *Journal of Hand Surgery* 2010; 35(12):2018-2021.
 16. Wilbourn AS the thoracic outlet syndrome is over diagnosed. *Arch Neuro* 1990; 47; 328-30.

How to cite this article: Sekhar RC, Kumar KL. Cervical rib- two case reports with review of literature. *Int J Health Sci Res.* 2015; 5(10):396-399.
