

*Case Report***Eccrine Hidrocystoma over a Finger: A Rare Site**Usha Shinde¹, Suresh V Mahajan², Satyaprakash C. Mahajan³¹Associate Prof., Dept of Pathology, Bharati Vidyapeeth Deemed University Medical College and Hospital sangali.²Prof. & HOD, Dept of Pathology, Dr. Vasanttrao Pawar Medical College, Hospital and Research centre, Nashik.³Consultant Dermatologist, Nashik.

Corresponding Author: Suresh V Mahajan

*Received: 17/06/2015**Revised: 16/07/2015**Accepted: 04/09/2015***ABSTRACT**

We report a case of 65 year old male, presented with chief complaint of gradually increasing swelling over right middle finger since one and half years. On examination, the solitary lesion was translucent and non-tender. Diagnosis of eccrine hidrocystoma (EH) was made on histopathology examination. Though the solitary EH is common in elderly male, its location over the finger is very rare. We would like to highlight the rare occurrence of EH over the finger in a male patient.

Key words: Eccrine hidrocystoma, finger, Papule.

INTRODUCTION

Eccrine Hidrocystoma is a rare benign cystic lesion of the skin. It usually presents as asymptomatic facial papules in middle aged females. It can occur as single or multiple lesions. It usually presents as a solitary lesion with predilection for periorbital and malar region of face. It shows chronic course and seasonal variation.

Solitary eccrine hidrocystoma equally affects both male and female in adult age. Multiple eccrine hidrocystomas are more commonly seen in middle aged females. We report a case of solitary eccrine hidrocystoma in an elderly male over the finger, which is one of the uncommon sites of its presentation.

CASE REPORT

A 65 years old male presented with swelling on right middle finger since one and half years, which was non tender and gradually increasing in size. On examination, the swelling was non tender, solitary, cystic, translucent and papular. It measured 1.5cm x 1 cm. [Figure 1]. He had no history of trauma or any chronic illness. Excision was performed and sample sent for histopathology examination. Histopathology revealed cyst situated in the mid-dermis. The lumen of the cyst contains eosinophilic material. It is located in close proximity of eccrine glands. The cyst is lined by two layers of cuboidal epithelium with eosinophilic cytoplasm [Figure 2]. Lumen contains small amount of pale eosinophilic secretions, causing flattening of epithelium [Figure 3]. There was no evidence of decapitation secretion.

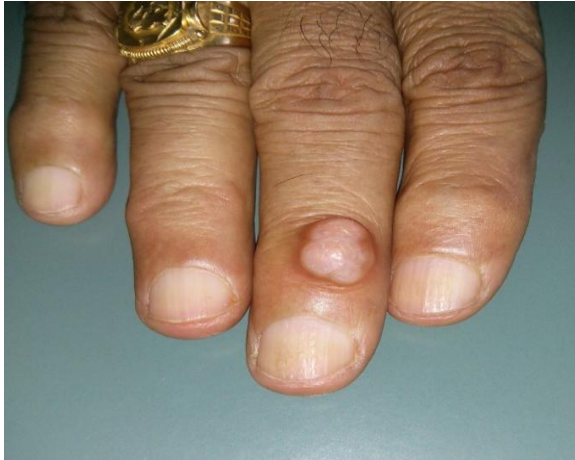

Figure 1: The solitary, translucent, dome shaped papule over the finger.

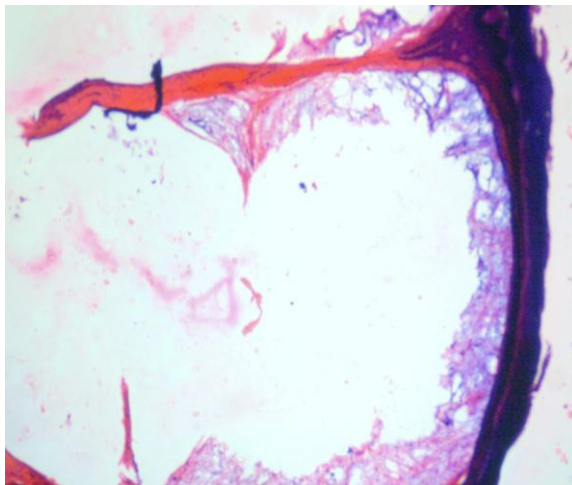


Figure 2: The cyst in mid-dermis showing eosinophilic material in lumen, lined by flattened to cuboidal epithelium.

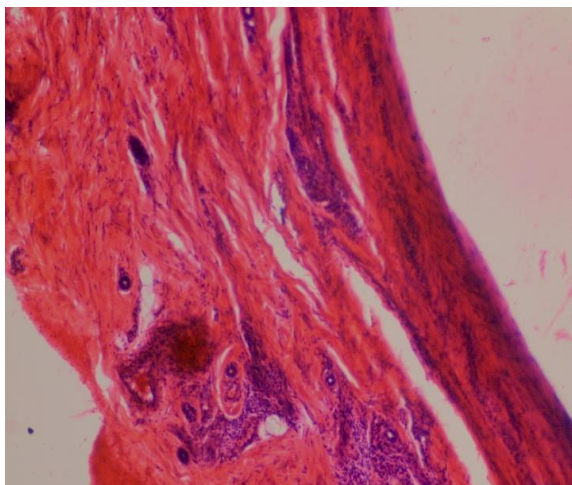


Figure 3: The cyst wall is lined by cuboidal epithelium showing flattening of the lining without decapitation.

DISCUSSION

Eccrine hidrocystomas are benign cystic tumours of sweat glands. [1] It is classified into two types according to the number of lesions: solitary type (the Smith and Chernosky type) and multiple type (the classic Robinson type).

The solitary type is more common, and constitutes 80% of all eccrine hidrocystomas. The multiple type is a relatively rare condition. [2] It usually presents as lesions of the face, trunk, or popliteal fossa. Clinically the lesions are translucent pale blue, dome shaped cystic papules. [3]

The eccrine hidrocystomas are considered to be the result of cystic dilation of excretory eccrine glands. These were thought to be caused by retention of sweat and blockage and dilation of sweat ducts. The retention of sweat is aggravated by increased temperature and physical exercise; hence it shows seasonal variation in hot and humid climate. [4] Microscopically, it is composed of a unilocular cyst lined by bilayered cuboidal epithelium. It is located within mid-dermis or superficial layer of skin, and has a predilection for the area around the eyes. The secretory cells, decapitation of cells is not seen, unlike in apocrine hidrocystomas. [3]

The diseases which may be associated with development of eccrine hidrocystoma are Graves disease, Parkinson disease and Goltz-Gorlin syndrome. [1]

Associated syndromes- Multiple eccrine/apocrine hidrocystomas are associated with Goltz-Gorlin and Schopf-Schulz- Passarge syndromes. [4]

Multiple eccrine hidrocystomas are associated with Graves disease, possibly due to hyperhidrosis, which is seen in hyperthyroid patients. This is supported by the fact that it disappears after treatment of the underlying hyperthyroidism. [4]

It has to be differentiated from apocrine hidrocystoma, epidermal inclusion cyst, mucinous cyst, hemangioma and lymphangioma. [1]

Attention is given to the cysts (apocrine hidrocystoma) because of their close resemblance to serious skin disorders like basal cell carcinoma of eye lid.

Some cysts mimic malignant melanoma because of their colour (blue-black). It is important to exclude these conditions. [4]

A solitary lesion is treated by needle puncture or patient may undergo surgical excision, while multiple lesions can be treated with topical 1% atropine ointment, or scopolamine. Botulinum toxin also has good results in case of multiple eccrine hidrocystoma. [1]

CONCLUSION

Eccrine Hidrocystoma can mimic many skin conditions including Malignant

Melanoma and Basal cell carcinoma. Hence it is important to exclude these conditions with the help of biopsy and Histopathology examination. We would also like to highlight the importance of rare occurrence of this condition in a male patient, at a rare site.

REFERENCES

1. Kubaise. TA. Eccrine Hidrocystoma. Clinical Descriptive Study. 2009 June;7(1)
2. Ta-Ju Liu Ji-Chen Ho. Two Cases of Multiple Eccrine Hidrocystomas with Good Response to Botulinum Toxin. Dermatol Sinica 2009 Sept; 186-190.
3. Weedon D. Weedon's Skin pathology. 3rd ed. China: Churchill Livingstone Elsevier; 2010. Chapter 16, Cyst, sinus and pits; p. 442-56
4. Sarabi K, Khachemoune A. Hidrocystomas - A Brief Review. MedGenMed 2006; 8 (3): 57.

How to cite this article: Shinde U, Mahajan SV, Mahajan SC. Eccrine hidrocystoma over a finger: a rare site. Int J Health Sci Res. 2015; 5(10):374-376.
