

*Review Article*

Clinicopathologic Study of Testicular Tumors: A Review of 50 Cases

Gupta Shruti¹, Shrivastava Alok²¹Assistant Professor, Department of Pathology, GMC Aurangabad, Maharashtra, India.²Associate Professor, Dept of Pathology, Indira Gandhi Government Medical College, Nagpur- 440018, Maharashtra, India.

Corresponding Author: Gupta Shruti

*Received: 31/08/2015**Revised: 21/09/2015**Accepted: 22/09/2015*

ABSTRACT

In view of extreme variability of Testicular tumors, the present study was carried out to classify the various tumors of the testis occurring in patients of Central India in accordance with the WHO classification. In this study spanning over a period of 2 years, clinical presentation of 50 cases of testicular tumor and its relation with histopathological diagnosis were analyzed. Most common clinical presentation was a scrotal swelling. Diagnosis based on gross & histopathological findings revealed Germ cell tumors as the most common testicular tumor.

Keywords: Testicular tumors, WHO Classification.

INTRODUCTION

The testicular tumors are the most common malignancy in men in 15 to 35 year. ^[1] The incidence of testicular germ cell tumors (GCTs) increases shortly after the onset of puberty and peaks in the fourth decade of life with a median age of 34 years at diagnosis. ^[2] It is a matter of great concern because a malignant lesion in an organ, which is so freely accessible for detailed clinical examination, is often missed in the earlier stage.

More than 90% of testicular neoplasms originate from germ cells. However, for a surgical pathologist, anxiety is accentuated by the variability of the testicular tumors and the fact that accurate histological interpretation is a major determinant of treatment and prognosis. Also, the treatment of testicular

tumors has undergone colossal advancements with complete remission possible in the early cases; thus, institution of an early & correct histopathological diagnosis is indispensable.

Due to the varied histomorphologic types, there had been several efforts of classification of testicular tumors in the past before the adoption of the present classification. In 1806, John Abernethy wrote a book "An attempt to form a classification of Tumors". ^[3] Much later in 1904, Collins and Pugh classified testicular tumors based on cell of Origin. ^[4] In 1906, Maurice Chevassu recognized two prevailing types of testicular neoplasms: 1) Seminomas (tumor or seminoma of Chevassu) originating from the spermatogenic line and 2) The mixed tumours growing

from foreign tissue existing in the testis, due to an anomaly of fetal growth. [5]

In 1946 in the article 'Tumors of the Testis: A report of 922 cases' by Dr Nathan B Friedman and Dr Robert A Moore, testicular tumors were classified into four categories: seminoma, embryonal carcinoma, teratoma, and teratocarcinoma. [6]

The International Histological classification of tumors of testis was published by W.H.O. Geneva in 1977. [7] Twenty seven years later, in 2004, the recent classification for testicular tumors was given by the W.H.O. [8]

WHO classification encompasses following major categories:

I. Germ cell tumors: Intratubular germ cell neoplasia, unclassified other types

A. Tumors of one histological type (pure forms)

B. Tumors of more than one histological type (mixed forms)

II. Sex cord/gonadal stromal tumors.

A. Pure forms

B. Tumors containing both germ cell and sex cord/gonadal stromal element-

III. Miscellaneous tumors of the testis

IV. Haematopoietic tumours

V. Tumors of collecting ducts and rete testis

VI. Tumors of paratesticular structures

VII. Mesenchymal tumors of the spermatic cord and testicular adenexa

VIII. Secondary tumors of the testis

MATERIALS & METHODS

A total of 50 cases of testicular tumors were analyzed in this study in regard with their clinical presentation, gross, microscopic findings and investigations.

Selection of Patients: All patients attending the surgery OPD who present with testicular swelling and those admitted in the wards with a solid, firm intratesticular mass that can't be transilluminated.

Exclusion Criteria: Patients in whom swelling was found to be non neoplastic on clinicopathological examination were excluded from study.

A detailed clinical history including chief complaints, past history, history of undescended testis, family history of testicular cancer was taken along with a thorough clinical examination consisting of complete local & systemic examination. Tumor marker studies and Radiological investigations were done when & where feasible. Surgical specimens were obtained in fixatives (10% formalin). After fixation, a comprehensive examination of the Gross Specimen was done under following headings: right or left side, external surface, colour & consistency, size of tumor, encapsulation, appearance of cut surface, colour, necrosis, cystic change or hemorrhage, surrounding testicular tissue, epididymis and spermatic cord. Lymph nodes, if any were also studied. The most representative areas of each case were found and sections were taken of size 1.5 x 1 cm.

Tissue processing was done. Sections were dehydrated in alcohol, cleared in xylol and embedded in paraffin wax. The corresponding blocks were prepared and 3 to 5 micron thick sections were cut from each paraffin block and stained with hematoxylin and eosin stain.

A meticulous microscopic examination was done & lesions were classified on the basis of present WHO classification (2004). [8]

RESULTS

In the present study, carried out over a period of 2 years from July 2012 to October 2014, 50 patients of clinically recognized Testicular masses were studied clinically and histopathological examination was done. Various aspects of clinical presentation were studied. Out of 50 cases studied, 66 % of patients presented with

scrotal swelling only. (Table 1) In our study, the duration of symptoms ranged from less than a month upto 10 months. However, majority of patients visited within 6 months of presentation of symptoms. In the present study, predominant right sided involvement of testis was seen (64%) and Bilateral involvement was seen in only 2 (4%) cases. (Table 2) The present study witnessed a wide range of age distribution ranging from 8 months of age to 70 years. Maximum number of cases was seen in the age group of 21-30 years followed by 31-40 years. (Table 3) Of the 50 cases, 10 were associated with a cryptorchidism.

Table No. 1: Mode Of Presentation Of Testicular Tumors

Mode of presentation	No. of Cases	%
Scrotal swelling only	33	66
Scrotal swelling with pain	6	12
Scrotal swelling with fever	4	8
Scrotal swelling with mass per abdomen	5	10
Scrotal swelling with breathlessness	1	2
Scrotal swelling with gynecomastia	1	2
Total	50	100

Table No.2: Laterality Distribution of Testicular Tumors

LATERALITY	NO. OF CASES	%
RIGHT	32	64
LEFT	16	32
BILATERAL	2	4
TOTAL	50	100

Table No. 3: Age Distribution of Testicular Tumours

AGE (IN YRS)	No. of CASES	%
<10	3	6
11-20	5	10
21-30	19	38
31-40	12	24
41-50	6	12
51-60	1	2
> 61	4	8
TOTAL	50	100

On histologic typing of the 50 cases according to the WHO classification (Table 4), [8] a predominance of Germ cell tumors was seen. Of the 50 cases, 31(62%) were Germ cell tumors of one histological types including 21 cases of Classical Seminoma, 5 cases of Teratoma, 3 cases of Yolk Sac Tumor & 1 case each of Spermatocytic Seminoma & embryonal carcinoma and 14 (28%) were testicular germ cell tumors of

mixed histological types along with 1 case of Sex cord Stromal tumor & 3 cases of lymphoma. A single case of Intratubular germ cell neoplasia was also found. Also, out of 50 cases, 10 masses were associated with other pathology along with tumour. Associated pathologies found were cryptorchidism & hydrocoele. 2 cases of Mixed Germ Cell Tumour & 1 case each of ITGCN, Seminoma & Teratoma were found to be associated with cryptorchid testis. 3 cases of Seminoma & 2 case of Mixed Germ Cell Tumour had concomittant hydrocoele.

Metastasis was noted in 8, out of our 50 cases & most common of site of metastasis was found to be intraabdominal lymph nodes.

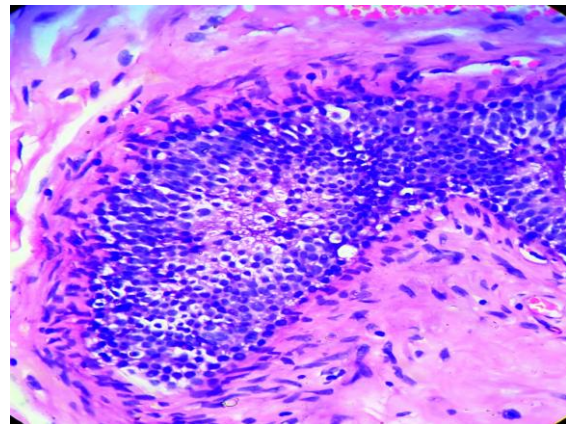


Figure 1. Photomicrograph showing a focus of Intratubular Germ cell neoplasia.

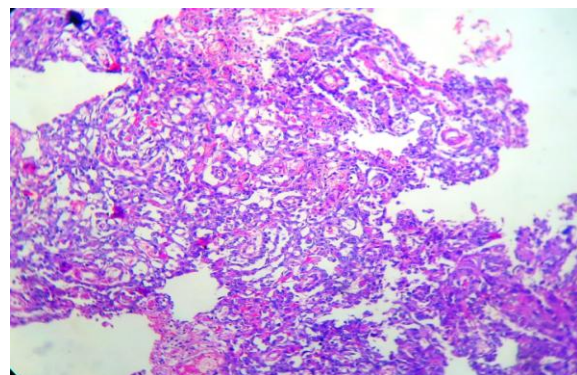


Figure2. Photomicrograph showing anastomosing glands & papillae lined by columnar cells and the characteristic Schiller Duval bodies, diagnostic of Yolk sac tumour .

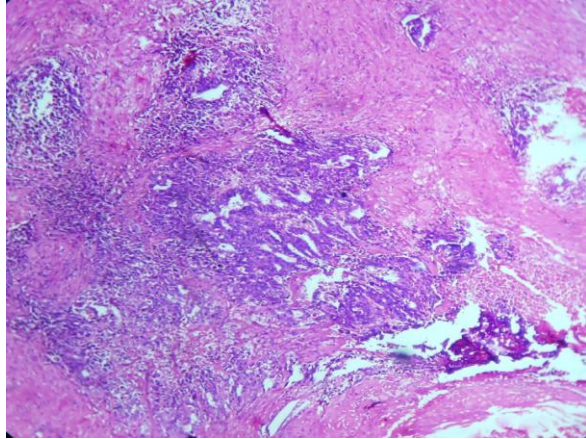


Figure3. Photomicrograph showing papillary growth pattern & high grade cytological features in a pure Embryonal carcinoma.

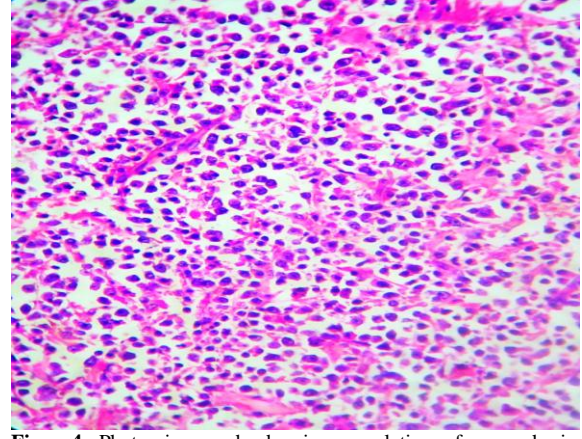


Figure4. Photomicrograph showing population of non-cohesive cells with amphophilic cytoplasm, round to oval nuclei, eccentric vesicular nucleus with prominent nucleoli, diagnostic of Non Hodgkin's lymphoma.

Table no.4: distribution of testicular tumours accor. To who classification

HISTOLOGIC TYPING	No. of Cases	%
1. GERM CELL TUMOURS		
(A). INTRATUBULAR GERM CELL NEOPLASIA	1	2
(B). TUMOURS OF ONE HISTOLOGICAL TYPES	31	62
SEMINOMA	21	42
SPERMATOCYtic SEMINOMA (WITH SARCOMATOUS TRANSFORMATION)	1	2
EMBYRONAL CARCINOMA	1	2
YOLK SAC TUMOUR	3	6
TERATOMA	5	10
(C). TUMOURS OF MORE THAN ONE HISTOLOGIC TYPES	14	28
EMBYRONAL CARCINOMA + TERATOMA (TERATOCARCINOMA)	2	4
SEMINOMA + YOLK SAC TUMOUR	5	10
TERATOMA + YOLK SAC TUMOUR	3	6
SEMINOMA + TERATOMA	2	4
EMBRYONAL CA + YOLK SAC TUMOR	2	4
2. SEX CORD STROMAL TUMOURS		
LEYDIG CELL TUMOR	1	2
3. LYMPHOMA	3	6
TOTAL	50	100

DISCUSSION

In the present study, 50 patients of testicular tumors were studied. Various parameters relating to clinicopathologic aspect were studied thoroughly and compared with the various other renowned authors who studied testicular tumors. In our study, age of patients presenting with testicular tumours ranged from 8 months - 70 years old. Average age was found to be approx. 35.5 years. Our findings were quite similar to the findings of Salako A.A. et al (2010), [9] who found age variation 4-70 years of age. We found maximum number of cases in age range 21-30 years (19 cases). (Table No. 1). Our findings were in

concordance with the findings of various other authors: Fischer C.G *et al* (1998) [10] 25-35 years, Gill et al (2000):- [11] 20-29 years, Salako A.A. et al (2010):- [9] 20- 39 years, Shirish et al (2012):- [12] 21-39 years etc.

Testicular tumours in our study were predominantly Right sided (64 %). Right sided predominance for testicular tumours was observed by various other authors in their studies as Deotra et al [13] (60%), Shirish et al [12] (56%). Bilateral involvement was seen in 2 (4%) cases. Approximately, similar percentages of bilaterality has been reported by different authors as Collins & Pugh [14] (2.3%), Gill et al [11] (1.57%) etc.

In our study 92 % (ie. 46 cases) of tumors were diagnosed as Germ cell tumors and 8% were diagnosed as Non Germ cell tumours on histopathology. Our findings were particularly very close to the findings of Moghe et al (1970) [15] and Tsung-Hsun Tsai et al (2007). [16] Among the Germ cell tumors, 31 tumors were of one histologic type including single case of Intratubular Germ cell Neoplasia (Figure 1) and 14 tumors belonged to the category of mixed histologic types.

Among the tumors of one histologic type, Seminoma was the most common neoplasm in the present study constituting about 42 % of all tumors. Our finding was comparable with the studies of various authors Moghe et al [15] (41.6%), Mushtaq et al [17] (44.4%) etc. Weir HK et al (1999), [18] studied in 1964 – 1996 found 5156 cases of testicular germ cell cancer, about half of the cases (54.3%) were seminomas. In our study, most common non seminomatous germ cell tumor of one histologic type was found to be Teratoma which constituted 10 % of all testicular tumors. Salako et al (2010) [9] found 12.5% of teratomas out of 26 cases studied of testicular and para testicular tumors over 17 years. Next most common were Yolk sac tumors (Figure2) comprising about 6% of all neoplasms. The rare ones in our study were embryonal carcinoma (Figure3) & spermatocytic seminoma. The incidence of embryonal carcinoma in various series showed wide range from 1.5 to 30 % of germ cell tumors. This is perhaps due to different interpretation of this term by different workers.

Among germ cell tumors of more than one histologic type, most common combination was Seminoma with Yolk sac tumor followed by a combination of Teratoma & Yolk sac tumor. The mean age of presentation was 38.5 & maximum cases were seen in the second decade. Two cases

of Teratocarcinoma & two cases each of Embryonal carcinoma with Yolk sac tumor, Seminoma with Teratoma were also found.

Among the Non Germ cell tumors, A single case of Sex cord stromal tumor diagnosed as Leydig cell tumor on histopathology was reported in our study along with 3 cases (6%) of lymphomas, all diagnosed as Non Hodgkin's lymphoma (Figure 4). The relative frequency of Lymphomas in various studies varies widely, however our findings were close to Gill et al [11] (8.23 %) & Shirish et al [12] (6%).

In the present study, 10 % of Germ cell tumours were found to be associated with undescended testis which is quite close to previous authors. According to Woodward P.J. (2004), [19] history of cryptorchidism was present in 3.5 – 14.5% of patients with testicular tumors. Other 5 (10%) cases of Germ cell tumours were associated with hydrocoele. In a study of 125 cases Gupta V.P. *et al* (1980) [20] observed secondary hydrocele in 11 cases (8.8%). According to Mahalik S.K. *et al* (2011), [21] 15-50% of patients with testicular tumors have associated hydrocele.

CONCLUSION

Our study concluded that testicular tumors present with the typical clinical presentation but histomorphologic forms are varied ranging from Germ cell origin to lymphomas. Most common presenting complaint is painless scrotal swelling. Maximum number of patients was seen in the age range of 21-30 years and Majority of patients presented within 6 months of symptoms. Right side of the testis gets affected in most of the cases. Histologically, the most common testicular tumours were Germ Cell tumours (92 %) followed by lymphomas. Our study thus emphasizes the clinico-histologic correlation & need for the

apt categorization of the various tumours of the testis.

REFERENCES

1. Russell SS. Testicular Cancer: Overview & Implications for health care providers. *Urol Nurs*.2014Jul-Aug;34(4):172-6,192
2. Armita Bahrami, Jae Y. Ro, and Alberto G. Ayala (2007) An Overview of Testicular Germ Cell Tumors. *Archives of Pathology & Laboratory Medicine: August2007, Vol.131, No.8, pp.1267-1280.*
3. A Program for the Conquest of Cancer: 1802. *Journal of history of medicine and allied sciences*. 1975; XXX (1):3-22.
4. Collin and Pugh. Cell of origin of Testicular tumour *Br.J.Urol* 1964; 36(2) 1-11.
5. Androutsos G. Maurice Chevassu (1877-1957): A pioneer of the study and therapy of testicular neoplasms. *J BUON*. 2003 Apr-Jun; 8(2):185-90.
6. Friedman & Moore. Tumours of the testis - A report on 922 cases. *Millett Surg* 1946; 99:573.
7. Mostofi FK, Sobin LH. International histological typing of testes tumor WHO, Geneva, 1977.
8. Eble J.N., Sauter G., Epstein J.I., Sesterhenn I.A. The World Health Organization classification of tumors of the urinary system and male genital system. Lyon, IARC Press, 2004.
9. Salako AA. Testicular and paratesticular tumours in south western Nigeria. *Afr Health Sci*.2010;10(1):14-17.
10. Fischer CG, Waechter W, Kraus S, Perez EF, Weidner W, Dudeck J. Urologic tumors in the Federal Republic of Germany. *Cancer* 1998;82:775.
11. Gill MS, Shah SH, Soomro IN, Kayani N, Hasan SH. Morphological Pattern of Testicular Tumors. *Journal of Pakistan medical association*. 2000;50(4):110-3.
12. Shirish Chandanwale, Ramanpreet Chawla, Archana Buch, Arpana Dharwadkar, Charusheela Gore, Mohit Rajpal. Pathology of Testicular Tumors - Review of 50 cases. *Int J Pharma Biomed Sci* 2012;3(4):167-176.
13. Deotra A, Mathur DR, Vyas MC. A 18 years study of testicular tumours in Jodhpur, western Rajasthan. *J Postgrad Med*.1994; 40:68-70.
14. Collins DH, Pugh RCB. Classification and frequency of testicular cancer. *Br J Urol* 1964, 36 (suppl 1), 1-11.
15. Moghe KV, Agarwal RV, Junnarkar RV. Tumours of the testis. *The Indian Journal of Cancer*. 1970 Jun: 90-97.
16. Tsung-Hsun Tsai, Shou-Hung Tang, Yi-Cheng Huang, Seng-Tang Wu, Shang-Sen Lee, Tai-Lung Cha. *J Med Sci* 2007; 27(3):121-124. <http://jms.ndmctsgh.edu.tw/2703121.pdf>
17. Mushtaq S, Jamal S, Mamoon N, Akbar N, Khadim T. The pathological spectrum of malignant testicular tumours in northern Pakistan. *J Pak Med Assoc*. 2007 Oct;57(10):499-50.
18. Weir HK, Marrett LD, Moravan V. Trends in the incidence of testicular germ cell cancer in Ontario by histologic subgroup, 1964 – 1996. *CMAJ*. 1999 Jan 26;160(2):201-05.
19. Woodward PJ. Case 70: Seminoma in an Undescended Testis. *Radiology* 2004, 231, 388.
20. Gupta VP, Chopra HL, Nagpal BL. Tumours of testis. *Indian J Pathol Microbiol* 1980; 23(2): 155-9.
21. Mahalik SK, Prasad A, Bhalla S, Kulshreshtha R. Transilluminating testicular mass. *Indian J Paediatr Oncol* 2011Jan; 32(1) 46-8.

How to cite this article: Gupta S, Shrivastava A. Clinicopathologic study of testicular tumors: a review of 50 cases. *Int J Health Sci Res*. 2015; 5(10):324-329.
