



Case Report

## Sacralisation of Lumbar Vertebra with Associated Partially Deficient Dorsal Wall of Sacral Canal- A Case Report

Apoorva D<sup>1</sup>, Shishirkumar<sup>1</sup>, Girish V Patil<sup>2</sup>, Thejeshwari H G<sup>1</sup>

<sup>1</sup>Assistant Professor, <sup>2</sup>Associate Professor,  
Department of Anatomy, DM- Waynad Institute of Medical Sciences, Meppadi, Kerala, India.

Corresponding Author: Apoorva D

Received: 01/08/2014

Revised: 26/08/2014

Accepted: 28/08/2014

### ABSTRACT

Back pain is the most common complaint in the modern life. Sacralisation of lumbar vertebra seems to be the most common cause under debate. Addition of sacral elements by the incorporation of fifth lumbar vertebra is known as sacralisation. Sacralisation could be unilateral or bilateral, complete or incomplete. During routine study of vertebral column, we noticed sacralisation of fifth lumbar vertebra with non fusion of lamina of first sacral vertebra in one of the sacrum, in the Department of Anatomy, DM WIMS College, Meppadi, Waynad. This sacrum had six vertebrae instead of five vertebrae as in the normal sacrum. There were five sacral foramina on right side due to complete fusion of abnormal transverse process of fifth lumbar vertebra. But, there were only four sacral foramina on the left side due to incomplete fusion i.e Unilateral Sacralisation. Well defined sacral promontory was absent. So we identified this variation as sacralisation of fifth lumbar vertebra and S1 vertebra was less developed as like S2.

These variations may be found in patients during radiological investigations complaining of low back pain. Lumbosacral transitional vertebrae are due to its embryological origin. These variations may affect normal function because of compression of nerves, soft tissue and ligamentous strain between joints. Knowledge of this variation is important to diagnose lower back pain, sciatica, disc prolapse and is helpful in procedures like spinal anaesthesia and lumbar puncture.

**Keywords:** Lumbar Puncture, Non fusion of lamina, Sacral Foramina, Sacralisation, Spinal Anaesthesia

### INTRODUCTION

Lumbo Sacral Transitional Vertebrae (LSTV) are the common congenital anomalies of the human spine. This includes sacralisation of fifth lumbar vertebra and lumbarisation of first sacral vertebra. This was observed for the first time by Bertolotti in the year 1917. This condition occurs due to defect in the segmentation of the lumbosacral spine during development. <sup>[1]</sup>

Although the condition has an incidence of over 12% in the general population, knowledge about the exact clinical implications is still lacking. The association of early degeneration of the disc above the LSTV in young patients has been reported in few previous studies. <sup>[2]</sup>

The sacrum is a large, triangular fusion of five vertebrae and forms the posterosuperior wall of pelvic cavity,

wedged between the two hip bones. Sacrum may contain six vertebrae, by development of additional sacral element or incorporation of the fifth lumbar or first coccygeal vertebrae. Inclusion of fifth lumbar vertebra is known as sacralisation is usually incomplete and limited to one side. In the most minor degree of the abnormality a fifth lumbar transverse process is large and articulates, sometimes by a synovial joint, with the sacrum at the posterolateral angle of its base. In case of lumbarisation, the bodies of first two sacral vertebrae may remain unfused when the lateral masses are fused. [3]

The prevalence of LSTV reported in the literature ranges from 4 to over 35%. Many of the studies further divided LSTV into lumbarisation and sacralisation with a mean prevalence of 5.5% and 7.5% respectively. [2]

### CASE FINDINGS

During the routine study of bones in the Department of Anatomy at DM Waynad Institute Of Medical Sciences, Meppadi, Kerala, we observed an unusual unilateral sacralisation of lumbar vertebra with non fusion of lamina of L5, S1 and partially S2 leading to deficient dorsal wall of the sacral canal.

We followed a simple score system followed by Khairnar K B and Rajale M B.

In the score system, the six structures assessed were the left and right inferior articular facets, left and right transverse processes, and the left and right sides of the vertebral body. A score given in such way that 1 point is awarded for

- a) Unilateral fusion of vertebral body (rt or lt half)
- b) Unilateral fusion of transverse process (rt or lt half)
- c) Unilateral fusion of inferior articular process (rt or lt half)

So ultimately 2 points were awarded for bilateral fusion i.e. rt half (1) + lt half (1)=2.

In our case there was unilateral fusion of vertebral body, transverse process and inferior articular process only on right side amounting to the total score 3.

The body of fifth lumbar vertebra was less massive. Thus, lumbosacral angle was ill defined. The transverse process of fifth lumbar vertebra on the right side was completely fused with the sacrum whereas on the left side it was incomplete. Thus, the sacral foramina on the right side were complete. When the size of the first sacral foramina formed by fifth lumbar vertebra is compared with the second sacral foramina formed by S1, there was gross difference in the size between them. The size of the sacral foramina on the right and left side has been mentioned in the table 1.

TABLE 1: Comparison of diameters of sacral foramina between pelvic and dorsal surface

Vertebral level	Side	Diameters of sacral foramina on pelvic surface		Diameters of sacral foramina on dorsal surface	
		Max horizontal diameter in mm	Max vertical diameter in mm	Max horizontal diameter	Max vertical diameter
L5	Right	0.8	1.2	0.8	2.4
	Left	-	-	-	-
S1	Right	1.1	1.5	0.6	1.2
	Left	1.3	1.7	0.8	1.2
S2	Right	1.0	1.7	0.6	0.7
	Left	0.8	1.2	0.6	0.6
S3	Right	0.6	0.8	0.8	0.5
	Left	0.8	0.7	1.0	0.5
S4	Right	0.7	0.4	0.4	0.9
	Left	0.7	0.5	1.0	0.8

The dorsal wall of the sacrum was partially deficient at the level L5, S1 and S2. Transverse diameter of the body of L5 was 49.2mm and the anterior posterior diameter was found to be 29.4mm. The straight length of the sacrum on its pelvic surface was found to be 114.5 mm and curved length 126.8mm.

TABLE 2: Castellvi classification of lumbosacral vertebrae

SL.NO	CASTELLVI CLASSIFICATION OF LUMBOSACRAL VERTEBRAE	
	Types of Lumbosacral Transition Vertebra	Includes
1.	Type I	Dysplastic transverse process with more than 19mm
	(a)	Unilateral
	(b)	Bilateral
2.	Type II	Incomplete lumbarisation /sacralisation with enlarged transverse process
	(a)	Unilateral
	(b)	Bilateral
3.	Type III	Complete lumbarisation/ sacralisation with complete fusion of transverse process of fifth lumbar vertebra to the sacral ala
	(a)	Unilateral
	(b)	bilateral
4.	Type IV	Mixed variety of Type IIa on one side and Type IIIa on other side

On the pelvic surface, bodies of sacral vertebrae were completely fused. Whereas there was partial fusion of the body of the L5 and upper margin of the ala of the sacrum in the right lower margin .

Table 3: Clinical Assessment Of Pain Due To Lstv

	CLINICAL ASSESMENT OF PAIN DUE TO LSTV
Firstly	1.Discogenic pain , degenerated in the disc above the transitional vertebra( type II, III, IV) 2. Bulging of the herniated disc may cause nerve root compression -sciatica 3. Nerve roots may be compressed between the transverse segment of LSTV and the sacral ala(type II)
Secondly	Pain may be generated in the articulation between the enlarged transverse process and the sacral als and ilium( type II)
Thirdly	Contra lateral low back pain in patients with unilateral LSTV- reflects facetogenic pain

The transverse process of the right side of L5 was completely fused with that of

S1, whereas it was not fused on the left side, showing complete but unilateral sacralisation of L5. Along the medial sacral crest, spines of all sacral segments were well developed. So, sacral hiatus was normal in its location, the apex of the hiatus being at the junction between S4 and S5 and was inverted 'v' shaped. The antero-posterior diameter of sacral canal at the level of apex of sacral hiatus was found to be 4mm. The length of sacral hiatus was found to be 3.2mm.

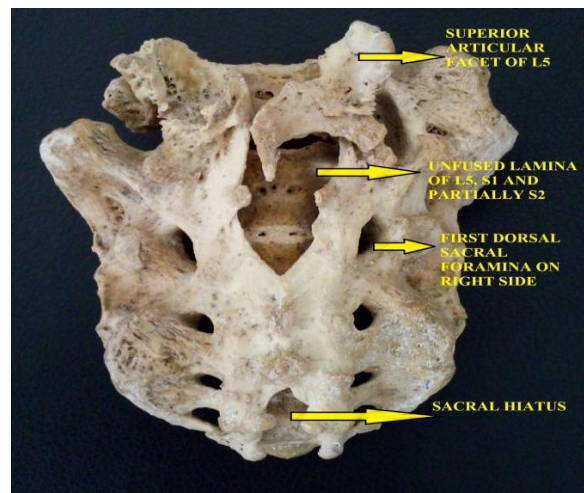


Fig 1: Dorsal Surface Of Sacrum

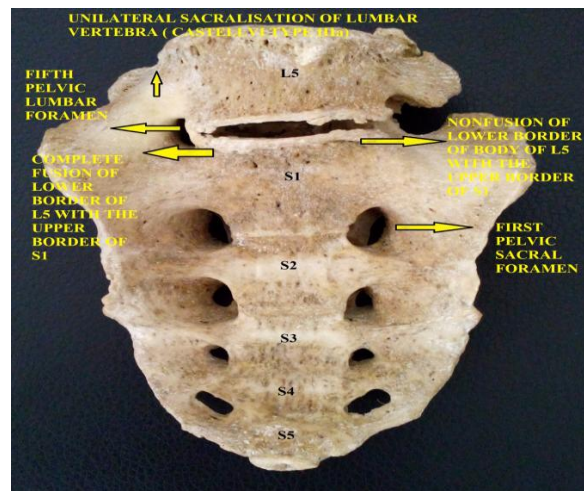


Fig 2: Pelvic Surface Of Sacrum

## DISCUSSION

The lumbosacral spine is important as it protects the spinal cord and spinal

nerves. The weight of the body is transmitted to the lower limbs by lumbosacral spine. Thus, plays an important role in locomotion and posture of the body. [4]

Bertolotti M showed the association of lumbosacral transition vertebrae and the low back pain. This was known as Bertolotti's syndrome. This is characterised by the presence of a variation of the fifth lumbar vertebra having a large transverse process, either articulated or fused with sacral base or iliac crest and producing a chronic, persistent low back pain due to arthritic changes occurring at the site of pseudoarthrosis. [5]

Differences in the prevalence of lumbosacral transition vertebrae may be explained by the differences in the diagnostic criteria, imaging techniques and other confounding factors between the investigated population samples. [2]

In 2001, Welkin et al, showed that in the absence of HOX 11 function, sacral vertebrae are not formed and instead these vertebrae assume a lumbar identity. Also, they showed that in the absence of HOX 10 function, no lumbar vertebrae are formed. Thus, they concluded that Lumbosacral transition vertebrae result from mutations in the HOX 10 and HOX 11 genes. [6]

No difference was found in the overall incidence of the structural pathology of the spine. However, they found secondary pathologic spinal conditions like bulging disc or disc herniation were nine times more common at the level immediately above the transitional vertebra compared to patients without LSTV.

Luoma et al showed that disc degeneration above the LSTV (Lumbo Sacral Transitional Vertebrae) was more frequent in young patients. During aging these degenerative disc changes became less obvious and were masked by regular degenerative changes. Also, this study

concluded that LSTV is reported to prevent the development of degenerative disc disease of the disc below the LSTV. The articulation or fusion between the transverse process of the LSTV and the sacrum has been assumed to restrict rotational and bending movements and thereby protect the disc below. [7]

Also, in the prospective studies by Vergauwen et al and Oguz et al, to see the significance in the facet joint arthrosis and foraminal stenosis to occur more significantly in the patients with LSTV, found no statistically significant differences in the patients with or without LSTV. [8]

In 1983 Castellvi, classified lumbosacral transition into four types. [9] This has been mentioned in table 2.

According to the above classification, our sacrum was of Type III a.

There is so much controversy with regard to whether such an abnormal vertebra produces or not symptoms of low back pain. Brault et al has described the clinical assessment for different types of LSTV which has been described in table 3.

The occurrence of Lumbo-Sacral Transitional Vertebra (LSTV) is linked to its embryological development. Development of lumbar vertebra, commences at 3<sup>rd</sup> week of intrauterine life. All vertebrae originate from the somites that form along the cranial caudal axis, on either side of the notochord, from presomatic mesoderm. Ossification of vertebra begins in 8<sup>th</sup> week and ends by 25<sup>th</sup> year. There are two primary centers and five secondary centers present in each vertebra. The primary cause of LSTV is the cranial shifts that means sacralisation of the last lumbar vertebrae and partial shifts which means unilateral fusion of the transverse processes. [10]

The secondary centers of ossification appear after puberty and all the sacral vertebrae starts fusing with each other. Any defect in the formation of the primary



centers (which give rise to the formation of each half of the vertebral arch) will lead to incomplete ossification of the laminae.

The relation between the sizes of the sacral foramina with the LSTV needs further studies for correlation.

Deficient dorsal wall of the sacral canal is due to non fusion of the lamina of the fifth lumbar vertebra. Imperfect development of spines could also be the other important cause. [3]

Wrong level emergency decompression, in a patient with a cauda equina syndrome, due to neglecting complete lumbarisation of S1 has been reported by Malanga and Cook. [11]

Thus, the knowledge of LSTV is of utmost importance in spinal surgeries.

## CONCLUSION

Among benign anatomical variation of lumbosacral spine, LSTV is very often encountered by the spinal surgeon. Failure to recognize and to number LSTV during spinal surgery may have serious complications. As in the present case, unilateral defect types give rise to increased intensity of pain due to uneven weight bearing. Incorrect numbering can theoretically lead to problems with the administration of epidural or intradural anaesthetic drugs in LSTV patients. LSTV is of utmost importance in spinal surgeries, especially if the surgery is performed in the absence of regular plain radiographs. In patients who present with low back pain and a LSTV diagnosed by a plain radiographs, the clinician should be aware of secondary spinal disorders like disc degeneration and disc herniation above LSTV, facet joint arthrosis at the level of LSTV. Therefore, in selected cases additional imaging methods like CT, MRI and SPECT may be considered. LSTV with non fusion of the lamina of the S1, with the normal sacral hiatus is a rare deformity. A comprehensive

awareness and understanding of the lesion helps spinal surgeon, orthopaedician, radiologists, gynecologists in dealing with such cases.

## REFERENCES

1. Dharathi K, Nagar SK , Ojaswini M, Dipali T, et al. A study of sacralisation of fifth lumbar vertebra in Gujarat, National Journal of Medical Research. 2012; 2 (2): 211-213
2. Bron J L, Barend J, Van Royen V, Paul I J M, Wuisman. The clinical significance of lumbosacral transitional anomalies. Acta Orthop. Bel, 2007;73(6): 687-695
3. Standring S, Borely NR, Collins P, Crossman AR, Gatzoulis MA, Healy JC, et al. Gray's Anatomy: The Anatomical Basis of Clinical Practice. 40<sup>th</sup> ED, London: Elsevier Ltd; 2008: P 724-728
4. Samreen P, Shashikala L, Rohini K. Lumbarization of first sacral vertebra: A case report. International Journal of Basic and Applied Medical Sciences, 2012; 2(2): 154-157
5. Bertolotti M . (1917). Contributo alla conoscenza dei vizi differenziazione regionale del rachide con special riguardo all assimilazione sacrale della V. lombare. *La Radiologia Medica*. 4 113-144.
6. Wellik DM, Capecchi MR. (2005). Hox 10 and Hox 11 genes are required to globally pattern the mammalian skeleton. *Science* 301(5631) 363-367.
7. Luoma K, Vehmas T, Raininko R, Luukkonen R, Riihimäki H. Lumbosacral transitional vertebra : relation to disc degeneration and low back pain. *Spine* 2004 ; 29 :200-205.
8. Vergauwen S, Parizel PM, van Breusegem L *et al*. Distribution and incidence of degenerative spine changes in patients with a lumbo-sacral transitional vertebra. *Eur Spine J* 1997 ; 6 : 168-172.
9. Castellvi AE, Goldstein LA, Chan DPK (1983). Lumbosacral transitional

vertebra and their relationship with lumbar extradural defects. *Spine*. 9(5) 493-495.

10. Keith. L. Moore, T.V.N. Persaud, The Developing human, clinically oriented embryology

Skeletal system. 8th edition, published by Saunders, Elsevier, Philadelphia, 2008: 344-346

11. Malanga GA, Cooke PM. Segmental anomaly leading to wrong level disc surgery in cauda equina syndrome. *Pain Physician* 2004 ; 7 : 107-110.

How to cite this article: Apoorva D, Shishirkumar, Patil GV et. al. Sacralisation of lumbar vertebra with associated partially deficient dorsal wall of sacral canal- a case report. *Int J Health Sci Res*. 2014;4(9):397-402.

\*\*\*\*\*

**International Journal of Health Sciences & Research (IJHSR)**

**Publish your work in this journal**

The International Journal of Health Sciences & Research is a multidisciplinary indexed open access double-blind peer-reviewed international journal that publishes original research articles from all areas of health sciences and allied branches. This monthly journal is characterised by rapid publication of reviews, original research and case reports across all the fields of health sciences. The details of journal are available on its official website ([www.ijhsr.org](http://www.ijhsr.org)).

Submit your manuscript by email: [editor.ijhsr@gmail.com](mailto:editor.ijhsr@gmail.com) OR [editor.ijhsr@yahoo.com](mailto:editor.ijhsr@yahoo.com)