



Case Report

Unilateral Duplication of the External Jugular Vein: A Case Report with Embryological Significance and Clinical Implications

Suresh B S¹, Shivaleela C², Kumar G V³

¹Professor of Anatomy, ²Assistant Professor of Anatomy, ³Assistant Professor of Pediatrics, Sri Siddhartha Medical College, Tumkur, Karnataka, India.

Corresponding Author: Kumar G V

Received: 25/07/2014

Revised: 13/08/2014

Accepted: 16/08/2014

ABSTRACT

The external jugular vein, one of the main superficial veins of the head and neck, drains blood mostly from the scalp and the face. It is formed by the union of the posterior division of the retromandibular vein with the posterior auricular vein. Here we present a case report of two external jugular veins emerging from the lower border of the parotid gland on the right side in a male cadaver aged about 60 years. The present case report mainly highlights the occurrence of this rare variation, its embryological basis and clinical implications.

Key words: External jugular vein, Facial vein, Retromandibular vein, Variations.

INTRODUCTION

The word jugular means neck. Veins of the neck are superficial or deep to the deep fascia. Deviation from the normal pattern in the vascular system is a common feature and it is far commoner in the veins than in the arteries. The relevance and importance of varied drainage patterns of the veins of the head and neck warrant attention for their use in surgeries involving micro vascular anastomoses. The external jugular vein, one of the main superficial veins of the head and neck, drains blood mostly from the scalp and the face. It is formed by the union of the posterior division of the retromandibular vein with the posterior auricular vein. It begins at the level of the angle of the mandible or in the parotid gland and runs down the neck towards the middle

of the clavicle. It crosses the sternocleidomastoid muscle obliquely and in the subclavian triangle, perforates the deep fascia. It crosses the transverse cervical nerve and its upper half runs parallel to the great auricular nerve which ascends behind it. It varies in size, occasionally being double. ^[1] The relevance and importance of varied drainage patterns of the veins of the head and neck warrant attention for their use in surgeries involving micro vascular anastomoses. ^[2] The clinical importance of this vein lies in the fact that it is used as a venous manometer and for catheterization. It is important medico-legally and for surgeons who do head and neck surgeries they have to avoid it while executing a submandibular incision to expose the mandible. It is also a

preferred option in the head and neck free tissue transfer as the recipient vein. [3]

CASE REPORT

On routine dissection for undergraduate students in a male cadaver aged about 60 years in the department of anatomy, Sri Siddhartha medical college, Tumkur, Karnataka, India, a unilateral variation in external jugular vein was noticed on right side. On left side of the neck a single external jugular vein was seen. But on right side two external jugular veins were seen emerging from the lower border of the parotid gland. Both veins cross the superficial surface of the sternocleidomastoid muscle obliquely & then pierce the deep fascia of the posterior triangle just above the clavicle. Finally both join the subclavian vein separately. Posterior external jugular vein was seen joining the right external jugular vein at the middle of the posterior triangle. The specimen was photographed (figure-1).

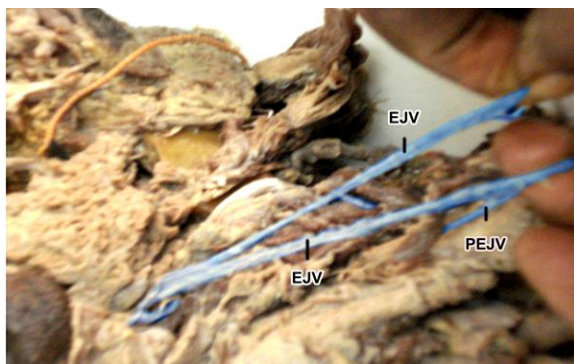


Figure-1: Showing double external jugular vein on the right side (EJV)
PEJV- Posterior external jugular vein

DISCUSSION

The external jugular vein receives the blood from the greater part of the face and scalp. The external jugular vein is one of the variable veins. Several variations of external jugular vein have been reported by Bergman et al [4] which include: (a) Formation merely by the posterior auricular

vein. (b) Receiving the facial, lingual or the cephalic veins as tributaries. (c) Passing over the clavicle and opening into the cephalic, subclavian or internal jugular veins. (d) Doubling of the vein. (e) Formation of an annulus around the clavicle.

The veins draining the regions of head and neck establish their identity only after the development of skull. The external jugular vein arises as a secondary channel from a capillary plexus derived from a tributary of cephalic vein, from the tissues of the neck and anastomoses secondarily with the anterior facial vein. [5] Nayak et al described a case where external jugular vein was formed by the union of facial vein and undivided retromandibular vein where the posterior auricular vein was absent and external jugular vein had a communication with cephalic vein. [6] Choudhary et al presented a case where bilaterally undivided retromandibular vein continued as external jugular vein after receiving posterior auricular vein and facial vein obliquely. [7] Bertha et al described a case where bilaterally, undivided retromandibular vein joined with facial vein to form a common trunk, which in turn drained into same sided superior venacava. [8] In the present case, on right side two external jugular veins are seen emerging from the lower border of the parotid gland. Both veins cross the superficial surface of the sternocleidomastoid muscle obliquely & then pierce the deep fascia of the posterior triangle just above the clavicle. Finally both join the subclavian vein separately.

Embryological aspects

Individual capillaries enlarge, join with adjacent ones and form larger channels. Superficial plexus of capillaries ultimately give rise to primary head veins which finally form superficial veins of head and neck. [9] The embryology of veins of the scalp, face and neck has not been clearly understood. Disappearance of the principle cephalic vein

formed in early embryonic life necessitates the formation of venous spaces which in turn fuse and form channels and finally form facial and pharyngeal veins. These venous spaces enlarge at some places and diminish at others, which may result in variations. Some primitive channels evolve, enlarge and form the definitive ones. Two venous channels are observed in this region in an embryo with a length of 10 mm i.e. the primitive maxillary vein and the ventral pharyngeal vein which drain the rapidly growing mandibular and the hyoid arches into the common cardinal vein. Simultaneously, a small cranial tributary of the primitive cephalic vein in the arm at stage 6 has grown larger in the differentiating tissues of the neck and joins the jugulocephalic vein which is cranio dorsal to the cartilaginous clavicle, which is now surrounded by a venous ring. The caudoclavicular part of this ring is a new anastomosis whereby the definitive cephalic vein overcomes its jugulocephalic detour and becomes directly continuous with the subclavian vein now definitive. The old proximal end of the primitive cephalic vein, which is the cranio dorsal part of the clavicular venous ring, may be recognised as a trunk of the adult external jugular vein. The part of the venous ring which is ventral and superficial to the clavicle i.e. the jugulocephalic segment of the primitive cephalic vein often dwindles at stage 6 and is usually lost. Further, the developing external jugular vein makes two connections, anterior and posterior with the facial vein and with the retromandibular vein respectively. Under normal circumstances, the anterior connection disappears so that the facial vein continues to drain via the common facial vein into the precardial vein (adult internal jugular vein), whereas the posterior connection persists, so that the retromandibular vein drains into the external jugular vein. [10]

The superficial veins of the head and neck, especially the external jugular vein are increasingly being utilized for cannulation to conduct diagnostic procedures or intravenous therapies. [11-13] The inspection, auscultation and Doppler sonographic examination of the jugular veins may give a clue for the diagnosis of cardiac diseases. [14]

Ultrasound guided venipuncture is a viable possibility in cases of variations in the pattern of the superficial veins. So, their knowledge is important for surgeons who do reconstructive surgery, [13] radiologists who do catheterization and clinicians in general. [15] Veins on the right side of the neck are commonly used for assessing venous pressure and for cannulation. External jugular vein is used by clinicians for therapeutic procedures and monitoring. The knowledge of variations in venous patterns in neck region is importance for surgeons in order to avoid unnecessary bleeding during surgical procedures.

CONCLUSION

Superficial veins especially external jugular vein are increasingly used for cannulation for diagnostic procedures as well for intravenous therapies. Ultrasound guided venipuncture is a viable possibility in cases of variations in patterns of superficial veins. Knowledge of these variations is important for surgeons to perform the reconstructive surgeries and to avoid any intraoperative error in procedures which might lead to unnecessary complications.

REFERENCES

1. Standing S, Berkovitz B KB. Neck. In: Standing S. Gray's anatomy: The anatomical basis of clinical practice. 39th edition. Edinburgh, London: Elsevier Churchill living stone; 2005, 1428-31.
2. Mehra S, Kaul J.M, Das S. Unusual Venous Drainage Pattern Of Face, A

- Case Report. Journal of Anatomical society of India. 2003; 52: 64-5.
3. Rajan Kumar Singla, Sanju Singla, Kanika Sachdeva. Partial duplication of external jugular vein forming a Venous Ring around Supraclavicular Nerve: A Case Report. Journal of Clinical and Diagnostic Research. 2011; 5(4): 859-861.
 4. Bergman RA, Afifi AK, Miyauchi R. Illustrated encyclopedia of human anatomic variation: opus II: cardiovascular system: veins: Head, neck and thorax. <http://www.anatomyatlases.org/AnatomicVariants/Cardiovascular/Text/Veins/JugularExternal.htm>
 5. Standing S, Harold E, Jeremiah CH. Development of the face and neck. In: Standing S. Grays anatomy: The anatomical basis of clinical practice. 39th edition. Edinburgh, London: Elsevier Churchill Livingstone; Edinburgh, London. 2005. pp. 609-18
 6. Nayak S, Soumya KV. Abnormal formation and communication of external jugular vein. *International Journal of Anatomical Variations*. 2008; 1:15-18.
 7. Choudhary S, Sharma AK, Singh H. Undivided retromandibular vein continuing as external jugular vein with facial vein draining into it: an anatomical variation. *JK Science*. 2010; 12(4): 203-4.
 8. Bertha A, Suganthy R. Anatomical Variations in Termination of Common facial Vein. *Journal of Clinical and Diagnostic Research*. 2011; 5(1): 24-7.
 9. Hamilton, Boyd, Mossman. Human Embryology. 4th edition. Heffer Cambridge. 1972; pp.261.
 10. Dhivya S, Chitra S. External jugular vein communicating with internal jugular vein - a case report. *Journal of Medical and Dental Sciences*. 2013; 2(30): 5512-5516.
 11. Patnaik VVG, Singla RK, Bala S. Surgical Incisions, their Anatomical basis. Part (1) Head and Neck. *J Anat Soc Ind*. 2000; 49(1): 69-77.
 12. Comert E, Comert A. The external jugular vein duplication. *Journal of Craniofacial Surgery*. 2009; 20(6): 2173-4.
 13. Gupta V, Tuli A, Choudhry R, Agarwal S, Mangal A. The facial vein draining into the external jugular vein in humans: its variation, phylogenetic retention and clinical relevance. *Surgical and Radiological Anatomy*. 2003; 25(1): 36-41.
 14. Baumgartner I, Bollinger A. Diagnostic importance of the jugular veins. *Vasa*. 1991; 20(1): 3-9.
 15. Nayak BS. Surgically important variations of the jugular veins. *Clinical Anatomy*. 2006; 19(6): 544-6.

How to cite this article: Suresh BS, Shivaleela C, Kumar GV. Unilateral duplication of the external jugular vein: a case report with embryological significance and clinical implications. *Int J Health Sci Res*. 2014;4(9):393-396.
