



Case Report

Sacroccocygeal Chordoma: A Case Report in a 52 Year Old Female

V. Raje^{1*}, Vaishali Raje^{1**}, Shruti Panicker², Madhavendra Kabra², Sangeeta Biradar²

¹Associate Professor, ^{*}Department of Neurosurgery, ^{**}Department of Community Medicine,

²Residents, Department of General Surgery.

Krishna Institute of Medical Sciences and Deemed University, Karad, Maharashtra, India.

Corresponding Author: Shruti Panicker

Received: 18/07/2014

Revised: 13/08/2014

Accepted: 19/08/2014

ABSTRACT

Introduction: Chordoma is a rare slow- growing neoplasm, thought to arise from the cellular remnants of the notochord.

Presentation of case: A 52 year old female presented with a swelling in the sacroccocygeal region since last 6 months. MRI sacral region showed well defined, multilobulated, solid lesion having smooth regular margin surrounding the sacrum and coccyx. The lesion is iso to hypointense on T1W1 and hyperintense on T2.

Discussion: Sacroccocygeal chordoma is a rare primary malignant tumour, and it is the most common primary sacral tumor. They are usually diagnosed late in the course of the diseases and can become quite large.

Management includes surgical resection of the tumour followed by radiotherapy. Despite these therapeutic modalities, recurrence is common.

Conclusion: The aim of presenting this case is its rarity. Surgical excision along with radiotherapy is the treatment of choice. Pre-operative imaging with MRI is essential to plan the most appropriate surgical approach.

Keywords: Sacroccocygeal chordoma, teratoma

INTRODUCTION

Chordoma is a rare malignant bone tumor that arises from ectopic rest cells of notochord. Restricted to the axial skeleton, it has a predilection for the sacrum (50%), sphenoid and occipital bones in the region of the clivus (35%), in the true vertebrae above the sacrum (15%).^[1,2] In addition there have been reports of ectopic chordomas arising outside the skeletal axis, within the maxilla, sinuses, larynx and other soft tissues. Although chordomas are tumors of bone, they have also been reported at extra osseus

sites, pre-dominantly in the parapharyngeal area. Sacral chordoma occurs almost twice as frequently in men compared with women and is uncommon in individuals younger than 40 years of age.^[3]

Chordomas are typically slow growing but locally aggressive. Significant extra compartmental growth is often seen by the time of diagnosis. Most sacral chordomas present with anterior extension into the pelvis.^[4,5] The tumor often displaces but does not invade the rectum, because the tough periosteum and presacral

fascia resist the transgression of disease. Metastasis is usually a late event. [6]

The relative rarity and slow growth of these tumors account for why most large clinical studies over many years have been based on cases collected involving variable treatments. Earlier studies [6] reported very high local recurrence rates for sacral chordoma treated with traditional surgical debulking and radiotherapy. These patients were condemned to progressive deterioration and pain from continued tumor growth, deteriorating neurological function, pressure sores, and infection. Local recurrence of sacral chordoma is associated with a 21-fold increased risk of tumor-related death.

Evidence suggestive of its origin is the location of the tumour (along the neuraxis), the similar immunohistochemical staining patterns, and the demonstration that notochord cells are left behind in the sacrococcygeal region when the remainder of the notochord regresses during the fetal life.

CASE REPORT

Patient is a 52 year old female presented with a swelling in the sacral region since 6 months. Clinical examination showed a well nourished, vitally stable female. Local examination revealed a solid swelling in the sacral region, extending over the gluteal region, extending over the bilateral gluteal region measuring 10×7 cm. on digital rectal examination mass was palpable. Anal tone was normal. Perianal sensations were normal, no complains of urinary incontinence.

MRI of the lumbosacral spine showed well defined multilobulated, solid lesion, having smooth regular margins and circumferentially surrounding the sacrococcyx bone. Intra operatively, under GA patient was put in prone position, an inverted U-shaped flap was elevated to expose the sacrococcygeal region, a large,

bulky, lobulated, grayish- white, relatively avascular tumor seen. All superficial part excised. Coccyx was dissected down and excised. Partial lower sacrectomy done. Tumour anterior to the sacrum excised appeared to be of different characteristic. It was granular, and highly vascular. Incision was closed on negative suction drain.

Microscopically the tumours are characterized by a distinct, lobular architecture that is formed by the physaliphorous ((soap bubble) cells with ample vacuolated cytoplasm as well as by the presence of signet ring type cells. Broad spectrum antibiotics were given and care was taken to keep the dressing sterile. Careful monitoring of vitals was done. Post operative period was uneventful. Patient was discharged after 20 days and followed up in radiotherapy outpatient department for radiotherapy.

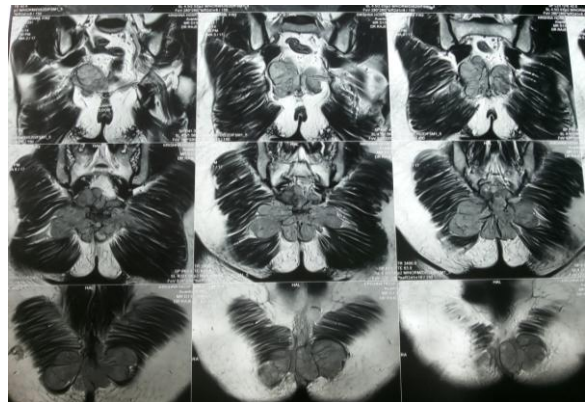

Fig 1 (MRI coronal section sacrococcygeal region)

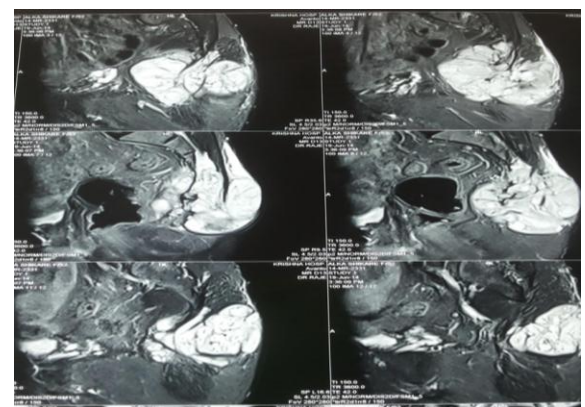


Fig 2 (MRI sagittal section sacrococcygeal region)

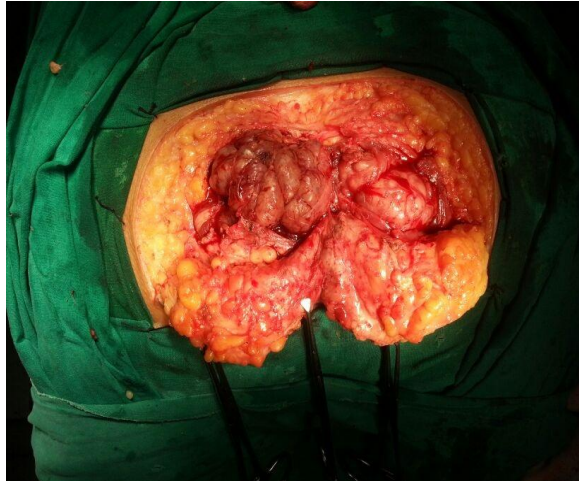


Fig 3 (Intra-operative gross specimen of the tumor)

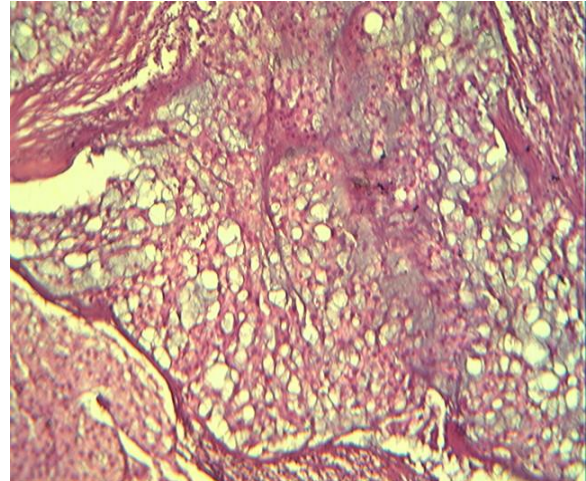


Fig 4 (Microscopic appearance of the excised tumour)

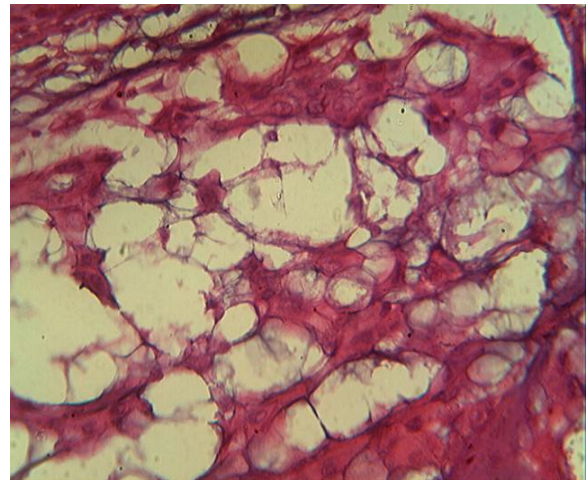
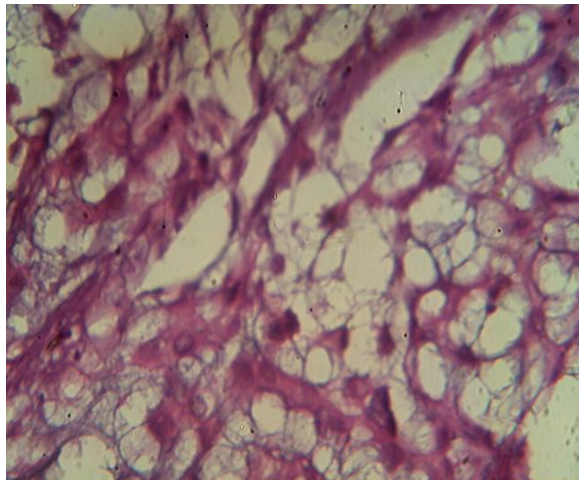


Fig. 5 & 6 Physaliphorous cells (soap bubble appearance)

DISCUSSION

Sacrococcygeal chordomas are malignant low-grade tumours, arising from remnants of the notochord. [3,7]

Because chordomas can develop insidiously, there can be a considerable time-lapse between the onset of symptoms and diagnosis

The conventional radiographic findings in sacrococcygeal chordomas are the central location of the tumour, its destruction of several segments of the sacrum and its appearance as an anterior soft-tissue mass that occasionally contains small calcifications. [8] MRI is the best imaging method for evaluating the extension of the tumour into soft tissue.

The reported rates of metastasis occurrence with chordomas vary considerably in the literature, from 5% to 70%. [3,7-11]

For the surgical treatment of chordomas, methods include the combined abdominal and trans-sacral approach [5] and the posterior approach. [13, 14] For proximal sacral lesions, the combined extended ilioinguinal and posterior approach is also useful. [15] The posterior approach is satisfactory for lesions at the third sacral segment or further caudal. Combined anterior and posterior exposure must be used for lesions that are located more cranially. [6,8,16-19]

The extent of surgical resection plays a major role in determining the length of the disease-free interval. [12,20] In patients who received a wide surgical excision, the recurrence rate was 17%, while in patients who received intralesional or marginal resection the recurrence rate was 81%. [9] It has been emphasized that if gluteal invasion is present, the risk of recurrence is higher, and therefore a wide posterior surgical margin is important. [2]

The risk of postoperative neurological deficits is related to the number of sacrificed nerve roots. [8] The loss of the S₄ and S₅ nerves is not associated with any significant urinary or bowel problems. [9] All of these potential consequences must be discussed with patients before surgery. Transrectal biopsy is not recommended in chordomas due to the risk of the rectal wall and presacral fascia becoming contaminated with tumour cells. If transrectal biopsy is performed, then the rectum must be resected during chordoma surgery. [7]

For long-term control of sacral chordomas, the superiority of wide resection over subtotal or even marginal intralesional resection is well known. For the patients in our series, wide resection was not possible because the tumours were very big, invading neighbouring tissues, and most patients wanted their sacral nerve roots to be retained; therefore, their disease could not be eradicated. Chordoma is a locally aggressive but slow-growing tumour, so early diagnosis and wide resection increases the chances of long-term control.

CONCLUSION

The aim of presenting this case is its rarity. Complete surgical excision along with radiotherapy and chemotherapy, increases the chances of extended survival in patients of sacrococcygeal chordoma.

Preoperative imaging with MRI is essential to plan the most appropriate surgical approach.

Conflict of interest: None

Funding: None

Ethical approval: Written informed consent was obtained from the patient for the publication of this case report and accompanying images.

ACKNOWLEDGEMENT

We are grateful to our Medical Director, for allowing us to present this case report.

REFERENCES

1. Campanacci ML. Bone and soft tissue tumors. 2. Berlin Heidelberg New York: Springer; 1990. pp. 639–651.
2. York JE, Kaczaraj A, Abi-Said D, Fuller GN, Skibber JM, Janjan NA, Gokaslan ZL. Sacral chordoma: 40-year experience at a major cancer center. *Neurosurgery*. 1999;44:74–79. doi: 10.1097/00006123-199901000-00041.
3. Azzarelli A, Quagliuolo V, Cerasoli S, Zucali R, Bignami P, Mazzaferro V, Dossena G, Gennari L. Chordoma: natural history and treatment results in 33 cases. *J Surg Oncol*. 1988;37:185–191.
4. Campanacci ML. Bone and soft tissue tumors. 2. Berlin Heidelberg New York: Springer; 1990. pp. 639–651.
5. Localio SA, Francis KC, Rossano PG. Abdominosacral resection of sacrococcygeal chordoma. *Ann Surg*. 1967;166:394–402. doi: 10.1097/0000658-196709000-00007.
6. Huth JF, Dawson EG, Eilber FR. Abdominosacral resection for malignant tumors of the sacrum. *Am J Surg*. 1984; 148:157–161. doi: 10.1016/0002-9610(84)90304-0.
7. Mindell ER. Chordoma. *J Bone Surg Am*. 1981;63:501–505.
8. Samson IR, Springfield DS, Suit HD, Mankin HJ. Operative treatment of sacrococcygeal chordoma. A review of

- twenty-one cases. *J Bone Joint Surg Am.* 1993;75:1476–1484. [P]
9. Bergh P, Kindblom LG, Gutenberg B, Remotti F, Ryd W, Meis-Kindblom JM. Prognostic factors in chordoma of the sacrum and mobile spine: a study of 39 patients. *Cancer.* 2000;88:2122–2134. doi: 10.1002/(SICI)1097-0142(20000501)88:9<2122::AID-CNCR19>3.0.CO;2-1.
 10. Huvos AG. Bone tumors. Diagnosis, treatment and prognosis. 2. Philadelphia: Saunders; 1991. pp. 599–624.
 11. Huvos AG. Bone tumors. Diagnosis, treatment and prognosis. 2. Philadelphia: Saunders; 1991. pp. 599–624.
 12. York JE, Kaczaraj A, Abi-Said D, Fuller GN, Skibber JM, Janjan NA, Gokaslan ZL. Sacral chordoma: 40-year experience at a major cancer center. *Neurosurgery.* 1999;44:74–79. doi: 10.1097/00006123-199901000-00041.
 13. Mindell ER. Chordoma. *J Bone Surg Am.* 1981;63:501–505.
 14. Wuisman P, Harle A, Matthiass HH, Roessner A, Erlemann R, Reiser M. Two-stage therapy in the treatment of sacral tumors. *Arch Orthop Trauma Surg.* 1989;108:255–260. doi: 10.1007/BF00936213.
 15. Simpson AH, Porter A, Davis A, Griffin A, McLeod RS, Bell RS. Cephalad sacral resection with a combined extended ilioinguinal and posterior approach. *J Bone Joint Surg Am.* 1995;77:405–411.
 16. Saxton JP. Chordoma. *Int J Radiat Oncol Biol Phys.* 1981;77:913–915.
 17. Stener B, Gutenberg B. High amputation of the sacrum for extirpation of tumors. Principles and technique. *Spine.* 1978;3:351–366. doi: 10.1097/00007632-197812000-00009.
 18. Sung HW, Shu WP, Wang HM, Yuai SY, Tsai YB. Surgical treatment of primary tumors of the sacrum. *Clin Orthop.* 1987;215:91–98.
 19. York JE, Kaczaraj A, Abi-Said D, Fuller GN, Skibber JM, Janjan NA, Gokaslan ZL. Sacral chordoma: 40-year experience at a major cancer center. *Neurosurgery.* 1999;44:74–79. doi: 10.1097/00006123-199901000-00041.
 20. Rich TA, Schiller A, Suit HD, Mankin HJ. Clinical and pathologic review of 48 cases of chordoma. *Cancer.* 1985;56:182–187. doi: 10.1002/1097-0142(19850701)56:1<182::AID-CNCR2820560131>3.0.CO;2-J.

How to cite this article: Raje V, Raje V, Panicker S et. al. Sacroccocygeal chordoma: a case report in a 52 year old female. *Int J Health Sci Res.* 2014;4(9):376-380.
