



Original Research Article

## Morphometric Evaluation of Anterior Fontanelle: A Fetal Cadaveric Study

Vinodhini Periyasamy, Mamatha H, Suhani, Antony Sylvan D'souza, Prasanna, Keerthana Prasad

Department of Anatomy, Kasturba Medical College, Manipal - 576104.

Corresponding Author: Vinodhini Periyasamy

Received: 11/06/2014

Revised: 04/08/2014

Accepted: 12/08/2014

### ABSTRACT

**Background:** The frontal bone is ossified from two primary centers, each half of the bone ossifies from a single center which appears between 6 and 7 weeks of the fetal life and is situated above the supra orbital margin. At birth the frontal bone is composed of two pieces, separated by the inter frontal suture and also separated from the parietal bones by the diamond-shaped, membrane filled anterior fontanelle that persists until 18 months after birth, which allows development and growth of the brain and the skull.

**Aim:** The study was designed to measure the dimensions & extent of anterior fontanelle in fetal skulls in order to assess the dimensions of the fontanelle and its related clinical significance.

**Materials & Methods:** The anterior fontanelle of 25 fetal skulls was studied, in the Department of Anatomy, Kasturba Medical College, and Manipal. The mean and standard deviation of the morphometric measures were tabulated.

**Results:** In our study, the measurements of the antero posterior & transverse chord length measurements were done both in dry skull & pericranium of the scalp. The mean and standard deviations are determined. 25 dry skulls were placed in the exact environment considering the same distance, light source & angulation and photographed. The photographs were correlated with Digital image analyzer - TISSUE QUANT. The mean total surface area was calculated.

**Conclusion:** Assessment of the tension and size of the anterior fontanelle is important in the routine examination of newborn infants when considering, respectively, possible disturbances of intracranial pressure and disorders of skeletal development. The knowledge of the normal variation in anterior fontanelle size may be of help in the early diagnosis of congenital hypothyroidism or provide a clue to other disorders of skeletal development.

**Keywords:** Anterior Fontanelle, hydrocephaly, hypothyroidism, tissue quant, Intracranial pressure

### INTRODUCTION

Anterior fontanelles are unpaired, unossified areas located in the vault of the fetal skull, allowing the prolific growth of the skull. It is situated at the junction of sagittal, coronal & frontal sutures, corresponding to bregma. Beneath it lays the superior sagittal sinus in the fetal skull,

together with the temporary interfrontal suture, they form the boundaries of a diamond-shaped the anterior fontanelle and hence rhomboid in shape. <sup>(1)</sup>

Fontanelles are the fibrous, membrane-covered gaps formed when more than two cranial bones are juxtaposed, as opposed to sutures. Examination of a

newborn's fontanel offers the physician a window into the infant's developing brain and general state of health. <sup>(1,2)</sup>

The normal fontanelle varies largely in shape and time of closure. The flat bones of the skull develop as part of the membranous neuro cranium. During fetal and postnatal life, the membranous bones enlarge by resorption centrally and by apposition of new layers at the edges of the sutures. <sup>(3,4)</sup>

The word "Anterior fontanelle" means little fountain or spring. They persists from 18 months till 2 years after birth, allowing the development and growth of the brain and the skull. The eventual closure of the fontanelle presumably occurs by transformation of fibroblasts into osteoblasts by the end of 2 years. <sup>(4)</sup>

**Aim**

The study was designed to measure the dimensions & extent of anterior fontanelle in fetal skulls in order to assess the dimensions of the fontanelle and its related clinical significance.

**MATERIALS & MATHEODS**

The anterior fontanelle of 25 fetal dry skulls & pericranium of the scalp in the spontaneously aborted fetuses, with no detectable congenital malformations or maternal history of risky pregnancy were studied, in the Department of Anatomy, Kasturba Medical College, and Manipal.

Calculations of the anteroposterior and transverse chord length dimensions were measured. The antero-posterior chord length is the distance between the points respectively the "antermost" and the "posterior-most" extremities of the membranous gap along the axis delimiting the contact between the right and the left halves of the skull. The illustration is given in Fig. 1, 2. The transverse chord length is also measured manually using vernier

calipers along the skull surface as in fig1a, 2a. The mean and standard deviation of the morphometric measures of anterior fontanelle were tabulated.

Assessment of total surface area was done using digital morphometric image analysis (TISSUE QUANT). It is illustrated in fig.3.

**RESULTS**

Table 1 depicts the measurements done in the dry skull.

Table 2 depicts the measurements done in the pericranium of fetal scalp:

**DIGITAL MORPHOMETRICS:**

All photographs were correlated with Digital image analyzer - TISSUE QUANT. The mean total surface area was calculated. TOTAL SUFACE AREA = 5047.3 (no. of pixels)

Figure 1: Measurements of anterior-posterior and transverse chord length estimated in the dry skull using Vernier Calipers

Figure 2: Measurements of anterior-posterior and transverse chord length estimated in the pericranium of fetal scalp using Vernier Calipers

Figure 3: Digital Morphometrics: Comparison of the Original (left) and numerical model (right).

TABLE 1: MEASUREMENTS-DRY SKULL:

	MEAN VALUE	STANDARD DEVIATION
ANTERIO-POSTERIOR CHORD	41.6mm	5.55.
TRANSVERSE CHORD	34.3mm	3.80

TABLE 2: MEASUREMENTS-PERICRANIUM OF FETAL SCALP:

	MEAN VALUE	STANDARD DEVIATION
ANTERIO-POSTERIOR CHORD	39.4mm	4.26
TRANSVERSE CHORD	31.2mm	3.22

## MEASUREMENTS - DRY FETAL SKULL BONES

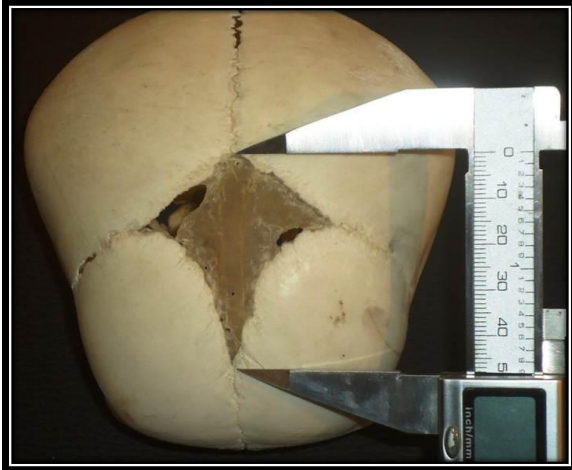

Fig 1,1a; Measurements of anterior-posterior and transverse chord length estimated using Vernier Calipers.

## MEASUREMENTS - PERICRANIUM OF THE FETAL SCALP

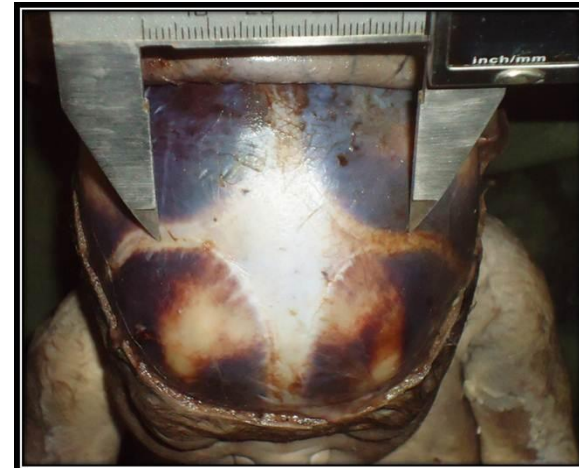
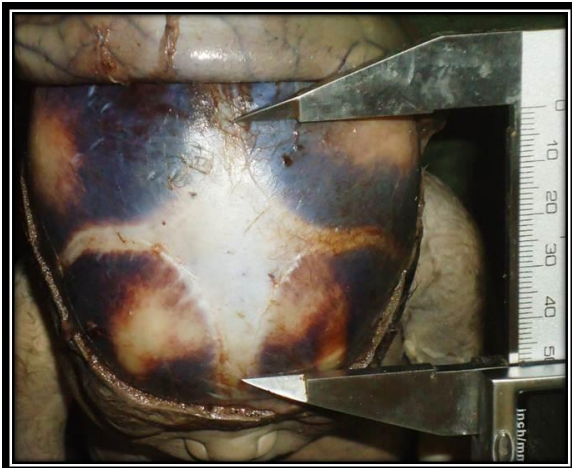

Fig 2,2a; Measurements of anterior-posterior and transverse chord length estimated using Vernier Calipers.

## DIGITAL MORPHOMETRICAL ANALYSIS

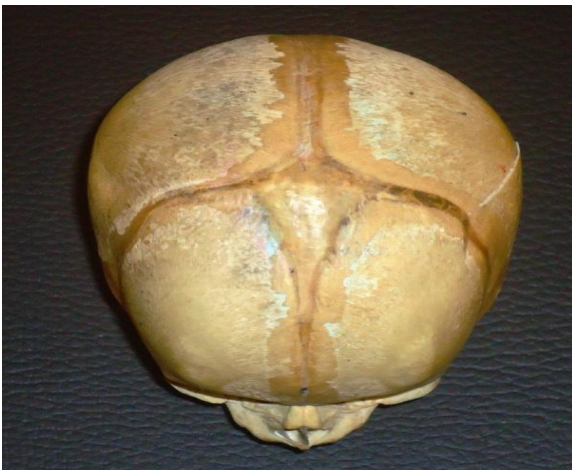

Fig 3: original (left) and numerical model (right).

## DISCUSSION

The diagnosis of an abnormal fontanel requires an understanding of the wide variation of normal. At birth, an infant has six fontanels. The anterior fontanel is the largest and most important for clinical evaluation. [1,2]

From our study the dimensions of anterior fontanelle provides valuable information regarding the alterations in the size of them during pathological situations. An unusually large or small size of fontanel may be a clue for the identification of intracranial or system disorders. The newborn's skull should be evaluated for shape, circumference, suture ridges, and size of anterior and posterior fontanels. Size is calculated by the average of the anteroposterior and transverse dimensions

Large fontanelle occurs in a number of disorders of skeletal morphogenesis such as achondroplasia, hypophosphataemia, osteogenesis imperfecta, and congenital hypothyroidism. The most common condition associated with enlarged fontanelles and delayed closure are due to increased intracranial pressure, congenital hypothyroidism, Down syndrome, Rickets etc. [3,4]

Palpation of the fontanel in the upright position may reveal a normal, slight pulsation. If the fontanels are closed and intracranial pressure has increased, percussion produces a "cracked pot" sound (dull, lacking resonance), known as Macewen's sign. Bridging of bone over a suture, an indistinct suture, or sclerosis along the suture margins indicates fusion of the frontal bones. If the anterior fontanel is open, ultrasonography is useful to evaluate ventricular dilatation. A computed tomographic (CT) scan can detect a fused suture, dilated ventricles, enlarged subarachnoid space, brain size, or an intracranial or extracranial mass. Magnetic resonance imaging (MRI) can

detect cortical and white-matter abnormalities, such as degenerative diseases, and document the extent of calvarial masses. [5,6]

Disorders associated with increased intracranial pressure can cause a bulging anterior fontanel. The most common disorders are meningitis, encephalitis, hydrocephalus, hypoxic-ischemic injury, trauma, and intracranial hemorrhage. The primary cause of a sunken fontanel is usually the dehydration. [7,8]

From the lateral to the medial edges, the bony plates gave way to islands of bone and then to aggregates of plump fibroblasts surrounding pink osteoid like material. The eventual closure of the fontanelle presumably occurs by transformation of fibroblasts into osteoblasts. These form bony islands usually joins to the main skull plate. [9-11]

Digital anthropology provides powerful tools for investigations and "revisiting" existing studies and theories on human evolution and in particular on growth and development processes. The general framework of the current research is the application of the modern medical imaging techniques to the geometric morphometric. In a more precise way, we are interested in retrieval of geometric computer models of anatomical shapes for some collection of specimens and the simulation of the geometric morphometric analysis through digital image processing. [12,13]

A new research field, we call digital morphometric, could emerge and make possible to perform morphological studies as analysis on different types of supports such as collections of specimens, real or synthetic objects or computer geometric models, for different types of shape features as distances, angles, outlines, landmarks, surface or volume features, according to different types of metrics as Euclidean. [13,14]

Morphometric data measurements are performed according to a chosen protocol using chosen metrics and applied on chosen shape features of the computer geometric model. The correlation with age is not so high; the closure of the anterior fontanelle was used, along with the feature of the inner ear, to estimate the age of death of the validation of the object reconstruction is determined on the ability to perform reliable morphometric measures. [14,15]

The present study contributes to both digital image processing and digital anthropology. The diagnosis of an abnormally large or small anterior fontanelle at birth presumes the knowledge of normal variations in its size, possible variations in size of the anterior fontanelle in relation to gestational age and intrauterine growth. In the absence of raised intracranial pressure the most important reason for assessing anterior fontanelle size in the neonate is the early diagnosis of congenital hypothyroidism, since its early detection and treatment has an important bearing on ultimate mental progress. [16-18]

The closure of the fontanelle must be largely dependent on the growth of the bones bordering on it. The anterior fontanelle closed earlier in the male than in the female. This distinguishes fontanelle closure from skeletal maturation in which the female lead is well known. [19, 20]

It is suggested that non-invasive techniques for measuring intracranial pressure should be suitable for use in the unsexed infant and should be capable of measuring pressure continuously. The tension of a membrane containing a fluid is determined by the pressure of the contained fluid and the elasticity of the membrane. [21,22]

Use of aplanation transducer, APT-16 transducer (Hewlett Packard) uses a modification of the aplanation principle and was evaluated for use as a 'fontanometer'.

The results indicate that the aplanation principle as used by the Hewlett Packard transducer maybe used to measure intracranial pressure without puncture in infants. [23-25]

An elaborate physical examination helps the physician determine which imaging modality, such as plain films, ultrasonography, computed tomographic scan, or magnetic resonance imaging, to use for diagnosis, for interpretation of the root cause to provide the earliest interventional therapy.

## CONCLUSION

The knowledge of size of anterior fontanelle is useful in evaluating the abnormal situations of failure of calvarial and brain growth. Assessment of the tension and size of the anterior fontanelle is important in the routine examination of newborn infants when considering, possible disturbances of intracranial pressure and disorders of skeletal development. The diagnosis of an abnormally large or small anterior fontanelle at birth, possess an alarming threat to the clinicians for interventional therapies.

Knowledge of the normal variation in anterior fontanelle size helps in the early diagnosis of congenital hypothyroidism or provides a significant factor for disorders of skeletal development. A simple method is described for measuring the area of the anterior fontanelle at birth. Normal values in preterm and term infants suggest enlargement of the fontanelle with gestational age.

Considerable skeletal growth retardation undoubtedly occurs in many small-for-dates babies, so that it is likely that large fontanelle size in these infants is a further manifestation of intrauterine growth retardation suggesting of a delay in osseous maturation of the skull bones.

## ACKNOWLEDGEMENTS

Our sincere thanks to Mrs. Keerthana Prasad, Assistant Professor, Manipal center for information sciences, Manipal for her help and the support for our project.

## REFERENCES

1. Susan Standing. Gray's Anatomy The anatomical basis of clinical practice, 40th Edition, Spain. Churchill Livingstone; Elsevier, 2008, 416-418..
2. Richard S Snell, Clinical Neuro Anatomy, 7th edition, Wolter Kluwer (India) pvt ltd, New Delhi, 2010, 46-467.
3. Adeyemo AA, Omotade OO. Variation in fontanelle size with gestational age. *Early Hum Dev* 1999;54: 207-14.
4. Joseph Kiesler, The Abnormal Fontanel, *American family physician* 2547 June 15, 2003, no 12, vol 67, 2540-2552..
5. M Sundaresan, M Wright, Anatomy and development of the fontanelle. August 20, 2012. 386-389.
6. Sarla Mattur, Ram Kumar et al, Anterior fontanel size, *Indian pediatrius* Vol 31-Feb 1994.
7. Sadler TW, Langman J. *Langman's Medical embryology*. 8th ed. Philadelphia: Lippincott Williams & Wilkins, 2000, 173-175.
8. Duc G, Largo RH. Anterior fontanel: size and closure in term and preterm infants. *Pediatrics* 1986; 78: 904-8.
9. Popich GA, Smith DW. Fontanels: Range of normal size. *J Pediatr* 1972, 80:749-752
10. Indira Bai K, Subrahmanyam MVG. Fontanels: Range of normal size. *Indian Pediatr* 1973, 10: 667-670.
11. Martinez-lage JF, Torroba A., Cranial fasciitis of the Anterior fontanel. *Childs Nerv Syst*. 1997;13: 626-8.
12. Green M. *Pediatric Diagnosis: Interpretation of symptoms and signs in children and adolescents*. 6th ed. Philadelphia: Saunders, 1998.
13. Mackenzie A, Shann F, Barnes G. Clinical signs of dehydration in children. *Lancet* 1989;2:1529-30.
14. Desbarats, P, Gueorguieva, al, Digital Anthropology for effective retrieval of the Anterior fontanelle,. *Image Anal Stereol - Sep* 2009, volume: 1-5.
15. Hildebrandt K, Polthier K, Wardetzky M (2005). On the convergence of metric and geometric properties of polyhedral surfaces. In: *Research Report* 05-24.
16. Mehta A, Wright BM, Short C. Clinical fontanometry in the newborn. *Lancet* 1988:754-6.
17. L. Crome, Peter E. S, (Hydrocephaly). *Sept* 30, 1957. 235-246.
18. Smith DW, Popich GA. Large fontanels in congenital hypothyroidism: A potential clue towards its recognition. *J Pediatr* 1972, 80: 753.
19. Scammon RE. The geometric relationships of the anterior fontanelle in infancy. *Anat Rec* 1930;46: 349-63.
20. Kirkpatrick, H Engleman, Symptoms and signs of progressive hydrocephalus, Department of Neurology, Royal Hospital for Sick Children, Edinburgh, 1989, 64, 124-128.
21. Robinson DC, Hall R, Munro DS. Grave's disease an unusual complication: Raised intracranial pressure due to premature fusion of skull sutures. *Arch Dis Child* 1962, 44: 252.

22. Walia bns, Bhalla AK. Norms of anterior fontanel size of Punjabi children. Indian Pediatr 1985, 22: 303-306.
23. Srugo I, Berger A. Anterior fontanel size in healthy Israeli newborn infants. Isr J Med Sri 1987, 23: 1137-1139.
24. Popich, G. A.,Smith, D. W. Fontanels: Range of normal size. Journal of Pediatrics, 1972. 80, 749.
25. S. R. Wealthall, Methods of measuring intracranial pressure via the fontanelle without puncture, Journal of Neurology, Neurosurgery, and Psychiatry, 1974, 37, 88-96.

How to cite this article: Periyasamy V, Mamatha H, Suhani et. al. Morphometric evaluation of anterior fontanelle a fetal cadaveric study. Int J Health Sci Res. 2014;4(9):107-113.

\*\*\*\*\*

**International Journal of Health Sciences & Research (IJHSR)**

**Publish your work in this journal**

The International Journal of Health Sciences & Research is a multidisciplinary indexed open access double-blind peer-reviewed international journal that publishes original research articles from all areas of health sciences and allied branches. This monthly journal is characterised by rapid publication of reviews, original research and case reports across all the fields of health sciences. The details of journal are available on its official website ([www.ijhsr.org](http://www.ijhsr.org)).

Submit your manuscript by email: [editor.ijhsr@gmail.com](mailto:editor.ijhsr@gmail.com) OR [editor.ijhsr@yahoo.com](mailto:editor.ijhsr@yahoo.com)