



Case Report

A Mosaic Turner with Dicentric X Chromosome Diagnosed in Adulthood

Manali Sinharay¹, Arindam Karmakar²

¹Tutor, Department of Biochemistry, KPC Medical College & Hospital, Kolkata, West Bengal

²Assistant Professor, Department of Pathology, Malda Medical College, Malda, West Bengal.

Corresponding Author: Manali Sinharay

Received: 11/06/2014

Revised: 04/07/2014

Accepted: 07/07/2014

ABSTRACT

Turner Syndrome is the result of complete absence or structural abnormality of the second sex chromosome with or without cell line mosaicism in a phenotypic female with a constellation of clinical manifestations which often correlate with the causal chromosomal abnormality. Here we report a case of mosaic turner syndrome with dicentric X chromosome diagnosed at the age of twenty, the presenting feature being delayed menarche and secondary amenorrhea, hypothyroidism, hypercholesterolemia and seronegative juvenile rheumatoid arthritis. This study attempts to intrigue further inquiries regarding association between the particular set of phenotypic manifestations and chromosomal abnormalities found in this patient as well as the need for a better diagnostic algorithm of Turner syndrome for early management.

Key words: Turner syndrome, seronegative juvenile rheumatoid arthritis.

INTRODUCTION

Turner's syndrome (TS), named after Henry Turner, is the result of complete or partial absence of the second sex chromosome with or without cell line mosaicism in a phenotypic female, associated with characteristic clinical features, the most consistent being short stature and gonadal dysgenesis. ⁽¹⁾ The first cases described were with the 'classical' karyotype 45, X. In more recent series the classical karyotype only accounts for 50% of cases; the remaining cases comprise karyotypes with an isochromosome of X [20%], mosaic karyotypes [10%], and rest karyotypes with X chromosome deletions or

rings, or the presence of an entire or part of Y chromosome. ⁽²⁾

CASE REPORT

A twenty year old girl presented with short stature, delayed menarche, irregular menstruation leading to amenorrhea for last six months. She complained of swelling of whole body with normal urine output and joint pain specially wrist and ankle joint with fever six months back. She was a known case of hypothyroidism and was on thyroxin therapy since thirteen years of age.

She was born of non consanguineous marriage and was delivered at full term. There was no history of any obstetrical complications or medical illness of her

mother. She was adequately vaccinated; breast fed and had attained the developmental milestones well within time. Despite being reared in a well-to-do family, she started lagging behind her peers in height after ten years of age. She never developed axillary or pubic hair and had underdeveloped breasts. A delayed menarche was followed by irregular menses which finally ceased six months back. She had normal schooling and is now doing her bachelor's in college. Past medical history was negative for mumps, tuberculosis or any major systemic illness. Her brother had normal physical and mental development.



Figure 1: Broad chest and slight webbing of neck.



Figure 2: Cubitus valgus.

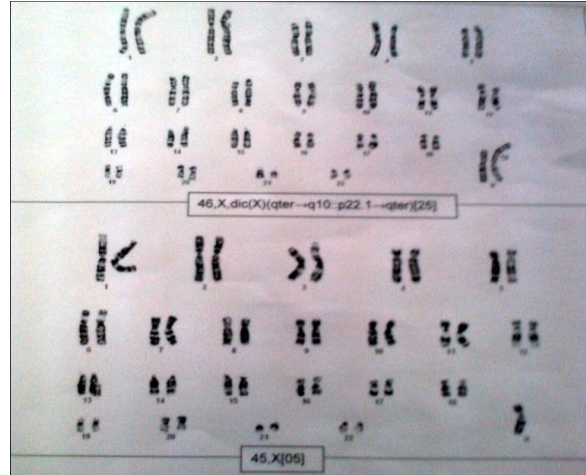


Figure 3: Karyotype revealing mosaic Turner with dicentric X chromosome.

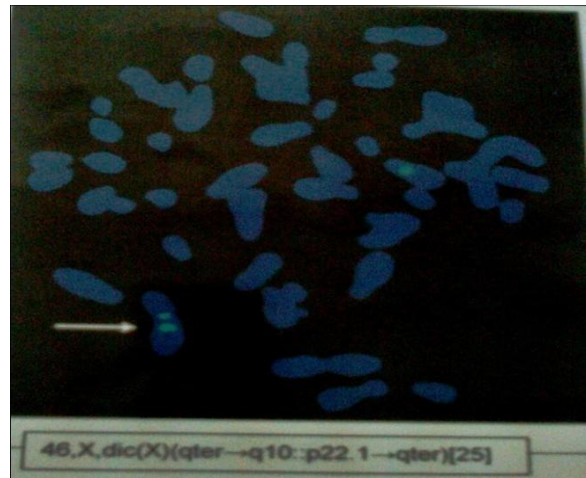


Figure 4: FISH revealing the dicentric X chromosome

General and systemic examination revealed

- She had short stature (height of 143 cms- below 5th percentile)
- Broad chest (Figure 1) with widely spaced nipple.
- Slightly webbed neck. (Figure 1)
- Poorly developed secondary sexual characteristics (absent pubic and axillary hair)
- Cubitus valgus (Figure 2)
- No gynaecologic abnormality.

Routine laboratory tests revealed anaemia (Hb-10.5g/dl), increased cholesterol (231mg/dl) and decreased Vitamin D levels (23.77ng/ml). Other tests like Blood Glucose, Liver function tests, renal function

tests, serum calcium, and serum parathyroid hormone were all normal. Echocardiographic findings were normal.

Endocrinal investigations were done, which revealed increased Serum FSH (>100mIU/ml), increased Serum LH (20.52mIU/ml), increased Serum Prolactin (23.42ng/ml) and normal Serum TSH levels (1.5 µIU/ml) due to thyroxin (100 mcg) therapy. Ultrasonography of lower abdomen revealed rudimentary uterus with non visualization of ovaries and endometrium, confirming pure gonadal dysgenesis. Kidneys were within normal limits. Karyotypic analysis of 30 cells harvested from peripheral blood revealed 2 cell lines-

- 25 cells revealed a total of 44 autosomes and 2 sex chromosomes with presence of dicentric X chromosome. The dicentric X chromosome was confirmed by Fluorescence in situ Hybridization using CEP 18/X/Y probe. (Figure 3)
- 5 cells revealed a total of 44 autosomes and one chromosome X.

So, karyotype suggested a mosaic turner syndrome variant- 46, Xdic (X) (qter→q10:p22.1→qter) [25] / 45, X [05]. (Figure 4)

Investigation for polyarthritis revealed negative serum Rheumatoid arthritis and Positive Anti Nuclear Antibody (index value=2.5).

USG power Doppler of wrists and ankles showed synovial proliferation on 2nd and 5th metacarpophalangeal joints, intercarpal joints, 1st metatarsophalangeal joint, intertarsal joints. Soft tissue edema with peritendinous swelling was noted on dorsal aspect of bilateral wrist and ankle joints.

At present, she is being treated with Estrogen (0.625mg) daily for hypogonadism, Prednisolone (5mg) daily for polyarthritis, Vitamin D & Calcium supplementation for proper bone

mineralization to prevent osteoporosis. Thyroxin therapy (100mcg) is being continued and the patient now comes for regular follow ups.

DISCUSSION

To diagnose suspected Turner syndrome (TS), 30-cell karyotype is usually done as recommended by the American College of Medical Genetics which identifies at least 10% mosaicism with 95% confidence. ⁽³⁾ It may be supplemented by counting of additional metaphase or Fluorescence in situ Hybridization (FISH) if there is a strong suspicion of undetected mosaicism. In rare instances karyotyping of other tissue samples, such as skin fibroblasts, may be necessary.

The phenotypic characteristics depend on the type of cytogenetic picture in the Turner variant. Turner mosaics usually have a less severe phenotype and up to 40% enter puberty spontaneously before developing gonadal failure. ⁽⁴⁾ Women with 45X/46, XY mosaicism have an increased risk of developing gonadoblastoma. Isochromosome Xq is the most common structural abnormality and is associated with autoimmune disorders and deafness. ⁽⁵⁾ Women with the ring X chromosome are more likely to have psychological abnormalities. However, any close association of any particular phenotypic feature with TS due to dicentric X chromosome is not mentioned in any text.

Affected individuals have a broad but variable spectrum of physical and functional alterations at any age-lymphedema of the hands or feet; nuchal folds; short stature with growth velocity less than the 10th percentile for age; characteristic facies with low-set ears, small mandible, high arched palate, low posterior hairline; distinctive skeletal abnormalities resulting in scoliosis, broad chest with widely spaced nipple, short webbed neck,

cubitus valgus, short fourth metacarpal and markedly elevated levels of FSH. Genes responsible for short stature have been localized to the distal part of short arm of the X (Xp11–22) and Y (Yp11). Mutations in this gene known as SHOX (short stature homeobox-containing gene), may also be responsible for some of the skeletal abnormalities associated with TS, such as the Madelung deformity of the wrist and possibly cubitus valgus, high arched palate, and micrognathia. ⁽⁶⁾

TS may be associated with congenital cardiovascular anomalies, hypertension and ischemic heart disease. Van PL et al ⁽⁷⁾ revealed in their study that Monosomy for the X-chromosome is associated with an atherogenic lipid profile. TS females have been reported to be at an increased risk of autoimmune diseases, most notably autoimmune thyroid diseases commonly resulting in hypothyroidism and type 1 diabetes mellitus, but also inflammatory bowel diseases and juvenile rheumatoid arthritis. ⁽⁸⁾ In the present instance, we found the patient to be suffering from Seronegative Juvenile Rheumatoid arthritis, diagnosis of which has been delayed. Delayed diagnosis of juvenile rheumatoid arthritis in a girl with TS was reported by Foeldvari I, Wuesthof A. ⁽⁹⁾

Ovarian failure occurs commonly in TS. Levels of follicle-stimulating hormone (FSH) and luteinizing hormone (LH) are high in early childhood and after the time of normal onset of puberty which may increase to menopausal levels in adulthood. Ultrasonic assessment of the pelvis in females with TS reveals the majority to have streak ovaries, too small to be identified and hypoplastic uterus, prepubertal in size. The majority of women with TS require long-term oestrogen replacement therapy for induction of puberty and growth, following which they are maintained on cyclical oestrogen-progestagen therapy. Oestrogen

replacement therapy helps in the prevention of osteoporosis and in reducing risk factors for atherosclerosis.

Patients with TS need comprehensive care from a multidisciplinary team comprising of endocrinologists, gynaecologists, cardiologists, otorhinologists, ophthalmologists and gastro-enterologists. Glucose metabolism, thyroid function, bone metabolism, liver function and cardiovascular status require to be assessed at regular intervals. The diagnosis of TS may be delayed until adulthood in up to 10% of women, as in the present case. All individuals with suspected TS are desirable to have a karyotype performed in time, as recommended by Savendahl L et al ⁽¹⁰⁾ in a study as they are at increased risk for a number of medical problems which requires utmost care to increase their life expectancy.

CONCLUSION

In the present instance we have tried to depict the clinical manifestations in a mosaic turner variant with dicentric X chromosome, diagnosed at a much older age. Further elaborate study is required to find any association between the phenotypic features and this cytogenetic variant. This case also ventilates the need for a high degree of clinical suspicion and refinement of diagnostic methodology of Turner syndrome.

REFERENCES

1. Turner H. A syndrome of infantilism, congenital webbed neck, and cubitus valgus. *Endocrinology*. 1938; 23: p. 566–574.
2. Baena N, De Vigan C, Cariati E, et al. Turner syndrome: Evaluation of prenatal diagnosis in 19 European registries. *Am J Med Genet*. 2004; 129A: p. 16–20.
3. Hook E. Exclusion of chromosomal mosaicism: tables of 90%, 95% and 99% confidence limits and comments on

- use. *Am J Hum Genet.* 1977 ; 29: p. 94–97.
4. Pasquino A, Passeri F, Pucarelli I, Segni M, Municchi G. Spontaneous pubertal development in Turner's syndrome. Italian Study Group for Turner's Syndrome. *J Clin Endocrinol Metab.* 1997; 82: p. 1810–1813.
 5. Stratakis C, Rennert O. Turner syndrome: molecular and cytogenetics, dysmorphology, endocrine, and other clinical manifestations and their management. *Endocrinologist.* 1994; 4: p. 442–453.
 6. Jones M, Schiller S, Rao E, et al. The short stature homeobox gene SHOX is involved in skeletal abnormalities in Turner syndrome. *Human Molecular Genetics.* 2000; 9(5): p. 695-702.
 7. Van P, Bakalov V, Bondy C. Monosomy for the X-chromosome is associated with an atherogenic lipid profile. *J Clin Endocrinol Metab.* 2006 Aug; 91(8): p. 2867-70.
 8. Jorgensen KT, Rostgaard K, Bache I, et al. Autoimmune Diseases in Women With Turner's Syndrome. *Arthritis & Rheumatism.* 2010 March; 62(3): p. 658–666.
 9. Foeldvari I, Wuesthof A. Delayed diagnosis of juvenile rheumatoid arthritis in a girl with Turner's syndrome. *Clin Exp Rheumatol.* 1997 Nov-Dec; 15(6): p. 701-3.
 10. Savendahl L, Davenport M. Delayed diagnoses of Turner's syndrome: proposed guidelines for change. *J Pediatr.* 2000 Oct; 137(4): p. 455-9.

How to cite this article: Sinharay M, Karmakar A. A mosaic turner with dicentric x chromosome diagnosed in adulthood. *Int J Health Sci Res.* 2014;4(8):304-308.

International Journal of Health Sciences & Research (IJHSR)

Publish your work in this journal

The International Journal of Health Sciences & Research is a multidisciplinary indexed open access double-blind peer-reviewed international journal that publishes original research articles from all areas of health sciences and allied branches. This monthly journal is characterised by rapid publication of reviews, original research and case reports across all the fields of health sciences. The details of journal are available on its official website (www.ijhsr.org).

Submit your manuscript by email: editor.ijhsr@gmail.com OR editor.ijhsr@yahoo.com