



Original Research Article

Correlation between High Resolution Ultrasonography and MRI in Rotator Cuff Tear Diagnosis

Shahnawaz Bashir^{1*}, Syed Ruzina Firdose^{1*}, Younis Kamal^{1**}, Hayat Ahmad Khan^{1**}, Manjit Arora², Snobar Gul³, Nazia Hassan⁴

¹Registrar, *Dept. of Radiodiagnosis and Imaging, ** Postgraduate Dept. of Orthopaedics, GMC, Srinagar, India.

²Consultant, Department of Radiodiagnosis and Imaging, ASCOMS, Jammu, India.

³PG Scholar, Department of Anatomy, GMC, Srinagar.

⁴PGDMCH Scholar, GMC, Srinagar.

Corresponding Author: Younis Kamal

Received: 29/06/2014

Revised: 24/07/2014

Accepted: 28/07/2014

ABSTRACT

Context: Rotator cuff tears is an important cause of shoulder pain and MRI is limited by its cost and availability especially in the developing countries.

Aims: This study was undertaken to find the degree of agreement between MRI and high resolution Ultrasonography in the diagnosis of Rotator cuff tears (RCT).

Methods and Material: Fifty consecutive patients with shoulder pain who were clinically suspected of RCT underwent ultrasonography and subsequent MRI was done. According to standardized procedures, Sonography was performed by a radiologist. USG and MRI results were scored as negative or positive for the presence of a full-thickness and partial thickness RCT.

Statistical analysis: The agreement between the two methods was assessed using kappa coefficient.

Results: Out of 50 patients, a total of 34 patients were diagnosed as having rotator cuff tears on ultrasound while 16 patients were normal. When MRI examination was conducted in these patients, it showed 38 cases of rotator cuff tears while 12 patients were diagnosed as normal. The agreement between the two methods was assessed using kappa coefficient. The strength of agreement between USG and MRI for the diagnosis of rotator cuff tears was found to be 'very good'.

Conclusions: Out of 50 patients, a total of 34 patients were diagnosed as having rotator cuff tears on ultrasound while 16 patients were normal. When MRI examination was conducted in these patients, it showed 38 cases of rotator cuff tears while 12 patients were diagnosed as normal. The agreement between the two methods was assessed using kappa coefficient. The strength of agreement between USG and MRI for the diagnosis of rotator cuff tears was found to be 'very good'.

Key-words: Rotator cuff tears, Ultrasound, Magnetic resonance imaging

Key message

The high resolution sonography is an attractive screening modality for rotator cuff in patients presenting with painful shoulder. A well performed ultrasound examination in most cases obviates the need for more invasive diagnostic tests like arthrography and cumbersome and expensive MRI examinations.

INTRODUCTION

Rotator cuff pathology is the most frequent (10%) cause of shoulder pain and disability. The prevalence increases linearly with age from the third decade onwards. [1] Contrast arthrography has long been the premier radiological examination used to diagnose full thickness tears of the rotator cuff. [2] Unfortunately, arthrography is an invasive procedure a high rate of delayed morbidity. It is also relatively expensive and time-consuming. [3]

Two competing non invasive imaging techniques, ultrasound (USG) and magnetic resonance imaging (MRI), are taking over the role of arthrography. Both MRI and USG are widely used for the evaluation of pathologic conditions of the rotator cuff and essentially obviate conventional arthrography.

High resolution real-time ultrasonography has been shown to be cost effective means of examining the rotator cuff. [4] Various authors have suggested that the ultrasound is as accurate as MRI for both full-thickness tears and partial-thickness tears. These results, combined with the lower cost for ultrasound, suggest that ultrasound may be the most cost-effective imaging method for screening of rotator cuff tears provided that the examiner has been properly trained in this operator-dependent technique. [5]

MATERIALS AND METHODS

A prospective study was conducted on 50 consecutive patients who presented in orthopedic outpatient department (OPD) with shoulder pain and suspected clinically of having rotator cuff tear (RCT). All patients with previously proven diagnosis of rotator cuff tear and Patients who had undergone shoulder surgery for any reason were excluded from the study. The patients were examined in the sitting position, on a rotating seat. The sonography was

performed using Logic 500 Pro series (GE) equipped with a phased array linear 8 MHz to 11 MHz transducer. The ultrasound examination was done according to American Institute of Ultrasound in Medicine (AIUM) Practice Guidelines (2007) for the Performance of the Musculoskeletal Ultrasound Examination. Ultrasound examination of the contralateral shoulder was done in each patient for comparison. All patients were followed for MRI shoulder, and the MRI findings recorded and correlated with ultrasonography findings.

Ultrasonographic criteria for the diagnosis of rotator cuff tears include direct and indirect signs. The direct signs were considered reliable in our study for sonographic diagnosis of rotator cuff injury and include signs for a full-thickness rotator cuff tear and signs for partial thickness tear. The direct signs for full thickness rotator cuff tears (RCT) include: Nonvisualization or absence of cuff tissue, Full-thickness discontinuity or hypoechoic defect of the rotator cuff with visible margins of the tear, A heterogeneously hypoechoic cuff with bursal fluid, and severe distortion of cuff architecture, Focal thinning of the rotator cuff and Loss of the convexity of the outer border of the rotator cuff. The indirect signs for full thickness RCT include: a hypoechoic defect that involves the articular or bursal surface, a focal hypoechoic zone within the substance of the cuff, thinning of the cuff (marked during passive movement), and loss of the convexity of the outer border of the rotator cuff. The last two criteria overlap with those for full-thickness tears and were considered in correlation with other associated findings as mentioned above.

The indirect sonographic signs for RCT are; cortical outpouchings or pitting at the insertion of the rotator cuff tendons, fluid in the joint cavity and subacromial/subdeltoid bursa, the ability to

compress the deltoid muscle into a cuff defect or against the humeral head (naked tuberosity sign), a bright aspect of the humeral cartilage (cartilage interface sign or uncovered cartilage sign) and muscle atrophy.

All MRI examinations were performed with a 0.5-T MR system (Signa Contour, GE Medical Systems). A flexible surface coil for shoulder was used. The patients were positioned in the magnet supine with the arms along the thorax and the affected arm externally rotated.

The MRI shoulder protocol consisted of: Oblique sagittal T1-weighted Fast spin echo(FSE) images, Oblique coronal T1-weighted FSE, T2-weighted FSE, proton density images and STIR(Short tau inversion recovery) images, Axial gradient echo images.

MRI findings were classified into intact cuff, partial-thickness and full-thickness rotator cuff tears. Established criteria were used for the diagnosis of a partial-thickness or full-thickness rotator cuff tears. MRI findings for a full-thickness rotator cuff tear include: Visualization of a complete defect in the tendon, extending from the articular to the bursal surface of the tendon, with presence of fluid-like signal within the defect on long TR/TE(relaxation time/echo time) images and Retraction of the musculotendinous junction.

Secondary signs include diffuse loss of the peribursal fat plane and the presence of fluid in the subdeltoid bursa, fluid in the glenohumeral joint, muscle atrophy, a decrease in the acromialhumeral distance to less than 7 mm and the presence of acromioclavicular joint cysts.

MRI findings for a partial-thickness rotator cuff tear include: Focal area of mildly increased signal intensity on PD images, which increases in signal intensity on T2-weighted images, and extends to one surface only, either the articular surface, or the

bursal surface, or is within the tendon substance itself (intrasubstance or interstitial) and Contour irregularities (attenuated or thickened tendon) or partial cuff fiber retraction.

Free fluid may be present within the subacromial–subdeltoid bursa if the tear is located on the superior bursal surface, or within the glenohumeral joint if the tear is located inferiorly at the articular surface.

RESULTS

There were 28(56%) males and 22(44%) females. Thus the male: female ratio is 1.3 : 1. We found statistically no significant difference in the prevalence of shoulder pain related to gender.

Distribution of patients with shoulder pain according to decade of life was; 5 (10%) patients in 30-40 years age group, 11 (22%) were in 41-50 years age group, 14 (28%) were in the 51-60 years age group while 20 (40%) patients were 61 years and above.

The prevalence of shoulder pain was observed to increase with the increasing age. The highest number of patients was observed in age group 61 years and above (40%). Night pain was present in 24 patients out of 50 patients. Thus night pain was seen in 48% patients.

The number of patients with right shoulder pain was 42 (84%) and left shoulder pain was 8 (16%).

Out of 33 patients who were right handed, 32 patients had RCT involving the right shoulder and 1 had RCT involving the left shoulder. Out of 5 patients who were left handed, 3 patients had RCT involving the left shoulder and 2 had RCT involving the right shoulder. It suggests that dominant arm is more susceptible to wearing effects and thus leads to RCT.

On ultrasound examination out of 50 patients, 20 patients showed full thickness tears, 14 patients were diagnosed as having

partial thickness tear and 16 patients were normal. Thus USG showed a total of 34 patients with rotator cuff tears.

On MRI out of 50 patients 22 patients showed full thickness tears, 16 patients were diagnosed as having partial thickness tear and 12 patients were normal. Thus a total of 38 patients were diagnosed as having rotator cuff tears on MRI.

Thus out of 50 patients, a total of 34 patients were diagnosed as having rotator cuff tears on ultrasound while 16 patients were normal. When MRI examination was conducted in these patients, it showed 38 cases of rotator cuff tears while 12 patients were diagnosed as normal.

The agreement between the two methods was assessed using kappa coefficient. The strength of agreement between USG and MRI for the diagnosis of rotator cuff tears was found to be 'very good'.

Out of 34 patients with supraspinatus tears on USG, 20 patients showed full thickness tears & 2 patients with MRI proven full thickness tear were falsely diagnosed as having partial thickness tear. Ultrasound also showed 12 partial thickness tears & 2 patients with MRI proven partial thickness tear were falsely diagnosed as normal. On total, Ultrasound detected 32 truly positive supraspinatus tears (20 full & 12 partial thickness tears), 2 falsely positive partial tears, 2 falsely negative as normal while 14 patients were diagnosed as normal (True negative).

Table 1. Agreement between USG and MRI for the diagnosis of rotator cuff tears

		MRI			Total
		No Tear	PTT	FTT	
USG	No Tear	12	4	0	16
	PTT	0	12	2	14
	FTT	0	0	20	20
Total		12	16	22	50

PTT: partial-thickness rotator cuff tears, FTT: full-thickness rotator cuff tears, TP: true positive, TN: true negative, FP: false positive, FN: false negative.

Kappa= 0.818 , SE of kappa = 0.069

95% confidence interval: From 0.683 to 0.952
(0.20 and lower= no or poor agreement; 0.21-0.4= low agreement; 0.41-0.60=moderate agreement; 0.61-0.80= good agreement; 0.81 and higher= very good agreement).

When MRI was conducted on these patients, 38 patients showed having supraspinatus tears while 12 patients showed no Supraspinatus tears & diagnosed as normal, Out of 38 patients with supraspinatus tears, 22 patients showed full thickness tears & 16 were having partial thickness tears.

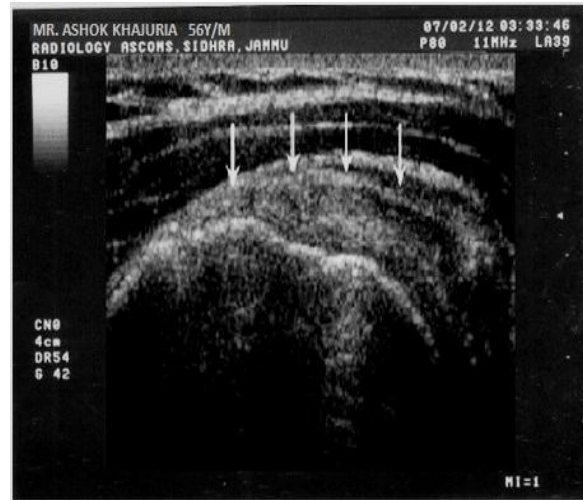


Fig. 1A. USG showing the normal supraspinatus tendon (longitudinal view).

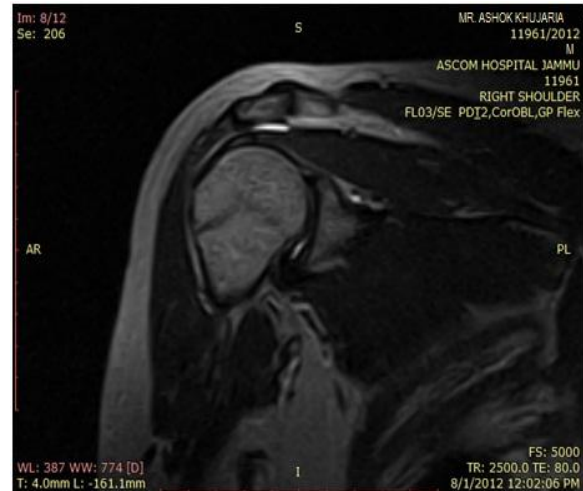

Fig. 1B. Coronal oblique proton density weighted MR image showing the normal longitudinal view of the supraspinatus tendon.

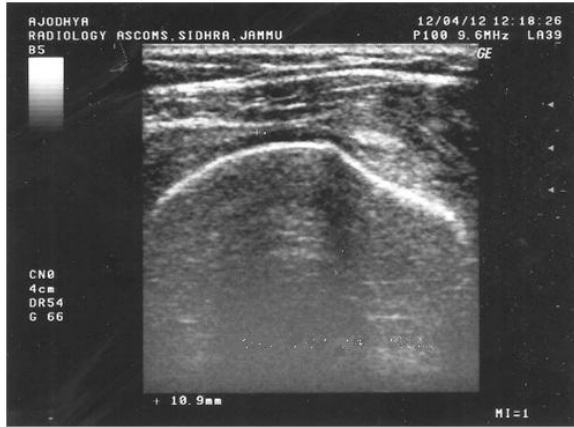

Fig. 2A. Ultrasound images of supraspinatus tendon (longitudinal axis) showing full-thickness tear of supraspinatus tendon (between the calipers). Note the loss of normal superior convexity of the supraspinatus tendon with deltoid muscle and dipping of the deltoid muscle into torn tendon gap.

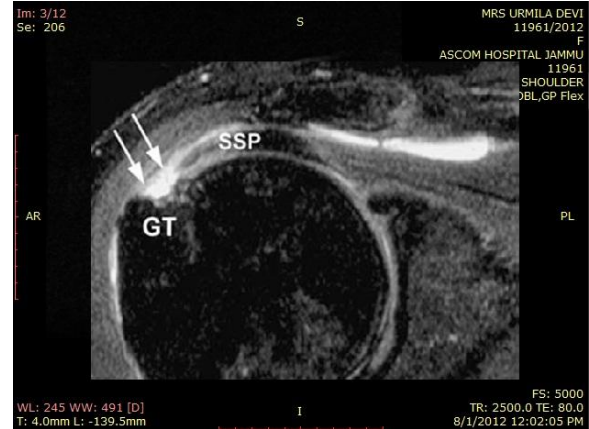

Fig. 3B. The corresponding oblique coronal fat suppressed MR image, showing the same configuration of the full-thickness tear (arrows) of the supraspinatus tendon (SSP). (GT = greater tuberosity).

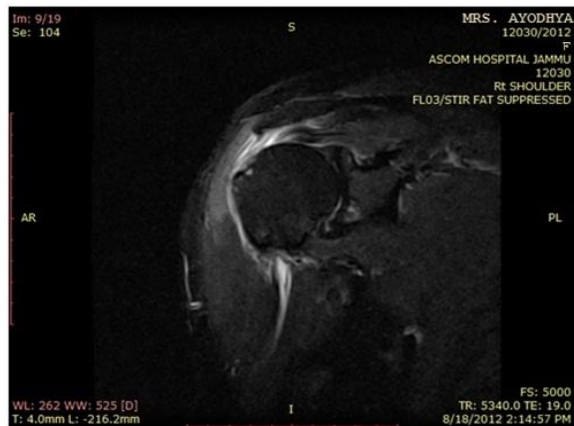


Fig. 2B. Corresponding coronal oblique fat suppressed MR image shows the full-thickness rotator cuff tear and the torn retracted edge of the supraspinatus tendon, with tendon retraction to the level of the humeral dome.

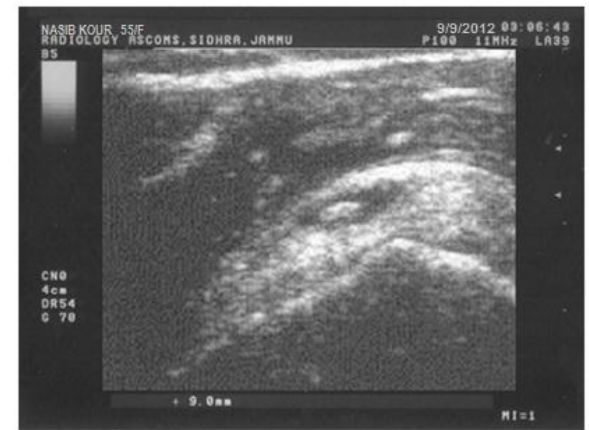

Fig. 4A. USG shows a hypoechoic defect involving the bursal surface of the supraspinatus tendon suggestive of bursal surface partial thickness rotator cuff tear.

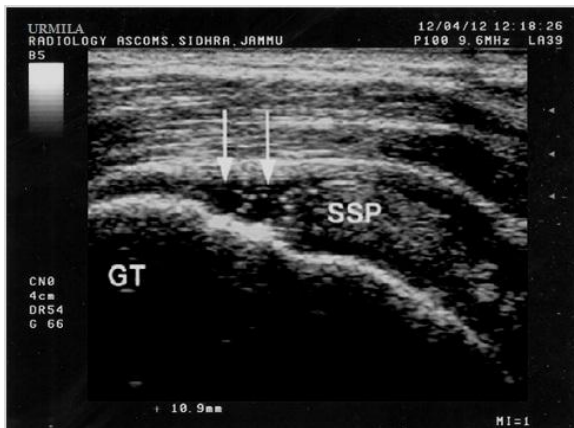

Fig. 3A. USG appearance of a full-thickness rotator cuff tear (arrows) at the insertion of the supraspinatus tendon (SSP). (GT =greater tuberosity).

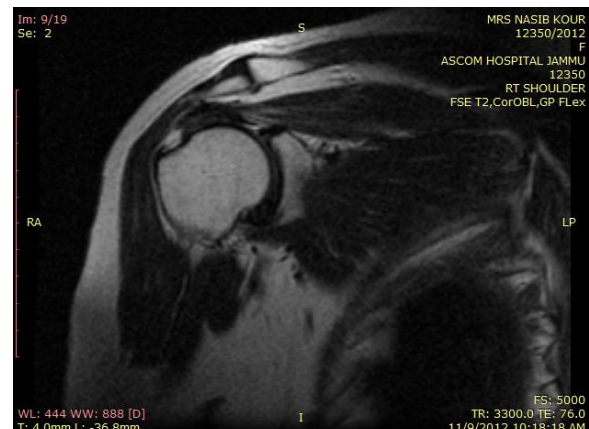


Fig. 4B. T2 weighted MR image shows a hyperintense area involving the bursal surface of the of the supraspinatus tendon suggestive of bursal surface partial thickness rotator cuff tear.

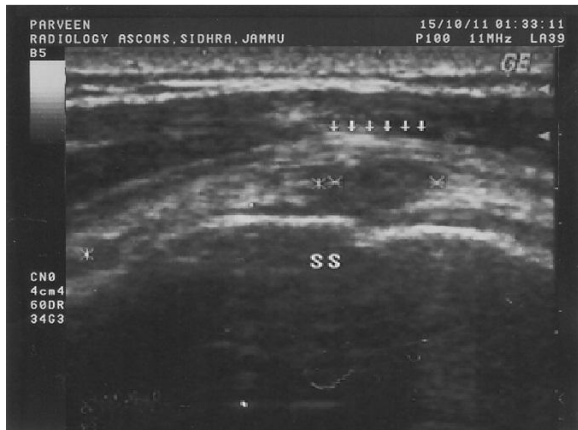

Fig. 5A. USG demonstrates a hypoechoic area involving the articular surface of the supraspinatus tendon with a few intact bursal sided fibers suggestive of articular surface partial thickness tear.

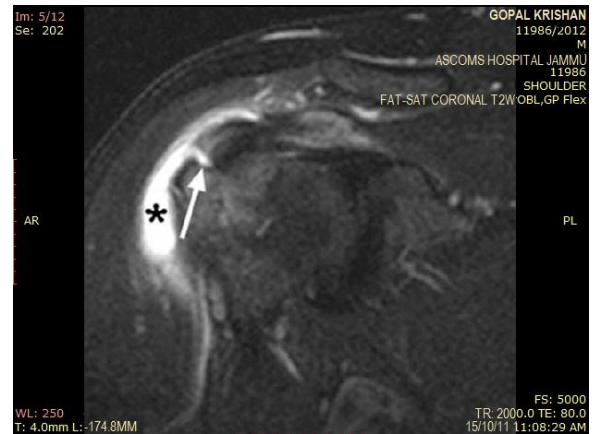


Fig. 6B. A fat-suppressed coronal MR image demonstrates subacromial-subdeltoid bursal fluid (asterisk). Also a bursal-sided partial thickness tear (arrow) is seen near the insertion of the cuff.

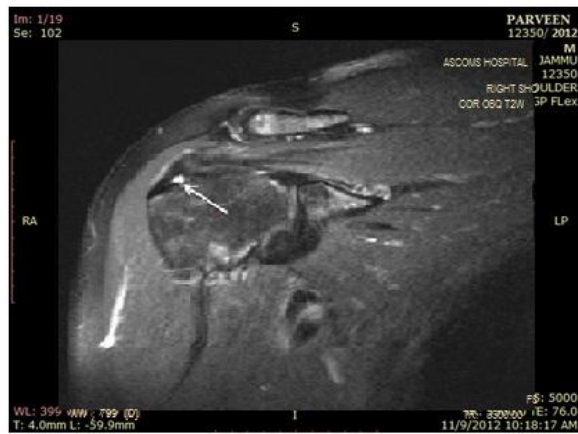

Fig. 5B. Coronal oblique T2 weighted image shows a partial thickness tear (arrow) of the articular-sided fibers that involves <50% of the tendon; overlying bursal-sided fibers remain intact.

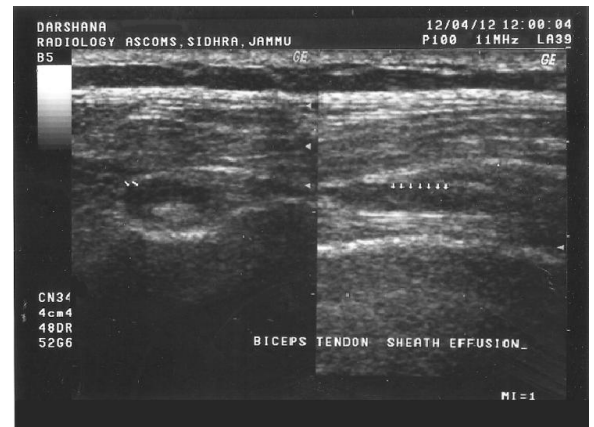


Fig. 7A. USG shows anechoic fluid surrounding the biceps tendon. Transverse view is shown on right side and the longitudinal view is shown on left side.

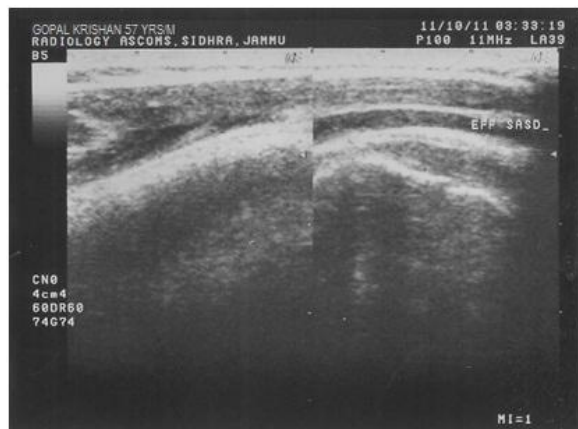


Fig. 6A. USG shows increased anechoic fluid in the subacromial-subdeltoid bursa.

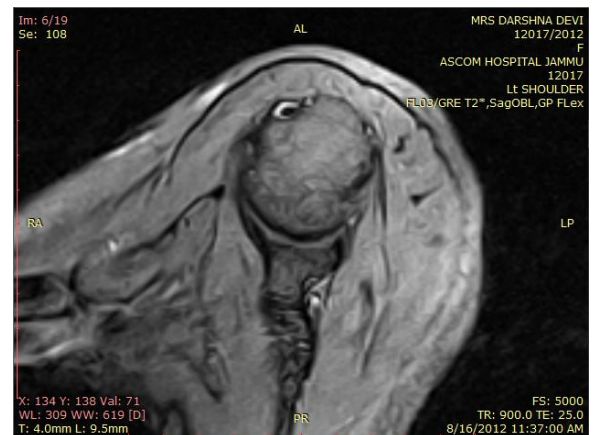


Fig. 7B. GRE MR image (axial view) shows hyperintense fluid surrounding the biceps tendon.

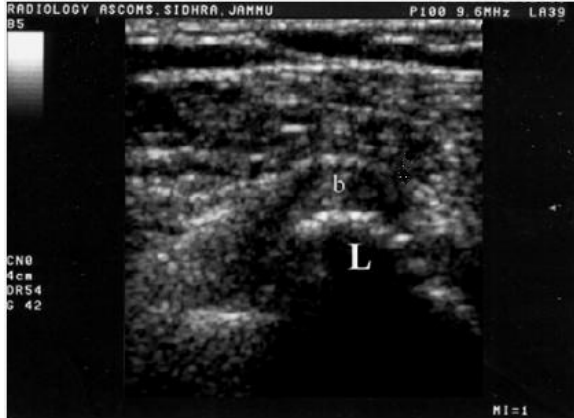

Fig. 8A. Transverse USG image shows subscapularis tendon tear with subluxation of the long head of the biceps tendon (b) perched on the lesser tuberosity (L) of the humerus.

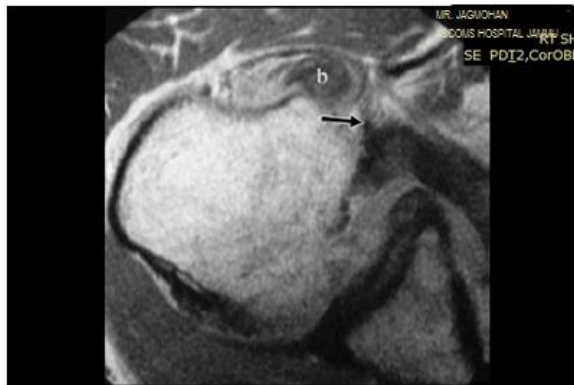

Fig. 8B. Corresponding axial proton density weighted MR image shows tear of the subscapularis tendon (arrow), with subluxation of the long head of the biceps tendon (b) perched on the lesser tuberosity (L) of the humerus.

DISCUSSION

Initial sonographic results in the detection of rotator cuff tears varied, [6] probably due to the use of low frequency (and low resolution) 5 MHz transducers and limited experience with the examination procedure. Subsequently technical improvements such as 7.5–14 MHz linear array broad-bandwidth transducers and better penetration of the ultrasound beam, as well as increased experience and detailed knowledge of shoulder anatomy and pathology significantly improved sonographic results and reliability. [7]

Our study indicated no statistically significant difference in the prevalence of rotator Cuff tear in each gender, which

correlates to the study carried by Milgrom et al. [8]

The ages of all the cases ranged from 30 to 72 years (mean age 48.02 years). Out of these 50 patients; 5(10%) patients were in 30-40 years age group, 11(22%) were in 41-50 years age group, 14 (28%) in the were in the 51-60 years age group while 20(40%) patients were 61 years and above. This suggests that there is an increase in the prevalence of shoulder pain and rotator cuff tears with advancing age.

The tendon degeneration occurs as part of the aging process [9] and occurs most commonly in the patients over 50 years of age. This correlates with the study by Brandt et al [6] who reported that symptomatic rotator cuff tears occur most commonly in patients over the age of 50 years. Progressive tendon failure then leads to rotator cuff rupture. [10] Consequently, tendinitis and tears of the rotator cuff usually occur in patients over the age of 50 years. [11] Milgrom et al [8] showed a linear increase in rotator cuff tears after the fifth decade of life. These observations corroborates with the findings of our study.

42 patients (84%) had pain involving the right shoulder and 8 patients (16%) had pain involving the left shoulder. Thus right shoulder was more frequently involved than the left shoulder. It correlates with the study by Bouaziz et al [12] who found right shoulder involvement (68%) more frequent than the left shoulder (32%).

We performed the ultrasound by using high frequency linear array transducer. Development of high resolution equipments as well as high frequency transducers has greatly increased the efficacy of ultrasonography. [13] Ultrasound examination of the contralateral shoulder was done in each patient for comparison. Rutten [14] recommended comparison with the contralateral shoulder as an additional

support for avoiding misinterpretation of normal anatomic differences as tears.

The agreement between the two methods was assessed using kappa coefficient (Kappa= 0.818). The strength of agreement between USG and MRI for the diagnosis of rotator cuff tears is considered to be 'very good'. Similar results were obtained by Alasaarela et al ^[15] and Rutten. ^[14] Alasaarela et al ^[15] evaluated 31 painful shoulders of 30 patients and reported a good agreement between US and MRI for diagnosis of full thickness tears and intrasubstance abnormalities of supraspinatus tendon (the kappa coefficient =0.73). Rutten ^[14] analyzed data of 68 patients who underwent MRI and surgery following USG examination and reported that agreement between US and MRI was high (the kappa coefficient was calculated to be 0.78).

Rutten ^[14] studied 68 patients and concluded that the diagnostic performances of high-resolution US and MR imaging in the detection of partial and full thickness tears of the rotator cuff is comparable, demonstrating an accuracy of 87% and sensitivities and specificities of over 90% respectively.

Our study has several important clinical implications. Firstly, a common approach towards the patients suspected of rotator cuff tears is to advise MRI (if available). Instead ultrasound could be advised which will save time, cost and improve clinical outfit of management. Secondly, patients with prosthesis, implants and claustrophobic patients which are the limitations of MRI can be benefited by ultrasound. The accuracy of ultrasound in experienced hands was found to be as good as that of MRI. ^[16] The MRI has shorter learning curve; it should be used secondarily and in selective cases because it provides more information about extent of tendons and has lower risk of artifacts. Due to the

cost difference between the two procedures, our study clearly shows that ultrasound is more cost-effective test to use for identification of rotator cuff tears. Radiology department should have experienced musculoskeletal sonologists, high frequency probes and equipments so that accurate and cost-effective diagnosis can be made. Our study showed that ultrasound is accurate in diagnosing rotator cuff pathologies which is in favorable comparison with Kenn et al ^[17] and Lach et al ^[18] who proved Ultrasound to be accurate and reliable in diagnosing a wide range of shoulder disorders compared with MRI.

There are several advantages of US over MRI. Ultrasound is available on a larger scale, portable, quick and a much more cost-effective imaging method, which is also easier tolerated by the patient. Ultrasound is not subject to motion artifacts, it allows instant comparison with the contralateral side, and tendons and other structures can be evaluated dynamically. The real time capability of US facilitates interventional procedures in or around the shoulder and allows better interaction with a patient who can point at the symptomatic area, which will optimize diagnostic yield. However, sonography of the shoulder joint is highly operator dependant. Small errors in transducer orientation and angulation may easily obscure small abnormalities within and around the cuff and give rise to false positive and false negative results. ^[19] There is a steep learning curve for shoulder sonography. But these potential pitfalls can be avoided by thoroughly understanding the normal anatomy, strictly insisting on proper transducer and patient position and using opposite shoulder for comparison. This can make sonography an effective, reliable and non invasive means of detecting rotator cuff tears.

CONCLUSION

We can conclude that diagnostic accuracy of USG and MRI are comparable. USG and MR imaging can be used as a primary modality for evaluating the rotator cuff, because they have comparable degrees of accuracy. Modality choice should be based on several factors like availability, patient preference and clinical information being sought.

The high resolution sonography is an attractive screening modality for rotator cuff in patients presenting with painful shoulder. A well performed ultrasound examination in most cases obviates the need for more invasive diagnostic tests like arthrography and cumbersome and expensive MRI examinations.

REFERENCES

1. Murrell GA, Walton JR. Diagnosis of rotator cuff tears. *Lancet* 2001; 357:769–70.
2. Resnick D. Shoulder arthrography. *Radiol Clin North Am.* 1981; 19:243–52.
3. Middleton WD. Ultrasonography of the shoulder. *Radiol Clin North Am* 1992;30:927–40.
4. Marnix T. van Holsbeeck. The rotator cuff. In: Rumack C.M editor. *Diagnostic Ultrasound*, 3rd ed. Missouri: Mosby Elsevier 2005; p.889-90.
5. de Jesus JO, Parker L, Frangos AJ, NazarianLN. Accuracy of MRI, MR arthrography, and ultrasound in the diagnosis of rotator cuff tears: a meta-analysis. *AJR* 2009;192:1701-1707.
6. Brandt TD, Cardone BW, Grant TH, Post M, Weiss CA. Rotator cuff sonography: A reassessment. *Radiology* 1989; 173:323-327.
7. Jacobson JA, Lancaster S, Prasad A, van Holsbeeck MT, Craig JG, Kolowich P. Full-thickness and partial-thickness supraspinatus tendon tears: value of US signs in diagnosis. *Radiology* 2004; 230:234-42.
8. Milgrom C, Schaffler M, Gilbert S, van Holsbeeck M. Rotator cuff changes in asymptomatic adults: the effect of age, hand dominance, and gender. *J Bone Joint Surg [Br]* 1995; 77:296-98.
9. Chard MD, Cawston TE, Riley GP, Gresham GA, Hazleman BL. Rotator cuff degeneration and lateral epicondylitis: a comparative histological study. *Ann Rheum Dis.* 1994;53:30–34.
10. Dalton SE. The conservative management of rotator cuff disorders. *Br J Rheumatol.* 1994;33(7):663–7
11. Cofield RH. Rotator cuff disease of the shoulder. *J Bone Joint Surg Am.* 1985 Jul;67(6):974-9.
12. Bouaziz M C, Jabnoun F , Chaabane S, Ladeb M F . Diagnostic Accuracy of High Resolution Ultrasound in Communicating Rotator Cuff Tears. *Iran J Radiol* 2010;7(3): 153-160
13. Friedman L, Finlay K, Popowich T, Jurriaans E. Ultrasonography of the shoulder: pitfalls & variants. *J Can Assoc Radiol.* 2002; 53: 22-31.
14. Matthieu J.C.M. Rutten. General introduction Study aims outline of thesis. In: Matthieu J.C.M. Rutten, editor. *Ultrasound of the shoulder; efficacy studies.* 1st ed. The Netherlands: Ipskamp Drukkers; 2010. p. 15-19
15. Alasaarela E, Takalo R, Tervonen O, Hakala M, Suramo I. Sonography and MRI in the evaluation of painful arthritic shoulder. *Br J Rheumatol.* 1997Sep;36(9):996–1000.

16. Zlatkin MB, Hoffman C, Shellock FG. Assessment of the rotator cuff and glenoid labrum using an extremity MR system: MR results compared to surgical findings from a multi-center study. J Magn Reson Imaging. 2004; 19: 5: 623-31.
17. Kenn W, Hufnagel P, Muller T, Gohlke F, Bohm D. Arthrography, ultrasound and MRI in rotator cuff lesions: a comparison of methods in partial lesions and small complete ruptures. Rofo. 2000; 172: 3: 260-6. 28.
18. Lach W, Dudarenko G, Brzosko M, Cyrylowski L, Flicinski J. Usefulness of ultrasonographic and MR imaging in diagnosis of shoulder impingement. Chir Narzadow Ruchu Ortop Pol. 2003; 68: 5: 307-11.
19. Middleton WD, Reinus WR, Totty WG, Melson GL, Murphy WA. Ultrasonographic evaluation of the rotator cuff and biceps tendon. J Bone Joint Surg [Am] 1986; 68: 440-450.

How to cite this article: Bashir S, Firdose SR, Kamal Y et. al. Correlation between high resolution ultrasonography and MRI in rotator cuff tear diagnosis. Int J Health Sci Res. 2014;4(8):103-112.

International Journal of Health Sciences & Research (IJHSR)

Publish your work in this journal

The International Journal of Health Sciences & Research is a multidisciplinary indexed open access double-blind peer-reviewed international journal that publishes original research articles from all areas of health sciences and allied branches. This monthly journal is characterised by rapid publication of reviews, original research and case reports across all the fields of health sciences. The details of journal are available on its official website (www.ijhsr.org).

Submit your manuscript by email: editor.ijhsr@gmail.com OR editor.ijhsr@yahoo.com