



Case Report

Secondaries in Peritoneum Mimicking As Tuberculous Peritonitis

Manish Jadhao¹, Sanjay Chaudhary¹, Anjali Chitale²

¹2nd Year P.G. Student, ²Associate Professor,
Dept. of General Surgery, A.C.P.M. Medical College, Dhule, Maharashtra, India.

Corresponding Author: Manish Jadhao

Received: 15/05/2014

Revised: 06/06/2014

Accepted: 06/06/2014

ABSTRACT

Peritoneal tuberculosis may present with distinct clinical and pathologic features than its usual presentation. It frequently presents a problem in diagnosis and management. We report a case of secondaries in peritoneum with occult primaries, which initially appeared with intestinal obstruction clinically and intestinal tuberculosis on operative field. This is a rare initial manifestation in patients who have no clinical features of tuberculosis or malignancies.. We review the literature and discuss the clinical and dilemma about tuberculosis and secondary metastasis in peritoneum which was confirmed on histopathological examination.

Key words: Intestinal tuberculosis, pseudomyxoma peritoni, secondary metastasis. AKT, PET scan.

INTRODUCTION

Intestinal Tuberculosis is frequently misdiagnosed condition clinically. It has diverse and slightly confusing presentations, including abdominal distention, ovarian tumors, or appendicitis-like syndromes. In this article, we emphasize the unique pathophysiological, clinical, and management aspects of this disease entity. Peritoneal TB and primary peritoneal carcinoma can both present as an abdominal mass and ascites and should therefore be considered as a differential diagnosis.^[1] Before the discovery of effective medical therapy for TB (TBMT) there was no hope for recovery of patients with abdominal TB. Reactive fibrosis of the peritoneum and formation of adhesions with adjacent tissues is the usual picture on laparotomy. Abdominal

distention, pain and vomiting, and presence of signs of subacute intestinal obstructions lead to surgery most of the times

Secondaries in peritoneum and Tuberculous peritonitis can mimic each other, leading to misdiagnosis. Ascites of tuberculous peritonitis (TBP) is in exudative form and may commonly be misdiagnosed as carcinomatous peritonitis, especially in the elderly.^[2] Since the clinical manifestations of peritoneal tuberculosis may resemble those of ovarian carcinoma with ascites, abdominopelvic masses, and elevated CA 125, a number of women with this disease are first seen by a gynecologist. Some authors have postulated that malignancy is the primary lesion, followed by secondary tubercular infection of the malignant ulcer, which might have been

facilitated by luminal obstruction, impaired cellular immunity, and loss of the mucosal barrier.^[3] However, others have suggested that the longstanding tuberculous ulcer may be carcinogenic. Tuberculous lymphadenitis can mimic malignancy, especially when adherent to adjacent organs. biopsy specimen provides a faster, alternative route for diagnosis with high specificity^[4]

Radiologists should be knowledgeable about this rare entity to aid in making a definite diagnosis, which is best made on computed tomography, and thus help in the management of these patients.. Currently laparoscopy is also used as diagnostic method in acute abdomen conditions to diagnose malignancy or tuberculosis by taking tissue biopsy.

CASE REPORT

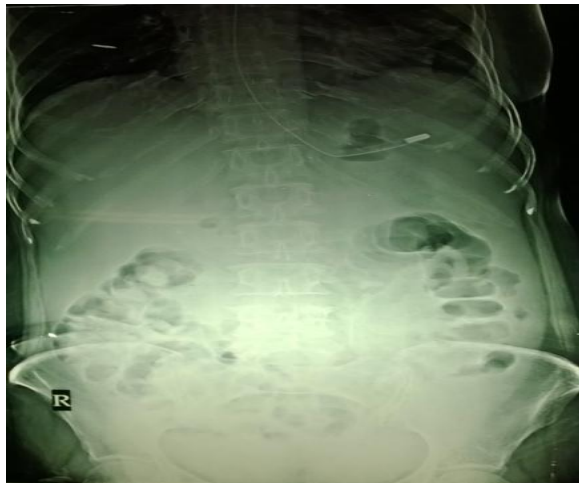


Figure 1 X ray Abdomen erect showing dilated bowel loops.

A 60 year old female presented with pain in abdomen and distention since 8 days, which was associated with subacute intestinal obstruction. There was no history of per rectal bleed, weight loss, fever, gynecological complaints or previous operation.

On examination patient was afebrile with normal vitals, per abdominal examination revealed generalized tenderness with guarding and distention. Bowel sounds were sluggish per rectal and per vaginal examination was normal. Patient was investigated further.

Hemogram was within normal limits, Xray abdomen standing was inconclusive without air fluid levels or gas under diaphragm [fig1]. Ultrasonography abdomen showed free fluid in abdomen with dilated bowel loops [fig2]. CT abdomen showed similar findings.

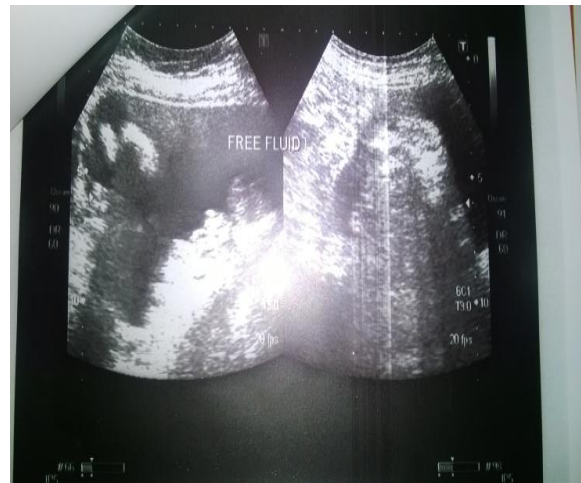

Figure 2 USG Abdomen with free fluid in peritoneal cavity.

Ryles tube aspirate was greenish in colour and distention increased in 48 hrs in spite of taping which revealed transudative ½ liter of fluid cytologically suggestive of peritonitis, so patient was shifted to operation theater for laparotomy.

Intra operative findings were, plaster like abdomen with omentum fibrosed and adhered to intestine. Intestinal serosa showed innumerable whitish nodules nearly 1-2 mm all over.[fig3].Due to intensive adhesions it was not possible to trace total length of bowel.No mass was palpable elsewhere in peritoneal cavity . Omental biopsy with 3250 mili litres of transudate fluid which was aspirated and sent for cytology and histopathological examination,which showed metastatic adenocarcinoma in peritoneum.[fig4.1 and 4.2]

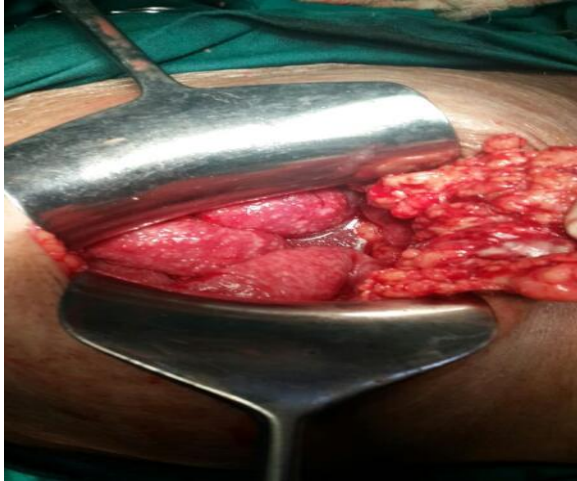

Figure 3 Operative finding with fibrosed omentum and white Tubercles.

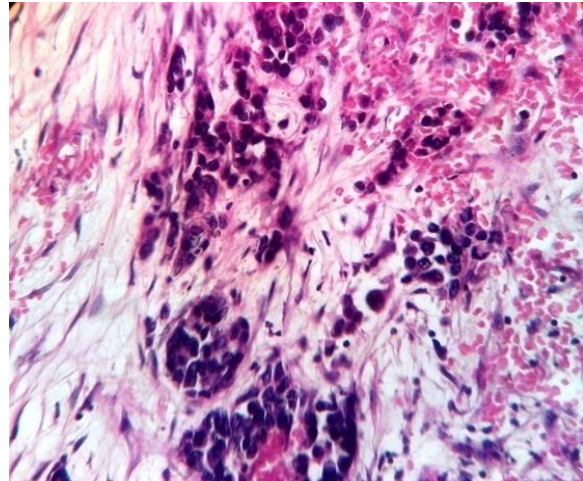


Figure 4.1 Histopathological finding showing malignant cells.

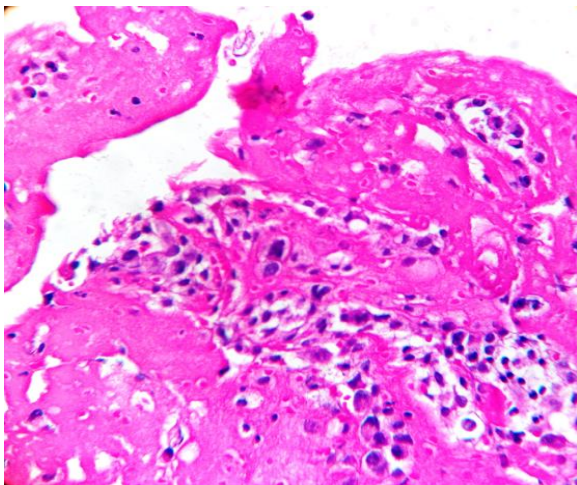


Figure 4.2 Histopathological finding showing malignant changes.

Intraoperatively primary foci was not appreciated. It required further investigation like PET scan and to treat accordingly. But due to unavailability of PET scan patient was counseled and referred to higher centre with proper documentation for further diagnosis and management.

DISCUSSION

Another differential diagnosis of secondaries in peritoneum along with tuberculous peritonitis is *Pseudomyxoma peritonei* which is a disease process characterized by copious mucinous ascites and histologically bland peritoneal mucinous

tumor. It is attributable to a ruptured mucinous cystadenocarcinoma (appendiceal origin in most cases). It has an indolent course but may recur over months to years.

Peritoneal mucinous carcinomatosis is a disease process characterized by abundant peritoneal mucinous tumor, and its clinical appearance is similar to that of pseudomyxoma peritonei. However, the peritoneal cells have architectural and structural features of carcinoma. These cells are derived from the gastrointestinal mucinous adenocarcinomas and are associated with a significantly worse prognosis.^[5]

In the past, pseudomyxoma peritonei was said to occur from a variety of primary tumors. This may be true, but in the vast majority of cases, the patients have an appendiceal tumor giving rise to this clinical entity.^[6] Mucinous peritoneal carcinomatosis may arise from other sites, such as the colon, gallbladder, pancreas, or stomach, but these tumors usually have signet ring histology. They may show redistribution but do not spare the small bowel and will implant and grow in the abdominal cavity in a random fashion with extensive small bowel involvement, resulting in a much poorer prognosis.

Main difference with secondaries in peritoneum with pseudomyxoma cells is, Pseudomyxoma cells do not have adherence molecules on their cell surface. This lack of "stickiness" means that the tumor cell will not actively attach to an abdominal or pelvic surface. The tumor will progress by the production of mucus, exfoliation of tumor cells, and a redistribution of these cells around the abdomen according to the aforementioned physiologic mechanisms. The "dissecting mucus" that is recognized by the pathologist as part of the histologic picture of pseudomyxoma peritonei should not be confused with invasive malignancy, which is not a part of this syndrome.^[7]

Secondaries in peritoneum are a distinct clinical entity from intestinal tuberculosis with unique clinical and pathologic features. It requires vigilance by the clinician, gastroenterologist, or surgeon who evaluates the patient initially, since early diagnosis is essential for the appropriate treatment of this disease. It may rarely manifest as intestinal obstruction, and the patient may have emergency surgery and small bowel resection, which lead to an adverse outcome.^[8]

In some cases the primary tumour in the appendix can be quite inconspicuous in the context of abundant mucinous peritoneal tumour. In addition, rupture and fibrosis can obliterate the appendix. Other problems are that ovarian tumours are often interpreted pathologically as primary mucinous borderline malignant tumours.^[9] This happens particularly when the appendix has not been removed but even occurs when an appendiceal adenoma is identified. There is evidence that the ovarian mucinous tumours in PMP are on the surface of the ovary and secondarily derived from the associated appendiceal mucinous tumour.

CONCLUSION

The diagnosis of secondaries in peritoneum can be difficult. It is often an unexpected finding during investigations of non-specific abdominal symptoms, either on USG/CT scan or the patient has undergone laparotomy. The diagnosis of carcinomatous peritonitis can be difficult on gross examination which may look like intestinal tuberculosis. Women with both low-grade mucinous carcinoma peritonei and high-grade mucinous carcinoma peritonei often have ovarian involvement by mucinous tumour. The ovarian tumour is often the presenting clinical symptom or sign and is often assumed to be the primary site, therefore no attempt is made to identify the appendix as a possible source of mucinous tumour.

In our case patient neither showed symptoms of tuberculosis or malignancy were present. Hence with such varied presentation Further evaluations like CT scan and PET scan and Immunohistochemistry are important to diagnose primary occult malignancies preoperatively. Histopathological diagnosis gives specific plan to manage patient further either with AKT or Chemotherapy depending upon the diagnosis.

REFERENCES

1. Balamurugan R, Venkataraman S, John KR, Ramakrishna BS: PCR amplification of the IS6110 insertion element of Mycobacterium tuberculosis in fecal samples from patients with intestinal tuberculosis. J Clin Microbiol 2006, 44:1884-1886.
2. Chatzicostas C, Koutroubakis IE, Tzardi M, Roussomoustakaki M, Prassopoulos P, Kouroumalis EA: Colonic tuberculosis mimicking Crohn's disease: case report. BMC Gastroenterol 2002, 2:10.
3. Singh V, Kumar P, Kamal J, Prakash V, Vaiphei K, Singh K:

- Clinicocolonoscopy profile of colonic tuberculosis. Am J Gastroenterol 1996, 91:565-568.
4. Marschall JB: Tuberculosis of the gastrointestinal tract and the peritoneum. Am J Gastroenterology 1993, 88
 5. Singal R, Gupta S, Gupta S (2012) Primary abdominal tuberculosis presenting as peritonitis in a young child-managed surgically. Asian Pac J Trop Med 5: 413-415.
 6. Carter J, Moradi MM, Eig S. Pseudomyxoma peritonei - experience from a tertiary referral center. Aust NZ J obstet Gynaecol Pathol 1992; 31:177-8.
 7. Sanford HB, Kathryn M. Pseudomyxoma peritonei. N Eng J med 2004; 350:15.
 8. Serhig S. Tuberculous peritonitis, A review of 100 cases. Am Rev Respir Dis 1967; 95: 398-401.
 9. Gilinsky NH, Marks IN, Kottler RE, Price SK. Abdominal tuberculosis, A10 years review. SA Med J 1983; 64: 849-857.

How to cite this article: Jadhao M, Chaudhary S, Chitale A. Secondaries in peritoneum mimicking as tuberculous peritonitis. Int J Health Sci Res. 2014;4(7):257-261.

International Journal of Health Sciences & Research (IJHSR)

Publish your work in this journal

The International Journal of Health Sciences & Research is a multidisciplinary indexed open access double-blind peer-reviewed international journal that publishes original research articles from all areas of health sciences and allied branches. This monthly journal is characterised by rapid publication of reviews, original research and case reports across all the fields of health sciences. The details of journal are available on its official website (www.ijhsr.org).

Submit your manuscript by email: editor.ijhsr@gmail.com OR editor.ijhsr@yahoo.com