



Original Research Article

Incidence of Absence of Palmaris Longus in North Karnataka Region: A Cadaveric Study

Amit Magadam¹, Daksha Dixit², Shilpa Bhimalli³

¹Assistant Professor, ²Professor and Head, ³Associate Professor,
Department of Anatomy, KLE University's J. N. Medical College, Belgaum, Karnataka, India.

Corresponding Author: Amit Magadam

Received: 13/04/2014

Revised: 05/05/2014

Accepted: 05/05/2014

ABSTRACT

Introduction: Palmaris longus is a slender, fusiform muscle lying medial to flexor carpi radialis. It arises from the medial epicondyle of humerus by the common tendon, and from adjacent intermuscular septa and deep fascia of the arm. Palmaris longus is often absent on one or both sides.

Aim of the Study: To determine the incidence of unilateral and bilateral absence of palmaris longus in the north Karnataka region.

Materials and Methods: Dissection of 30 embalmed adult cadavers (60 upper limbs) of both sexes belonging to north Karnataka region were carried out and observed for the presence or absence of palmaris longus muscle.

Results: Bilateral absence of palmaris longus was observed in 2 cadavers (1 male and 1 female). Unilateral absence was observed in the right side of 1 male cadaver.

Conclusion: The incidence of absence of palmaris longus muscle in the north Karnataka region will be useful to surgeons doing tendon graft surgeries.

Key Words: Palmaris longus, Reconstructive surgery, Tendon grafts, Cadavers.

INTRODUCTION

Palmaris longus is a slender, fusiform muscle lying medial to flexor carpi radialis. It arises from the medial epicondyle of humerus by the common tendon, and from adjacent intermuscular septa and deep fascia of the arm. It converges to form a long tendon, which passes superficial to the flexor retinaculum. As the tendon crosses the retinaculum it broadens out to become a flat sheet which becomes incorporated into the palmar aponeurosis. Palmaris longus is often absent on one or both sides. [1]

Palmaris longus is often described as one of the most variable muscles in the human body and is phylogenetically classified as a retrogressive muscle. [2] Although it plays a role in carpal flexion, its main function appears to be as an anchor for the skin and fascia of the hand, in resisting horizontal shearing forces in a distal direction, which would tend to deglove the skin of the palm. [1]

The aim of this study was to determine the incidence of unilateral and bilateral absence of palmaris longus for the population of north Karnataka region.

MATERIALS AND METHODS

Dissection of 30 embalmed adult cadavers (60 upper limbs) of both sexes (20 males and 10 females) belonging to north Karnataka region were carried out in the Anatomy dissection hall of J.N Medical College, Belgaum. Later, the presence or absence of palmaris longus was recorded. It was a cross-sectional type of study.

RESULTS

Bilateral absence of palmaris longus was observed in 2 cadavers (1 male and 1 female) as shown in figure number 1 to 4. Unilateral absence was observed in the right side of 1 male cadaver (figure 5). In all other dissected upper limbs palmaris longus was seen bilaterally with normal morphology. The incidence of absence of palmaris longus in north Karnataka region is shown in table 1.

Table 1: Incidence of absence of palmaris longus in north Karnataka region.

Palmaris longus	Number of cadavers	Incidence of absence of palmaris longus (%)
Unilateral absence	1	3.33%
Bilateral absence	2	6.66%
Total absence	3	10.00%

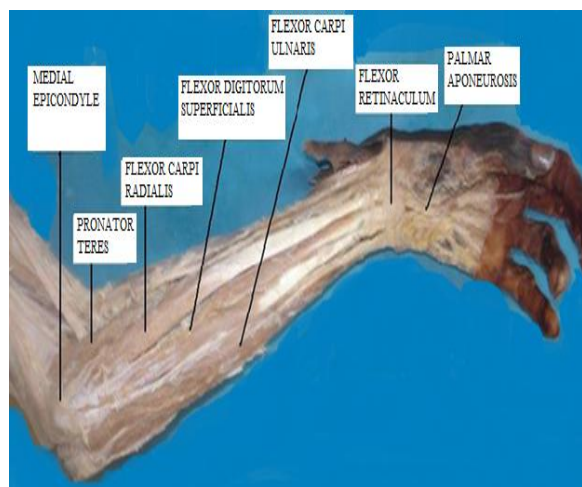


Figure 1: Cadaver Number 1 (Left Upper Limb – Palmaris Longus Absent).

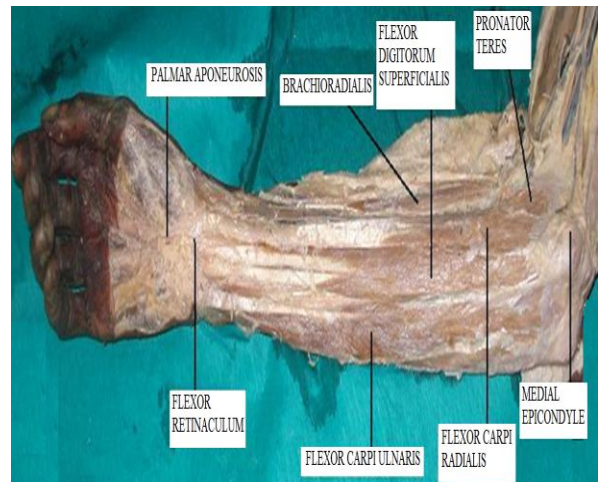


Figure 2: Cadaver Number 1 (Right Upper Limb – Palmaris Longus Absent).

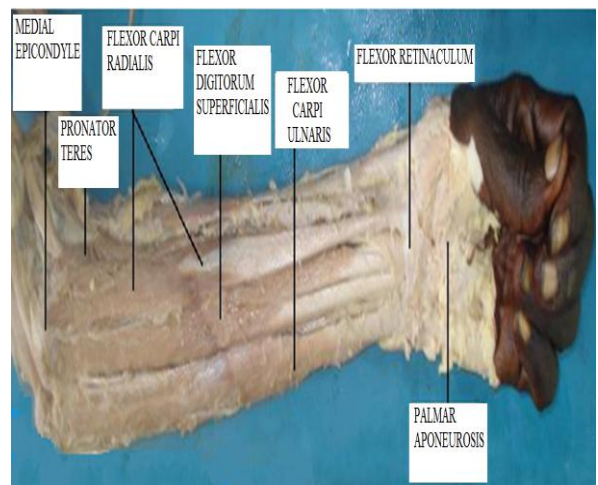


Figure 3: Cadaver number 2 (Left Upper Limb - Palmaris Longus Absent).

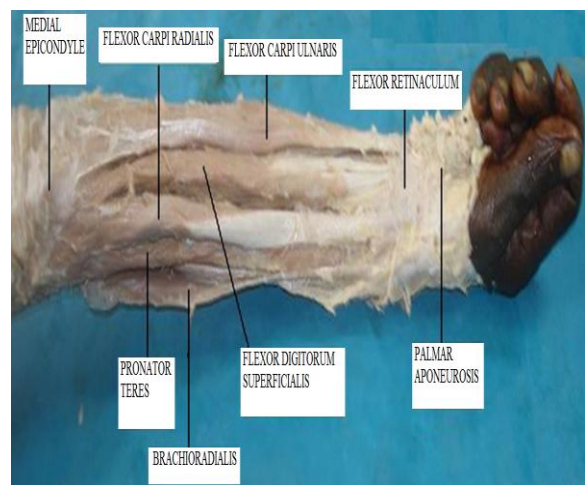


Figure 4: Cadaver number 2 (Right Upper Limb - Palmaris Longus Absent).

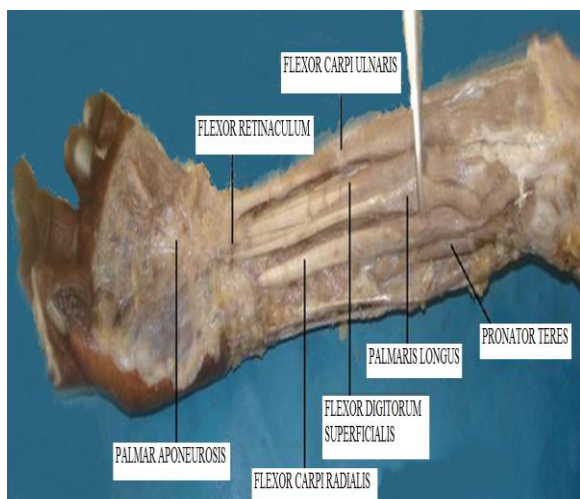


Figure 5: Cadaver number 3 (Left Upper Limb - Palmaris Longus Present).

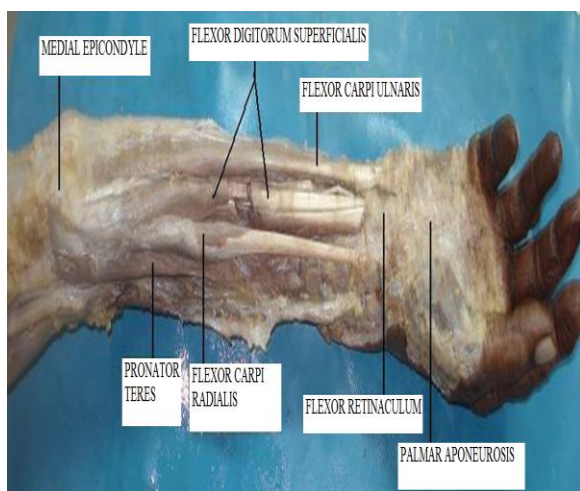


Figure 6: Cadaver Number 3 (Right Upper Limb - Palmaris Longus Absent).

DISCUSSION

The palmaris longus is seen as a small tendon between the flexor carpi radialis and the flexor carpi ulnaris, although

it is not always present. The muscle is absent in about 14 percent of the population, however this varies greatly with ethnicity. Palmaris longus is often absent on one or both sides. Absence of palmaris longus does not have any known effect on grip strength.^[3]

Tendon grafts are frequently needed in reconstructive surgery on the hand. Many surgeons agree that the palmaris longus tendon is the first choice as a donor tendon because it fulfils the necessary requirements of length, diameter and availability, and can be used without producing any functional deformity. The palmaris longus tendon is often considered the ideal donor for tendon grafts for replacement of the long flexors of the fingers.^[4] The absence of the muscle has been described as ranging from a high of about 25% to 16% in white caucasians to a low of 4% in mongoloids. An average of 10% absence has been universally accepted.^[2]

In our study we observed the absence of palmaris longus muscle in 10% of bodies studied which is far less than other Indian cadaveric study done by Pai MM et al^[2] (26%). Incidence of our study is comparable with the cadaveric studies done by Baral P et al^[5] (8.33%) and Reimann AF et al^[6] (12%). Other studies done on living human beings and cadavers are tabulated in table number 2.

Table 2: Distribution of absence of palmaris longus in different populations of the world.

S.No	Different populations	Type of study	Percentage of absence (agenesis) of palmaris long	Authors	Year of study
1	Mangalore	Cadaveric	26.00%	Pai MM et al ^[2]	2008
2	Nepal	Cadaveric	8.33%	Baral P et al ^[5]	2009
3	Chicago	Cadaveric	12.00%	Reimann AF et al ^[6]	1944
4	Europe	Cadaveric	16.00%	Moss A.L.H. ^[7]	1988
5	Iran	Cadaveric	29.60%	Mobarakeh MK ^[8]	2008
6	India	Human	16.90%	Pawan Agarwal ^[9]	2010
7	China	Human	4.60%	Sebastin SJ ^[10]	2006
8	North Karnataka	Cadaveric	10.00%	Present study	2013

CONCLUSION

The incidence of bilateral absence of palmaris longus was found to be 6.66% and unilateral absence of palmaris longus was found to be 3.33% in the cadavers of north Karnataka region. The overall total absence of palmaris longus in our study was found to be 10% which is lower than other Indian populations as mentioned in the literature. These findings will document the incidence of agenesis in the north Karnataka region and will be useful to surgeons doing tendon graft surgeries.

ACKNOWLEDGEMENT

The authors are highly thankful to the KLE University's J. N. Medical College, Belgaum, for providing the necessary support and infrastructure facility to carry out this study.

REFERENCES

1. Johnson D, Ellis H. Pectoral Girdle and Upper Limb. In: Standring S. Gray's Anatomy. The Anatomical Basis of Clinical Practice. 39th ed. Spain: Elsevier Churchill Livingstone; 2005. p.876-877.
2. Pai MM, Prabhu LV, Nayak SR, Madhyastha S, Vadgaonkar R, Krishnamurthy A et al. The Palmaris Longus Muscle: Its Anatomic Variations and Functional Morphology. Rom J Morphol Embryol. 2008; 49:215-217.
3. Wikipedia contributors. Palmaris Longus Muscle [Internet]. Wikipedia, The Free Encyclopedia; 2014 Feb 6, 03:32 UTC [cited 2014 Feb 11]. Available from: http://en.wikipedia.org/w/index.php?title=Palmaris_longus_muscle&oldid=436049994.
4. Thompson NW, Mockford BJ, Cran GW. Absence of Palmaris Longus Muscle: A Population Study. Ulster Med J. 2001;70(1):22-24.
5. Baral P, Bhattarai C, Poudel PP, Roy S, Banstola D, Shrestha RN et al. Anatomic Variations of Palmaris Longus Muscles in Nepalese. J GMC. 2009; 3(2):39-44.
6. Reimann AF, Daseler EH. The Palmaris Longus Muscle and Tendon. A Study of 1600 Extremities. Anat Rec. 1944;89(4):495-505.
7. Moss A.L.H. Is there an Association Between an absence of Palmaris Longus Tendon and an Absence of Plantaris Tendon? Euro J Plast Surg. 1988; 11(1):32-34.
8. Mobarakeh MK, Pasha MG. Variation, Length and Width of Tendinous Portion of Palmaris Longus and Forearm Length and Height: Is there a link? A Cadaver Study of Adult Iranians. Iran J Med Sci. 2008; 33(3):164-168.
9. Agarwal P. Absence of the Palmaris Longus Tendon in Indian population. Indian J Orthop. 2010; 44(2):212-215.
10. Sebastin SJ, Puhaindran ME. The Prevalence of Absence of the Palmaris Longus—A Study in a Chinese population and a Review of the Literature. Ann Acad Med Singapore. 2006; 35:249-253.

How to cite this article: Magadam A, Dixit D, Bhimalli S. Incidence of absence of palmaris longus in north Karnataka region: a cadaveric study. Int J Health Sci Res. 2014;4(6):37-40.
