

*Case Report***Unilateral Variation of Median Artery with Its Embryological and Clinical Significance: Case Report**

Rajesh. V, Udaya Kumar P, Murali Krishna. S, Kalpana T, Sirisha V, Naveen Kumar B

Department of Anatomy, Mamata Medical College, Khammam, A.P, India.

Corresponding Author: Rajesh. V

*Received: 07/04/2014**Revised: 10/05/2014**Accepted: 15/05/2014***ABSTRACT**

Objective: To document the persistence of median artery and to correlate its clinical significance and embryological development. **Materials and methods:** This case was observed after thorough and meticulous dissection of both forearms of a 70 year old male cadaver in Department of Anatomy at Mamata Medical College, Khammam. **Results:** In the present case the persistent median artery originated from anterior interosseous artery. It was in anterior relation to the median nerve with thickness of 1.8 mm in the carpal tunnel. It did not take part in the formation of superficial palmar arch in the hand. **Conclusion:** With the advent of micro vascular surgery and reconstructive surgeries it is important to recognize and document the developmental variation in course, distribution and branching pattern of the arteries of upper limb. Recognition and documentation of this type of anatomical variation is highly significant during the surgeries of carpal tunnel syndrome.

Key words: persistent median artery, superficial palmar arch

INTRODUCTION

The incidence of variations in the blood vessels of upper limb approximates 11-24% and this can be explained on the basis of development. ^[1]

In the usual course the median artery gets obliterated and supplies the median nerve as vasa nervosum. Superficial palmar arch in the palm is formed by the ulnar artery and completed laterally either by superficial palmar branch of radial artery, arteria princeps pollicis, arteria radialis indicis or arteria nervi mediana. ^[2]

Axis artery of upper limb bud arises from the seventh intersegmental artery. Proximal part of the axis artery develops

into axillary artery while the distal part develops into anterior interosseous artery. Median artery arises from anterior interosseous artery and grows in relation with median nerve. After the obliteration of anterior interosseous artery the capillary plexus in the palm is fed by median artery. During the process of development the median artery gets obliterated and supplies the median nerve but in few cases it persists and takes part in the formation of superficial palmar arch. ^[3]

This implies that abnormal blood vessels in the upper limb can be due to the persistence of blood vessels that normally

get obliterated during the process of development

CASE REPORT

The present variation in the arterial pattern of left upper limb was observed in a seventy year old male cadaver during the course of an undergraduate medical training program at Mamata Medical College, Khammam. The course of the artery was thoroughly traced and the variation was recorded and photographed,

In the present case, persistent median artery was observed in the left upper limb. The artery originated from anterior interosseous artery and was in anterior relation to the median nerve in its course in the forearm until it reached the carpal tunnel. Later it entered the palm by passing below the flexor retinaculum. The thickness of the artery in the carpal tunnel was 1.8mm. In palm it supplied index and middle digits.(Fig 1)

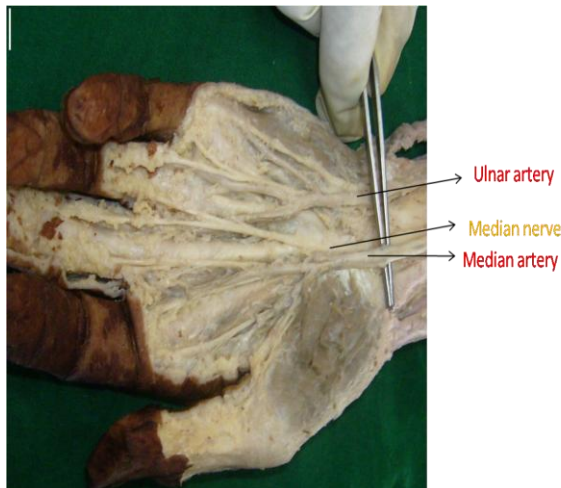


Fig No 1 Showing Persistent Median Artery(1.8mm)

DISCUSSION

Vascular variations of upper extremities are very common but have a lot of clinical and surgical importance. Many cadaveric and angiographic studies have been documented regarding the unusual arterial pattern in the upper limb. Quain et al

for the first time classified the arterial variations in 1844. [4]

Superficial palmar arch is classified into complete and incomplete arch. An arch is said to be incomplete if the vessels forming the arch does not take part in anastomosis. [5] In a cadaveric study done in 650 upper extremities, Coleman S et al reported the incidence of incomplete superficial palmar arch in 21.5% [6] but Ikeda et al observed the incidence to be only 14.2% . [7]

According to Janevskis, et al 2.2% of the persistent median arteries have contributed to the formation of superficial palmar arch [8] and Anitha, et al reported, the incidence to be 6% in a study done in 100 upper limbs. [9] A case report by durgesh et al [10] is similar to our findings but in the present case persistent median artery did not take part in the formation of superficial palmar arch.

Previous studies in the literature described the origin of persistent median artery may be from common interosseous artery, anterior interosseous artery or ulnar artery. Very rarely it takes origin either from brachial artery or radial artery. Varley, et al [11] reported that there is increased risk of ischemia during surgeries if the median artery arises from radial artery. In the present case the artery originated from anterior interosseous artery.

Barfed, et al found persistent median artery during the surgery of carpal tunnel syndrome in nine subjects. [12] According to Zeiss.j, et al persistent median artery is usually asymptomatic but sometimes can cause perfusion of hand [13] and Gassner, et al states that surgeons should be more vigilant if persistent median artery is associated with bifurcated median nerve in the carpal tunnel. [14]

CONCLUSION

This study highlights the presence of unilateral persistent median artery with its embryological and clinical significance. Clinicians, radiologists should be aware of such variant vascular anatomy during hand surgeries and conducting invasive procedures like Allen test, angiography and colour doppler studies. Precise knowledge about persistent median artery and its association with median nerve should be known to the surgeons when evaluating patients with carpal tunnel syndrome.

ACKNOWLEDGEMENTS

Authors acknowledge the immense help received from the scholars whose articles are cited and included in references of this manuscript. The authors are also grateful to authors / editors / publishers of all those articles, journals and books from where the literature for this article has been reviewed and discussed.

Competing interests: The authors declare that we have no competing interests

Ethical committee clearance:

As the study included only human cadavers, ethical committee clearance was not taken into consideration. Authors will take the responsibility of any further allegations regarding ethical clearance that arise from the study.

REFERENCES

1. Uglietta JB, Kadir S. Arteriographic study of variant arterial anatomy of variant arterial anatomy of the upper extremities. *Cardiovasc Intervent Radiol.* 1989; 12: 145–148.
2. Datta AK, Essentials of human anatomy, superior and inferior extremities, 2nd Ed, Calcutta, Current Books International, 2000, 99-100
3. Datta, AK, Essentials of human embryology, 5th Ed, Calcutta, Current Books International, 2005, 195-196
4. Quain R (1844) Anatomy of the Arteries of the Human Body, pp, 235-271. London: Taylor & Walton.
5. Gellman H, Botte MJ, Shankwiler J, Gelberman RH. Arterial patterns of the deep and superficial palmar arches. *Clin Orthop Relat Res.* 2001; 383E: 41–46.
6. Coleman, S.S., Anson, B.J., 1961. Arterian patterns in the hand based upon a study of 650 specimens. *Surg. Gynaecol. Obstet.* 113 (4), 409–424.
7. Ikeda A, Ugawa A, Kazihara Y, Hamada N. Arterial patterns in the hand based on a three-dimensional analysis of 220 cadaver hands. *J Hand Surg.* 1988; 13: 501-509.
8. Janevski BK. Angiography of the upper extremity. The Hague: Martinus Nijhoff 1982; pp.73-122.
9. Anitha T, Kalbande S, Dombe D, Variations in the formation of superficial palmar arch and its clinical significance in hand surgeries, *Int J Biol Med Res,* 2011, 2, 2, 543-6.
10. Durgesh V, Ramanarao R. Persistent median artery. *International Journal of Basic and Applied Medical Sciences.* 2013 Vol. 3 (1) , pp.284-286
11. Varley I, Wales CJ, Carter LM. The median artery: its potential implications for the radial forearm flap. *J Plast Reconstr Aesthet Surg.* 2008;61:693–5.
12. Barfred T, Hojlund Ap, Bertheussen K. Median artery in carpal tunnel syndrome. *J Hand Surgery Am.* 1985; 864-7.
13. Zeiss J, Guillian-Haidet L. MR demonstration of anomalous muscles about the volar aspect of the wrist

and forearm. Clinical Imaging
1996;20:219-21
14. Gassner EM, Schocke M, Peer S,
Schwabegger A, Jaschke W, Bodner
G. Persistent median artery in the

carpal tunnel: Color Doppler
ultrasonographic findings. J
Ultrasound Med 2002; 21:455-61.

How to cite this article: Rajesh V, Kumar UP, Krishna MS et. al. Unilateral variation of median artery with its embryological and clinical significance: case report. Int J Health Sci Res. 2014;4(6):208-211.

International Journal of Health Sciences & Research (IJHSR)

Publish your work in this journal

The International Journal of Health Sciences & Research is a multidisciplinary indexed open access double-blind peer-reviewed international journal that publishes original research articles from all areas of health sciences and allied branches. This monthly journal is characterised by rapid publication of reviews, original research and case reports across all the fields of health sciences. The details of journal are available on its official website (www.ijhsr.org).

Submit your manuscript by email: editor.ijhsr@gmail.com OR editor.ijhsr@yahoo.com