



Case Report

A Rare Case of Traumatic Breast Avulsion

Kshirsagar Ashok, Nangare Nitin, Patankar Ritvij, Pednekar Akshay, Vekariya Mayank, Chincholi Tejas, Gupta Vaibhav

Krishna Institute of Medical Sciences, Karad, Maharashtra, India – 415110

Corresponding Author: Kshirsagar Ashok

Received: 30/04/2014

Revised: 23/05/2014

Accepted: 27/05/2014

ABSTRACT

Introduction: The breast or mammary gland is a distinguishing feature of the class mammalian. Seat belt laws have altered the pattern of chest injuries. Breast injuries are probably more common now because of greater compliance with seat belt laws. Except seat belt traumas, isolated breast traumas are very rare events. Therefore they are interesting cases for general surgery

Case Report: A 50 year old female presented with contused lacerated wound over chest on left side following a mechanical injury by harvester blades. On examination there was near total traumatic avulsion of left breast with penetrating injury to left chest wall causing left sided open pneumothorax. Patient was posted for emergency operative procedure where evidence of fracture left first, fifth, sixth ribs were noted along with left open pneumothorax and left traumatic breast avulsion. Patient underwent left pleural closure with fixation of left 1st rib with left simple mastectomy with left intercostal drain tube insertion.

Conclusion: Isolated breast traumas are rare. Most present with hemorrhage and fat necrosis of the breast. Clinical and radiological features may simulate those of malignant breast disease. In cases of doubt lesions should be biopsied to minimize the chances of missing a malignant lesion. Traumatic breast avulsion is still rarer. The case can be managed with simple mastectomy with thoracic exploration.

Keywords: breast avulsion, trauma, mastectomy

INTRODUCTION

The breast or mammary gland is a distinguishing feature of the class mammalian. From puberty to death the breast is subjected to constant physical and physiological alterations that relate to menses, pregnancy, gestation and menopause. Seat belt laws have altered the pattern of chest injuries with an increased incidence of fractured ribs contrasting with penetrating chest injuries in those not wearing seat belt. Breast injuries are probably more common now because of

greater compliance with seat belt laws. Except seat belt traumas, isolated breast traumas are very rare events. Therefore they are interesting cases for general surgery

CASE REPORT

50 year old female presented with contused lacerated wound over chest on left side following a mechanical injury by harvester blades. There was no history of head injury. On examination there was near total traumatic avulsion of left breast with penetrating injury to left chest wall causing

left sided open pneumothorax (fig 1). Air entry was absent on left side. Blood investigations were within normal limits. Patient was posted for emergency operative procedure where evidence of fracture left first, fifth, sixth ribs were noted along with left open pneumothorax and left traumatic breast avulsion (fig 2). No injury to the lungs was noted. Patient underwent left pleural closure with fixation of left 1st rib with left simple mastectomy with left intercostal drain tube insertion. Post operative period was uneventful. Following development of healthy granulation tissue over chest wound patient underwent split thickness skin grafting. Graft was accepted well and patient was discharged after 21 days with follow up on outpatient department basis (fig 3 & 4).

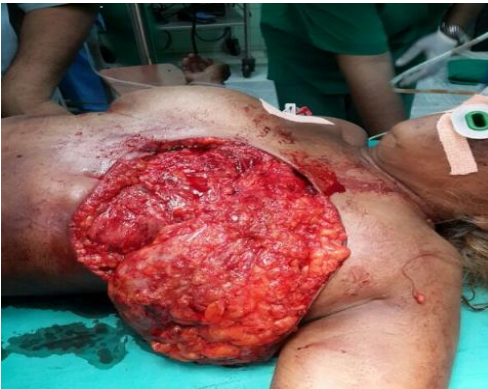

Fig. 1 Traumatic avulsion of left breast.

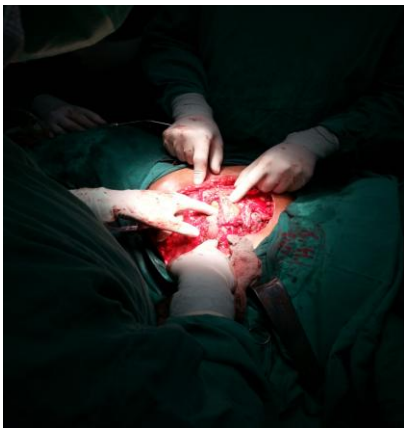


Fig. 2 Intraoperative open pneumothorax with no parenchymal injury.

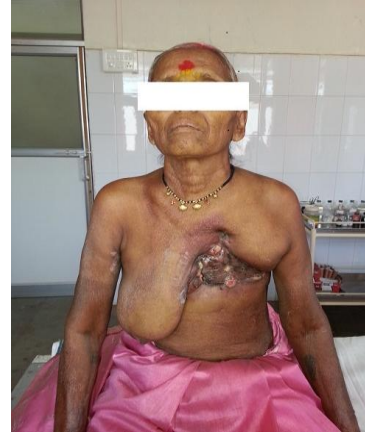

Fig. 3 Post operative.

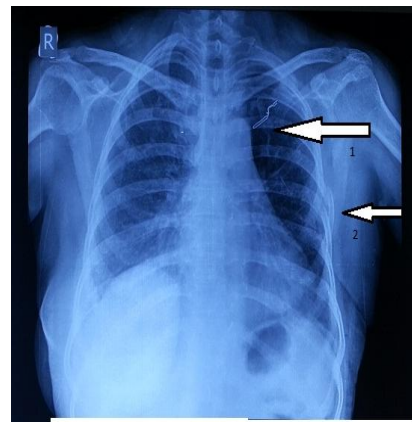


Fig. 4 Postoperative x-ray image (1- 1st rib wiring , 2- fracture 5th & 6th ribs)

DISCUSSION

Isolated breast traumas are rare events, traumatic avulsion being still rarer. Trauma to the breast often lead to the formation of intra glandular hematomas. The abundance of fat tissue in this gland accounts for the relatively high frequency of fat necrosis and self digestion of fat by lipases after traumas i.e fat necrosis, cystosteatonecrosis, lipophagic granuloma. Broadly speaking hematomas are easily diagnosed by both mammography and ultrasonography. However, scarring and formation of lipophagic granulomas due to hemorrhage result in the diagnostic features which are difficult to distinguish from malignant breast nodules. Pignatelly-V et al (1) published 40 patients with breast trauma with a clinically detected nodule or

hematoma with skin retraction or thickening related to trauma. The USG features of these patients at first observation were classified as ; a fluid collection in 12 patients(30%), a solid nodule in 6 patients(15%), a cystic nodule in 10 patients(25%), diffuse parenchymal abnormalities in 4 patients(10%), calcified nodules in 6 patients(15%), and no findings in 2 patients(5%). In their series US guided needle biopsy was performed in 10 patients, 5 patients underwent surgical biopsy, 4 had lipophagic granuloma and the other one had a chronic inflammation.

DioPiro PJ et al ⁽²⁾ published seat belt injuries of the breast in automobile accidents. In his series there were 5 cases and he had examined their sonographic and mammographic findings. In his paper he concluded that mammograms in women with breast injuries caused by seat belts show areas of contusion, lipid cysts and parenchymal calcifications occurring in a band like distribution corresponding to the path of the seat belt shoulder restraints across the chest. As a result he determined that at 1-2 months after breast injury caused by the seat belt, mammograms showed thin-walled fat-density cysts in a linear distribution and inn less dense breast an associated 2-3 cm band of increased density. The band of increased density was not seen in more dense breasts. These findings correlated with the line of contusion across the breast and resultant fat necrosis which ultimately led to the formation of lipid cysts. By 3-4 months after the injury the lipid cysts and contusion were less apparent and a line of fibrosis had developed.

We did not come across any literature regarding traumatic avulsion of the breast with open pneumothorax which itself is a rare event. The affected breast underwent excision of left breast with closure of the pleura and fixation of the fracture rib. There was no evidence of any

lung injury. Also no trauma was noticed to the other breast. Regular dressings helped develop healthy granulation tissue over the chest wall which was later covered by a split thickness skin graft. Post-operative recovery was uneventful.

Chaves-LR et al ⁽³⁾ described trauma as a risk factor for breast cancer, but the simple conclusion that trauma caused the cancer is not substantial by experimental evidence. Single episode of trauma produce carcinoma in animal models only when a potent topical carcinogen is also applied. ⁽⁴⁾ These cutaneous tumors occurred in only 13% of the subjects. In one of the publishings of the seat belt breast injuries adenocarcinoma with trauma was noted in 3 of the 5 patients. ⁽⁵⁾ But they describe that the carcinoma of the breast and road traffic accidents are common coincidence is the likeliest explanation for their findings i.e. trauma was sustained by a breast which harboured pre-existing carcinoma.

CONCLUSION

In conclusion, trauma to the breast can produce lesions which cannot be distinguished from malignant lesions by clinical examination or radiological imaging. If we have any suspicion, all such lesions should be biopsied to minimize the risk of missing a carcinoma. In case avulsion, simple mastectomy can be performed. However, thoracic cavity should be explored well for any pleural or lung trauma. Chest wall can be covered either by free rotation flaps or split thickness skin grafts as per individual case.

ACKNOWLEDGEMENT

We are thankful to Mrs. M.C. Deshingkar from Surgery Dept. Office for her secretarial help.

Conflicts of interest statement: None.

Funding: None.

Consent: Written informed consent was obtained from the patient for publication of this case report and accompanying images.

REFERENCES

1. Pignatelli-V, Basolo-F, Bagnolesi-A, Cartei-F, Grassi-L. Hematoma and fat necrosis of the breast: mammographic and echo graphic features. Radiol-Med-Torino. 1995 Jan-Feb; 89 (1,2); 36-41
2. Dio-Piro-PJ. Meyer-JE, Frenna-TH. Seat belt injuries of the breast; findings on mammography and sonography. AJR-Am-J-Roentgenol. 1995. Feb. 164(2), 317-20.
3. Chaves-LR, Hubbell-FA, McMullin-JM, Understanding knowledge and attitudes about breast cancer. A cultural analysis. Arch-Fam-Me. 1995 Feb 4(2), 145-52.
4. Bonser GM. Aetiology of carcinoma of the breast. Hosp Med 1968; 2; 390-6
5. Dawes R.F.H, Smallwood J.A , Taylor I. , seat belt injury to the female breast. Br. J. Surg. 1986, Vol. 73 Feb, 106-107.

How to cite this article: Ashok K, Nitin N, Ritvij P et. al. A rare case of traumatic breast avulsion. Int J Health Sci Res. 2014;4(6):200-203.

International Journal of Health Sciences & Research (IJHSR)

Publish your work in this journal

The International Journal of Health Sciences & Research is a multidisciplinary indexed open access double-blind peer-reviewed international journal that publishes original research articles from all areas of health sciences and allied branches. This monthly journal is characterised by rapid publication of reviews, original research and case reports across all the fields of health sciences. The details of journal are available on its official website (www.ijhsr.org).

Submit your manuscript by email: editor.ijhsr@gmail.com OR editor.ijhsr@yahoo.com