



Original Research Article

## Anatomical Variations in the Arterial Supply of the Suprarenal Gland

Sushma R.K<sup>1</sup>, Mahesh Dhoot<sup>2</sup>, Hemant Ashish Harode<sup>2</sup>, Antony Sylvan D'Souza<sup>3</sup>, Mamatha H<sup>4</sup>

<sup>1</sup>Lecturer, <sup>2</sup>Postgraduate, <sup>3</sup>Professor & Head, <sup>4</sup>Assistant Professor;  
Department of Anatomy, Kasturba Medical College, Manipal University, Manipal-576104, Karnataka, India.

Corresponding Author: Mamatha H

Received: 29/03/2014

Revised: 17/04/2014

Accepted: 21/04/2014

### ABSTRACT

**Introduction:** Suprarenal gland is normally supplied by superior, middle and inferior suprarenal arteries which are the branches of inferior phrenic, abdominal aorta and renal artery respectively. However the arterial supply of the suprarenal gland may show variations. Therefore a study was conducted to find the variations in the arterial supply of Suprarenal Gland. **Materials and methods:** 20 Formalin fixed cadavers, were dissected bilaterally in the department of Anatomy, Kasturba Medical College, Manipal to study the arterial supply of the suprarenal gland, which were photographed and different variations were noted. **Results:** Out of 20 cadavers variations were observed in five cases in the arterial pattern of supra renal gland. We found that in one cadaver superior supra renal artery on the left side was arising directly from the coeliac trunk. Another variation was observed on the right side in a cadaver that inferior and middle suprarenal arteries were arising from accessory renal artery and on the right side it gave another small branch to the gland. **Conclusion:** Variations in the arterial pattern of suprarenal gland are significant for radiological and surgical interventions.

**KEY WORDS:** Suprarenal gland, suprarenal artery, renal artery, abdominal aorta, inferior phrenic artery

### INTRODUCTION

Suprarenal gland is highly vascular and receives blood flow about 5ml per minute. The required demand is supplied by superior, middle and inferior suprarenal arteries.

Superior suprarenal artery (SSA) usually arises from inferior phrenic artery (IPA), a branch of abdominal aorta (AA). Middle suprarenal artery (MSA) arises from the lateral aspect of AA at the level of superior mesenteric artery. Inferior suprarenal artery (ISA) arises usually from the renal artery (RA) but occasionally from

accessory renal arteries (ARA). However variations in the arterial architecture of the suprarenal gland are common. <sup>[1]</sup> Knowledge of these variations is required as preoperative vascular evaluation is mandatory during surgical and radiological interventions of the abdomen. <sup>[2-4]</sup> Therefore, it is essential to have a vivid knowledge of the normal and anomalous arterial pattern of the suprarenal gland to avoid complications during surgical intervention.

The present study was therefore undertaken to study the arterial supply of the suprarenal gland and its possible variations

which may provide an exact and accurate definition of the origin of the glandular arteries and provide a reliable basis for the selective angiographic technical approach and surgical interventions.

## MATERIALS AND METHODS

20 Formalin fixed cadavers of age ranging from 45 to 60, were dissected bilaterally in the department of Anatomy, Kasturba Medical College, Manipal to study the arterial supply of the suprarenal gland. The arteries were painted and photographed. The variations in the arterial pattern were noted and tabulated.

## RESULTS

Out of 20 cadavers i.e., 40 cases, variations were observed in 7 cases (2 bilaterally) in the arterial pattern of the suprarenal gland. The rest showed the normal arterial pattern [table 1].

**Table 1:** Variations in the branching pattern of the suprarenal arteries.

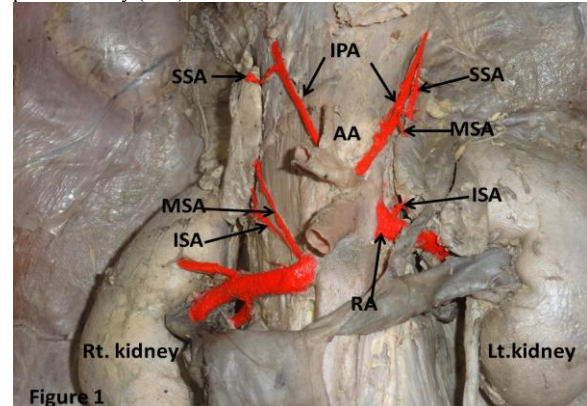
	Right Side	Left Side
SSA	20 (100%) cases from IPA	20 (100%) cases from IPA
MSA	15(80%) cases from AA	18(90%) cases from AA
	2(10%) cases from RA	1(5%) case from IPA
	1(5%) case from ARA	1(5%) case from CT
	2 (5%) case from IPA	
ISA	17(90%) cases from RA	18(90%) cases from RA
	1(5%) case from ARA	2(10%) cases from ARA
	2 (5%) case from IPA	

Case 1: On the right side, the MSA was arising from the RA and on the left side from the IPA (Figure 1).

Case 2: On the right side, MSA and ISA were arising from ARA while on the Left side the MSA was arising from the coeliac trunk & ISA from ARA (Figure 2).

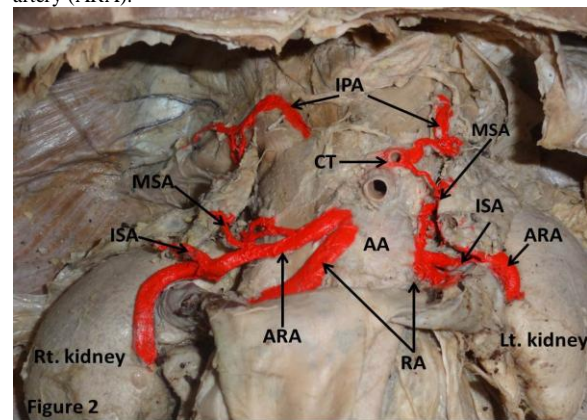
Case 3: On the Left side, 2 to 3 small twigs of the MSA were arising from the AA while ISA was a branch of the ARA. The SSA was however normally arising from the IPA. Normal arterial pattern was observed on the right side (Figure 3).

**Figure 1:** Showing the Middle suprarenal artery (MSA) arising from renal artery (RA) on the right side and from the inferior phrenic artery (IPA) on the left.

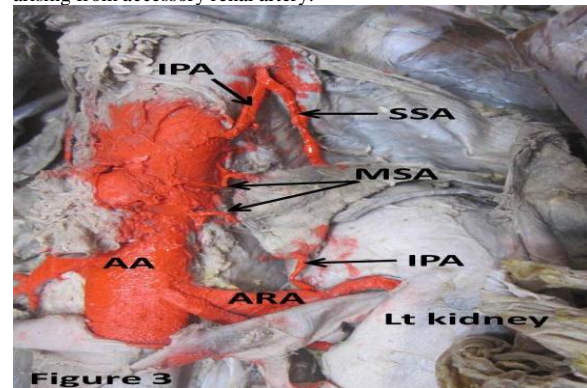


AA: Abdominal aorta, SSA: Superior suprarenal artery, ISA: Inferior suprarenal artery.

**Figure 2:** Showing the Middle (MSA) & inferior suprarenal (ISA) arteries arising from accessory renal artery (ARA) on the right side. In the left side, the Middle suprarenal artery was arising from Coeliac Trunk & Inferior suprarenal artery from accessory renal artery (ARA).



**Figure 3:** Left side showing 2 to 3 small branches of MSA arising from the abdominal aorta while Inferior supra renal artery was arising from accessory renal artery.

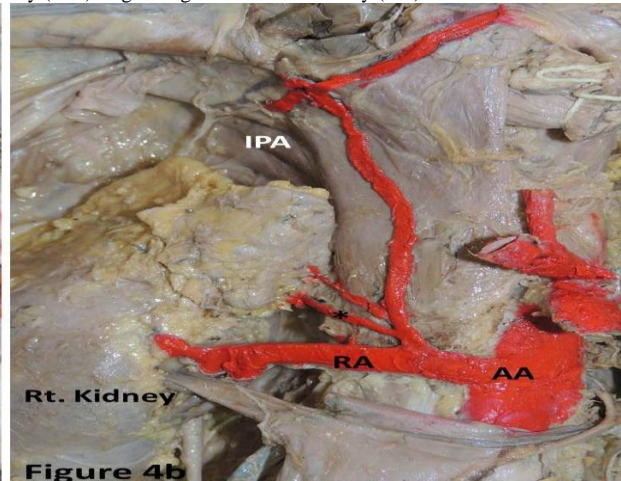
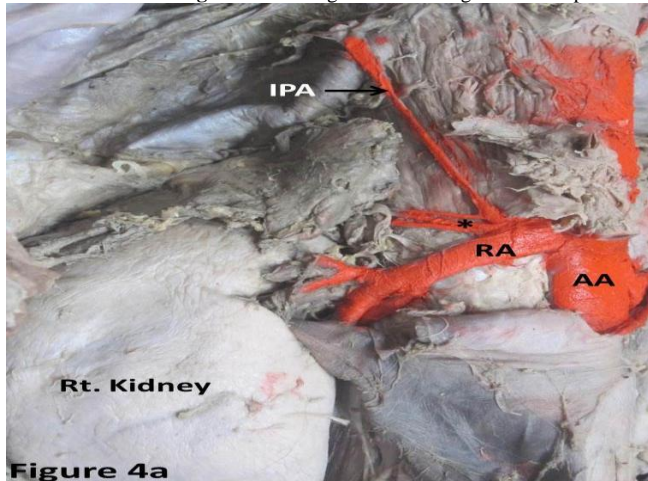


Case 4: Right side showed the IPA originating from the RA. The suprarenal

gland was entirely supplied by branches arising from the junction between the RA and IPA. The arterial pattern was normal when observed on the left side (Figure 4a).

Case 5: On the right side, the IPA was arising from the RA. The arterial supply of the suprarenal gland was provided by twigs arising from IPA. Normal arterial pattern was observed on the left side (Figure 4b).

**Figure 4a & b:** Right side showing the inferior phrenic artery (IPA) originating from the renal artery (RA).



**Figure 4a**

**Figure 4b**

**Figure 4a:** The suprarenal gland is supplied by twigs (\*) arising at the junction between the renal and inferior phrenic artery. **Figure 4b:** All the arterial twigs to the suprarenal gland are (\*) arising from the IPA.

## DISCUSSION

The blood supply of the suprarenal gland presents a complexity. The arteries supplying the gland show variability in their position and origin. [5,6]

Embryologically the formation of the blood vessels is attributed to vasculogenesis and angiogenesis. However, intussusceptive microvascular growth and intussusceptive arborization are responsible for vascular growth and remodelling. [7]

Arterial supply of the kidneys, adrenal glands and gonads are derived from rete arteriosum urogenitale, which is formed by lateral splanchnic branches of dorsal aorta. [8]

Earlier it was stated that there are approximately nine such lateral mesonephric arteries which are divided into cranial, middle and caudal groups. The cranial group comprises of first and second arteries passing dorsal to adrenal body; middle group with third, fourth and fifth arteries passing through adrenal bodies of respective

side; and caudal group with sixth, seventh, eighth and ninth arteries which remain ventral to adrenal bodies. These arteries normally disappear in caudal direction except those supplying kidneys, gonads, and suprarenal glands. [9] Persistence of one such anomalous branch may be responsible for the variable origin of the suprarenal arteries. Certain factors like growth, hemodynamics, genetic factors and teratogenicity of the chemical reagents may also influence the aberrant origin of the arteries. [1]

SSA usually arises from the IPA which in turn is a branch of the AA. Studies have also reported anomalous origin of SSA directly from AA and splenic artery. [1] The IPAs may also show a variant origin. They normally originate from the AA and CT and sometimes may even arise from the RA. Various other sites of origin include the left gastric, hepatic, superior mesenteric, spermatic, and suprarenal arteries. [10]

In the present study SSA was arising from the IPA. The latter was observed as a



branch of AA in majority of the cases. But two cases presented the IPA originating from the renal artery and all the arterial twigs to the suprarenal gland were entirely arising from the IPA.

The IPA is the most common source of extra-hepatic collateral blood supply and may also be associated with various pathologies like hepatocellular carcinoma, hemoptysis, diaphragmatic or hepatic bleeding due to trauma or surgery, and bleeding caused by gastroesophageal problems. [10] Therefore radiologists must be familiar with the arterial pattern of the IPA and its branches so that the pathologic conditions related to the IPA can be adequately managed.

MSA normally arises from the AA. It can also originate from the IPA, CT, RA, ARA lumbar and gonadal arteries. [3] The MSA may sometimes provide a testicular artery, more frequently on the left than on the right side. [11]

In a study, the arterial origin of MSA when studied indicated 7% from the coeliac trunk and its branches and 3% from the superior mesenteric artery. Additionally one case showed the emergence of MSA from the lumbar artery on the left side. [12] In an angiographic review of 100 cases, Toni and his co-workers stated that on the left side MSA was provided by the AA, in 99% and 1% from coeliac trunk, while on the right side, the MSA originated in 91% of cases from the aorta, 4% from the coeliac trunk, 3% from the inferior phrenic artery and 2% from the renal artery. [13]

The MSA originating from the renal artery was the rarest pattern in the above study. The present study on the other hand reports two cases on the right side showing the MSA arising from the RA. The present study also reports the origin of the MSA from the IPA which in turn was a branch of the RA.

MSA plays an important role in the supply of the gland, [14] and thus it becomes necessary to be acquainted with the variations in its origin, distribution and branching both clinically and surgically.

The ISA although is a branch of the RA can also arise from the AA, ARA, Gonadal artery and rarely from the coeliac trunk. [1] Present study also revealed ISA arising from ARA in addition to its normal origin. Additionally, ISA arising from the IPA was also identified.

Manso & DiDio (2000) studied 30 pairs of suprarenal glands, with four inferior suprarenal arteries (1.6%) supplying a single gland. [3] Bordei et al. (2003) described three inferior suprarenal arteries in 6.6% of their cases. A common arterial trunk which further trifurcated into middle and inferior suprarenal arteries and a renal artery was also reported. [15] Brohiet al. (2001) reported a case of high origin of the left testicular artery from the aorta which in turn provided a suprarenal branch. There were no arterial twigs to the suprarenal arising from the renal artery. The SSA and MSA however had normal origin. [11]

In the present study, ISA mainly arose from the RA in majority of the cases. However branches from the ARA and IPA have also been identified.

According to Rossi (1968) and Rossi et al. (1979), arteriograms of the ISA are imperative in the identification of tumors of the gland. However the calibre, multiplicity and variations of the arteries pose a major problem in the arteriography of the suprarenal gland. [16, 17]

Exact and accurate definition of the anatomo-angiography of the origin of the glandular arteries as an aortographic presentation provides a reliable basis for the selective angiographic technical approach. [18] Moreover, since the gland has a particular anatomical specialty, it is important in surgical intervention to the

retroperitoneal space. Because of the close relation between the gland and the aorta and its various branches, anatomical problems may be encountered particularly during the modern organ transplant techniques such as kidney and liver transplantations due to unfamiliar arteries in the operative field.

Surgery of the suprarenal gland also requires detailed recognition of its various arterial sources since the organ has no arterial hiatus of its own and is encircled by arteries originating from the abdominal aorta and its various branches. Considering these vessels give origin to the arteries that supply the gland it should be taken into account to prevent possible accidental injury during the surgical interventions. <sup>[17]</sup>

## CONCLUSION

The study therefore suggests that a detailed awareness of the arterial anatomy of the suprarenal gland is essential for preoperative vascular evaluation and surgical interventions of upper abdominal organs to avoid complications.

## REFERENCES

1. S. Dutta. Suprarenal gland–arterial supply: an embryological basis and applied importance. *Romanian Journal of Morphology and Embryology* 2010; 51(1):137–140
2. Miekos E, Anatomical basis of radiodiagnosis of the adrenal gland, *IntUrolNephrol.* 1979; 11(3):193–200.
3. Manso JC, Didio LJ, Anatomical variations of the human suprarenal arteries, *Ann Anat.* 2000; 182(5):483–488
4. Toni R, Mosca S, Favero L, Ricci S, Roversir, Toni G, Vezzadini P, Clinical anatomy of the suprarenal arteries: a quantitative approach by aortography, *SurgRadiol Anat.* 1988;10(4):297–302.
5. Gagnon R, The arterial supply of the human adrenal gland, *Rev Can Biol.* 1957; 6(4):421–433.
6. Merklin RJ, Arterial supply of the suprarenal gland, *Anat Rec.* 2005; 144(4):359–371.
7. Djonov V, Schmid M, Tschanz SA, Burri PH, Intussusceptive angiogenesis: its role in embryonic vascular network formation, *Circ Res.* 2000, 86(3):286–292.
8. Larsen WJ, Sherman LS, Potter SS, Scott WJ, *Human Embryology*, 3rd edition, Elsevier Health Sciences. 2001; 201.
9. Felix W, Mesonephric arteries (amesonephricae). In: Keibel F, Mall FP (eds), *Manual of Human Embryology*, 2<sup>nd</sup> edition, Lippincott, Philadelphia. 1912; 820–825.
10. Gwon DI, Ko GY, Yoon HK, Sung KB, Lee JM, Ryu SJ, Seo MH, Shim JC, Lee GJ, Kim HK. Inferior phrenic artery: anatomy, variations, pathologic conditions, and interventional management. *Radiographics.* 2007;27(3):687–705.
11. Brohi RA, Sargon MF, Yener N, High origin and unusual suprarenal branch of a testicular artery, *SurgRadiol Anat.* 2001; 23(3):207–208
12. Gagnon R. Middle suprarenal arteries in man: a statistical study of 200 human adrenal glands. *Rev.Can. Biol.* 1964; 23: 461–467.
13. Toni, R., Mosca, S., Favero, L., Ricci, S., Roversi, R., Toni, G., Vezzadini, P., Clinical anatomy of the suprarenal arteries: a quantitative approach by aortography. *Surg. Radiol. Anat.* 1988; 10: 297–302.
14. Mehmet C, Erdil FH, Kosar MI, Sabanciogullari V. A rare variation of the right middle suprarenal artery. *Ann Anat.* 2007;189 : 287—289

15. Bordei P, Antohe D St., Sapte E, Iliescu D. Morphological aspects of the inferior suprarenal artery. Surg. Radiol. Anat. 2003; 25: 247–251.
16. Rossi P. Arteriography in adrenal tumours. Brit J Radiol. 1968;41:81–82
17. Rossi P, Passariello R, Simonetti G, Rovighi L, Grecco M. Arterious (sic) and venous system of the adrenal glands: Anatomical considerations. Ann Radiol. 1979; 22:372–377
18. Kahn PC, Nickrosz LV. Selective angiography of the adrenal glands. Am. J. Roentgenol. 1967;101:739–749.

How to cite this article: Sushma R.K, Dhoot M, Harode HA et. al. Anatomical variations in the arterial supply of the suprarenal gland. Int J Health Sci Res. 2014;4(5):31-36.

\*\*\*\*\*

**International Journal of Health Sciences & Research (IJHSR)**

**Publish your work in this journal**

The International Journal of Health Sciences & Research is a multidisciplinary indexed open access double-blind peer-reviewed international journal that publishes original research articles from all areas of health sciences and allied branches. This monthly journal is characterised by rapid publication of reviews, original research and case reports across all the fields of health sciences. The details of journal are available on its official website ([www.ijhsr.org](http://www.ijhsr.org)).

Submit your manuscript by email: [editor.ijhsr@gmail.com](mailto:editor.ijhsr@gmail.com) OR [editor.ijhsr@yahoo.com](mailto:editor.ijhsr@yahoo.com)