



Case Report

## Accessory Right Hepatic Artery Compensating Rudimentary Right Branch of Hepatic Artery Proper - A Case Report

Naveen Kumar, Swamy Ravindra S, Prakashchandra Shetty, Satheesha B Nayak, Jyothsna Patil, Surekha D Shetty, Anitha Guru

Department of Anatomy, Melaka Manipal Medical College (Manipal Campus), Manipal University, Manipal, Karnataka, INDIA.

Corresponding Author: Swamy Ravindra S

Received: 25/03/2014

Revised: 14/04/2014

Accepted: 15/04/2014

### ABSTRACT

Replaced right hepatic artery and accessory right hepatic artery (ARHA) are the rare form of variant hepatic arterial system. During routine dissection of abdominal cavity, we observed an ARHA arising from the proximal part of superior mesenteric artery. This anomalous artery was found to be compensating the nutritional source of the right lobe of the liver which might have been deprived due to rudimentary right branch of hepatic artery proper. In addition to this, the AHA was also supplying the gall bladder and cystic duct through its cystic branches. Presence of ARHA in addition to original right branch of the hepatic artery proper may get unnoticed by the surgeons or therapeutic radiologists leading to serious complications following its iatrogenic injury. Therefore, ascertaining the presence or absence of ARHA is prerequisite before planning and executing surgical or radiological interventions in this region.

**Keywords:** accessory right hepatic artery, celiac trunk, superior mesenteric artery, right hepatic artery

### INTRODUCTION

Among the branches of celiac trunk, the hepatic arterial system is known to show its variation. The common hepatic artery is one among the major branches of the celiac axis. It usually terminates by dividing into gastroduodenal and hepatic artery proper branches. The latter further ascends upwards within the right free margin of the lesser omentum and enters the porta hepatis of the liver as right and left hepatic branches to supply corresponding physiological lobes of the liver. The right hepatic artery before it supply the liver, it normally gives a cystic branch to gall bladder and its duct. [1]

Occasionally, the right hepatic artery originates from neighbouring arteries and may replace the conventional right hepatic artery. Thus, this artery is called as replaced right hepatic artery. Very rarely right hepatic artery arises as a deviating source of origin from non celiac axis and supply the right lobe of the liver as an additional hepatic artery. Such type of variant vascular channel is known as accessory right hepatic artery or ARHA. [2]

Therapeutic embolization of superior mesenteric artery may jeopardize the liver function by cutting off blood supply through replaced right hepatic artery leading to liver

necrosis. [3] Similarly, existence of ARHA, also may lead to fatal bleeding during surgical approach at the liver due to its damage. Whatever the adverse affect of presence of variant hepatic arterial pattern, frequency of its detection is being increased particularly during the necessity of intrahepatic arteriole vasodilatation in reduced portal flow. [4]

We present here an embryological and clinical perspective of an ARHA originating from superior mesenteric artery, compensating rudimentary right hepatic artery from hepatic artery proper and catering gallbladder and its duct.

The knowledge on aberrant vasculature to the liver before planning and executing any surgical and radiological intervention is important to prevent iatrogenic bleeding or any other inevitable complications.

### CASE REPORT

During routine cadaveric dissection for medical undergraduate students, we observed an accessory right hepatic artery arising from proximal part of superior mesenteric artery, which coursed upward and towards right, anterior to the portal vein, deep to the head of the pancreas and the second part of the duodenum. It then entered the right free margin of lesser omentum, occupying right side of the portal vein and slightly behind the bile duct. Near the fundus of the gall bladder, accessory right hepatic artery trifurcated into two hepatic branches and a cystic branch. Hepatic branches entered the substance of right lobe of the liver at right end of the porta hepatis. The cystic branch further divided and supplied both the surfaces of gallbladder and also to the cystic duct (Fig 01). Origin and branching pattern of celiac trunk was found to be normal. However, the common hepatic artery ended by trifurcating into right gastric, hepatic artery proper and

gastrooduodenal branches. The hepatic artery proper gave right and left hepatic branches, in which the right hepatic branch was remarkably hypoplastic and appeared to be rudimentary (Fig 02). This variant arterial pattern of liver and gall bladder was observed in a formalin embalmed male cadaver aged about 50 years. No other vascular anomalies were noted in the supracolic compartment of the abdominal cavity.

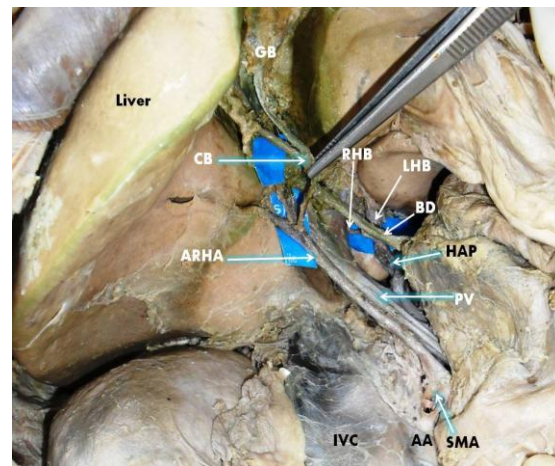


Figure 01: Showing the origin of Accessory hepatic artery (ARHA) from superior mesenteric artery (SMA) on the right side of portal vein (PV), supplying the right lobe of the liver and giving rise to cystic branches (CB) to gall bladder (GB). The hepatic artery proper (HAP) divided into a prominent left hepatic branch (LHB) and a rudimentary right hepatic branch (RHB). BD: bile duct, IVC: inferior vena cava, AA: abdominal aorta.

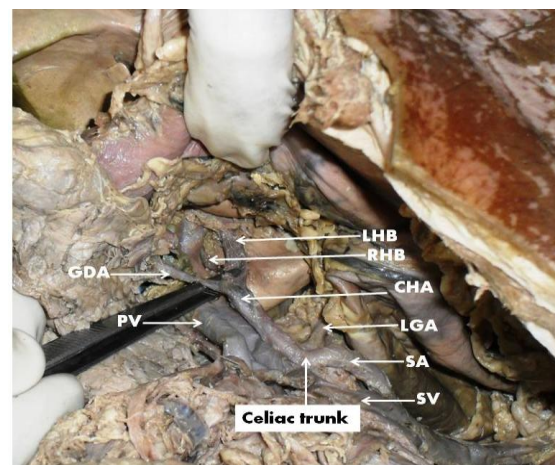


Figure 02: Showing a rudimentary right hepatic branch (RHB) and prominent left hepatic branch (LHB). CHA: common hepatic artery, SA: splenic artery, LGA: left gastric artery, SV: splenic vein, PV: portal vein, GDA: gastrooduodenal artery.

## DISCUSSION

Variant hepatic arteries are not uncommon. Stauffer JA et al. found aberrant right hepatic arterial anatomy (ARHAA) in 16.2% individuals. [5] A study conducted by Ugurel et al., reported the prevalence of hepatic artery variation as 48%. [6] Accessory right hepatic artery originating from the superior mesenteric artery as present in our case is considered as Type VI and Type III of hepatic artery variation according to Michels classification and Hiatt classification respectively. [7, 8] Bordei and Antohe's study on 60 human fetuses found a case with separate origin of all the three branches of coeliac trunk from the aorta. [9] Bordei and Antohe). Nayak SB et al. reported about accessory hepatic artery which took origin from the superior mesenteric artery supplying the liver in addition to the hepatic artery proper. The hepatic artery proper in that case gave rise to a cystic branch and entered undivided in the porta hepatis. [10] Srinivasa Rao et al. reported a similar case of arterial variation with the hepatic artery proper (right hepatic artery) dividing into smaller branches before entering into porta hepatis of liver. However, in the report authors did not mention about the origin of cystic artery. [11] Johnson et al. reported a case in which the left hepatic artery took origin from the common hepatic artery and the right hepatic artery took origin from the gastroduodenal artery behind the pancreatic head. [12] A case of replaced right hepatic artery arising from superior mesenteric artery was reported by Satheesha et al. [13]

In the present case the accessory hepatic artery trifurcated into two hepatic branches and a cystic branch. Hepatic branches from the accessory hepatic artery entered the substance of right lobe of the liver at right end of the porta hepatis. Cystic branch from the accessory hepatic artery divided into 2 branches to supply gall

bladder and its duct (Fig 01). The hepatic artery proper gave right and left hepatic branches, in which the right hepatic branch was hypoplastic and appeared to be rudimentary, thus making the present vascular variation different from other reported cases (Fig 02).

The aorta during embryonic development gives off four ventral segments which become the celiac, splenic, common hepatic and superior mesenteric arteries. These four ventral segment arteries anastomose with a longitudinal ventral artery. A persistent part of the longitudinal ventral arterial segment connected to the superior mesenteric artery leads to the formation of accessory right hepatic artery. [14]

During pancreaticoduodenectomy, anomalies of the right hepatic artery are important and their recognition is necessary to protect the blood supply to the liver and bile ducts. [5] It is mandatory to have a preoperative knowledge of anatomic hepatic vascular variations for surgical planning and to reduce postoperative complications of hepatic surgery. [15] Thus surgeons doing liver transplants, laparoscopic surgery, pancreatic mobilizations, gastrojejunostomies, radiological abdominal interventions by radiologists and surgeon attending penetrating injuries to the abdomen should be aware of variations of accessory hepatic arteries to avoid inadvertent or iatrogenic hepatic vascular injury. Further, careful look for the presence of accessory hepatic artery, its course and branching pattern makes it obligatory when there is a remarkably thinner hepatic branches.

## REFERENCES

1. Standring S; Gray's anatomy: The Anatomical basis of clinical practice, 39th Ed. Elsevier Churchill living stone;2005, pp-1214-1215

2. Weiglein AH. Variations and topography of the arteries in the lesser omentum in humans. *Clin Anat* 1996; 9(3):143–150.
3. Barakate MS, Cappe I, Curtin A, Engel KD, Li-Kim-Moy J, Poon MS, Sandeman MD. Management of acute superior mesenteric artery occlusion. *ANZ J Surg* 2002; 72(1):25-29.
4. Ayse Erden, Erbu Dusunceli, Evren Ustuner, Yasemin Genc. The significance of the right hepatic artery originating from the superior mesenteric artery in patients with cavernous transformation of the portal vein. *Diagn Interv Radiol* 2009; 15:31–35
5. Stauffer JA, Bridges MD, Turan N, Nguyen JH, Martin JK. Aberrant right hepatic arterial anatomy and pancreaticoduodenectomy: recognition, prevalence and management. *HPB (Oxford)*. 2009 Mar;11(2):161-5.
6. Ugurel MS1, Battal B, Bozlar U, Nural MS, Tasar M, Ors F, Saglam M, Karademir I. Anatomical variations of hepatic arterial system, coeliac trunk and renal arteries: an analysis with multidetector CT angiography. *Br J Radiol*. 2010 Aug;83(992):661-7.
7. Michels NA. Newer anatomy of the liver and its variant blood supply and collateral circulation. *Am J Surg* 1966;112:337–47.
8. Hiatt JR, Gabbay J, Busuttil RW. Surgical anatomy of the hepatic arteries in 1000 cases. *Ann Surg* 1994;220:50–2.
9. Bordei P, Antohe DS. Variations of the celiac trunk branches in the fetus. *Morphologie*. 2002 Sep;86(274):43-7.
10. Nayak SB, Ashwini LS, Swamy Ravindra S, Abhinitha P, Sapna Marpalli, Jyothsna Patil, Ashwini Aithal P. Surgically important accessory hepatic artery – A case report. *J. Morphol. Sci.*, 2012; 29(3):1-2.
11. Srinivasarao Y, Thirupathi Rao V, Polavarapu S. An accessory right hepatic artery arising from superior mesenteric artery and its clinical significance. *Int J Anat Res*.2013;01:11-14.
12. Johnson PB, Cawich SO, Shah S, Gardner MT, Roberts P, Stedman B, Pearce NW. Vascular supply to the liver: a report of a rare arterial variant. *Case Rep Radiol*. 2013;2013:3.
13. Satheesha NB, Srinivasa RS, Surekha DS, Naveen K, Anita G. Replaced Right Hepatic Artery Associated with Uncommon Triplet Right Renal Vein: Embryological Perspective and Clinical Importance. *Journal of Surgical Academia* 2012; 2(2):45-48
14. Langman J. *Medical embryology*, 6th ed. Baltimore, Philadelphia, MD, USA: Lippincott Williams & Wilkins 1975; 282-90.
15. Catalano OA, Singh AH, Uppot RN, Hahn PF, Ferrone CR, Sahani DV. Vascular and biliary variants in the liver: implications for liver surgery. *Radiographics*. 2008 Mar-Apr;28(2): 359-78.

How to cite this article: Kumar N, Swamy RS, Shetty P et. al. Accessory right hepatic artery compensating rudimentary right branch of hepatic artery proper - a case report. *Int J Health Sci Res*. 2014;4(5):331-334.

\*\*\*\*\*