



Case Report

Parietal Abdominal Wall Swelling Turning Out To Be a Parietal Complication of Hydatid Cyst of Liver - A Case Report

Niraj B. Singh¹, Anjali M. Chitale², Vinay Kumar Yadav¹

¹P.G.3rd Year, ²Professor,
Department of General Surgery, ACPM Medical College & Hospital, Sakri Road, Dhule - 424001.

Corresponding Author: Niraj B. Singh

Received: 09/01/2014

Revised: 03/02/2014

Accepted: 07/02/2014

ABSTRACT

Hydatid cyst is the disease of liver and lungs, but this disease may occur in any part of world and anywhere in the body. This report presents hydatid cyst located in the liver which presented as a superficial parietal abdominal wall swelling.

A 65 year old female patient from central Dhule district of Maharashtra came with chief complaints of a painless mass in the Right hypochondriac region since 10 years, gradually increasing in size. Clinically it seemed to be a parietal abdominal wall swelling but ultrasound revealed lesion to be a hydatid cyst of the liver which had herniated out through the abdominal wall in spite of there being no evidence any abdominal wall defect congenital / acquired at the site of presentation. Hydatid cyst of the liver can with / without getting ruptured spread to various structures around the liver.

Spread of hydatid cyst of liver to the adjacent abdominal wall is called as "The Parietal complication" of this disease, which are 1) subcutaneous rupture of the cyst and 2) spontaneous cysto-cutaneous fistula of liver hydatid cyst. There have been reports published of cases with spontaneous subcutaneous rupture of hydatid cyst of liver, hydatid cyst of liver presenting as cysto-cutaneous fistula and previously operated hydatid cyst of liver with abdominal wall recurrence, but case reports with intact hydatid cyst of liver presenting as a superficial parietal abdominal wall swelling has not yet been reported.

Parietal complications of hydatid cyst of the liver are extremely rare. The diagnosis is usually established by USG and CT-scan.

In our case patient had a hydatid cyst of liver, which herniated out of abdomen inspite of no history of any trauma or surgery in past. The swelling was not having any discharge, nor had it ruptured in the subcutaneous space. Our case an "Intact Hydatid cyst of liver herniated through a normal abdominal wall" is, to the best of our knowledge, the 1st case reported of this kind.

Key words: Hydatid cyst, parietal complication, Liver, Abdominal wall

INTRODUCTION

Echinococcosis (hydatid disease) is a zoonosis caused by the larval stage of *Echinococcus granulosus* (also known as *Taenia echinococcus*). Humans are

accidental intermediate hosts, whereas animals can be both intermediate hosts and definitive hosts. The two main types of hydatid disease are caused by *E. granulosus* and *E. multilocularis*. The former is

commonly seen in the Mediterranean, South America, the Middle East, Australia, and New Zealand, and is the most common type of hydatid disease in humans.^[1] In humans, 50–75% of the cysts occur in the liver, 25% are located in the lungs, and 5–10% distribute along the arterial system. Infection with echinococcal organisms is the most common cause of liver cysts in the world.^[1]

CASE REPORT

A 65 yr old female patient presented with a large painless lump on the abdominal wall- Rt. Upper Quadrant, since 10 yrs. Initially small gradually increasing in size to the size of an orange.

No history of vomiting/ abdominal pain / constipation/ jaundice, otherwise asymptomatic. No history of any surgery in past.

On Examination: A 12 cm x 15 cm globular mass in the Right Hypochondriac region. Mass firm in consistency, smooth surface, Non-tender, Non-fluctuant, not fixed to overlying skin but fixed to abdominal wall, no cough impulse, no evidence of scar over the swelling, no jaundice. Clinically: ? Huge Lipoma of abdominal wall.

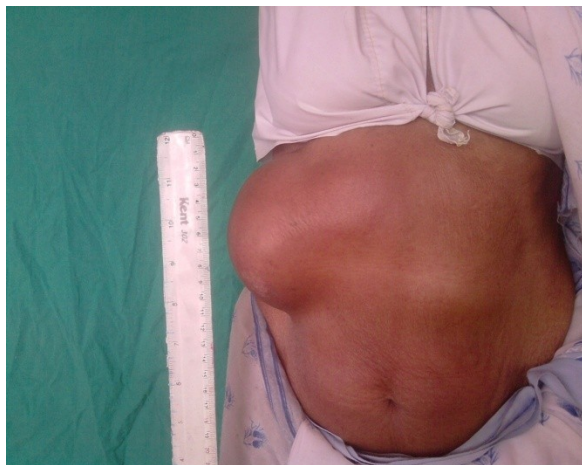

Figure 1 . Swelling seen from anterior view.

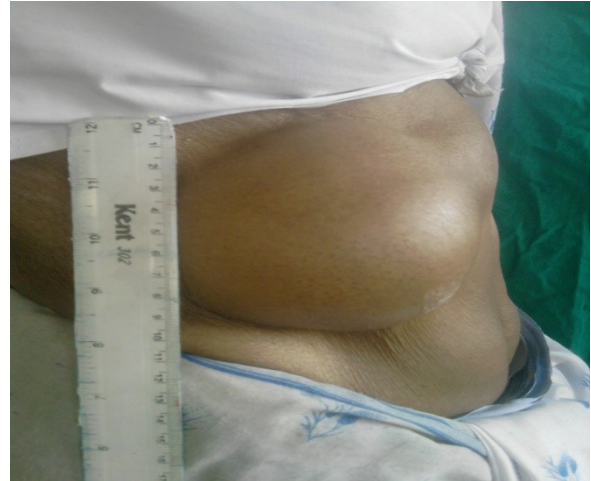

Figure 2. Swelling seen from Lateral view.

On investigation: All routine hematological investigations were within normal limits. Clinical examination was suspicious of it being of a simple lipoma. X- ray abdomen standing was done which showed a mass with egg shell calcification below the xiphisternum.

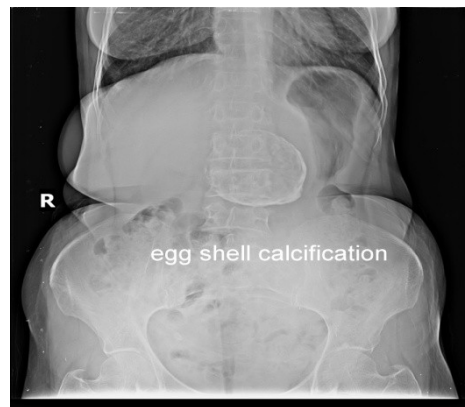

Figure 3. X-ray abdomen showing circumferential calcified lesion in upper abdomen.

Patient was not affording for CT- Abdomen, hence USG- Abdomen was done. USG- ABD surprisingly showed the mass to be a Hydatid Cyst arising from Rt. lobe of liver with calcification. The cyst had three spherical components which were connected to each other, the right one (1st part) was that component which had herniated out of the abdomen, the middle (2nd part) & the left (3rd part) were embedded in the right liver lobe

parenchyma of which the left one (3rd part) was partly coming out of liver parenchyma through the inferior surface and was in mid-line, dead & calcified.

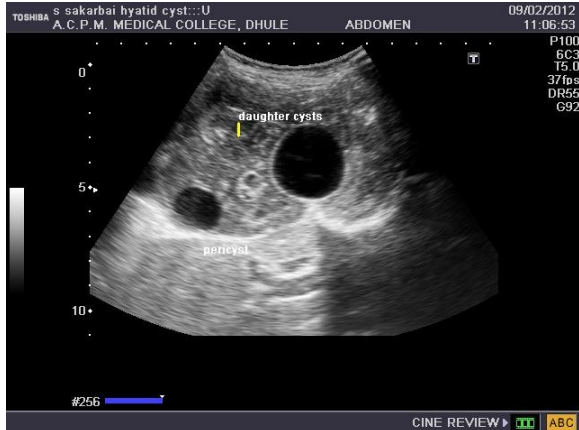


Figure 4. USG showing lesion to be cystic containing thick fluid and multiple cysts inside it's cavity (daughter cysts).

Inner layer of 3rd part of the cyst separated from outer layer and appeared as a serpentine structure inside of the cyst called The Water-lily sign was characteristic of hydatid cyst was seen.

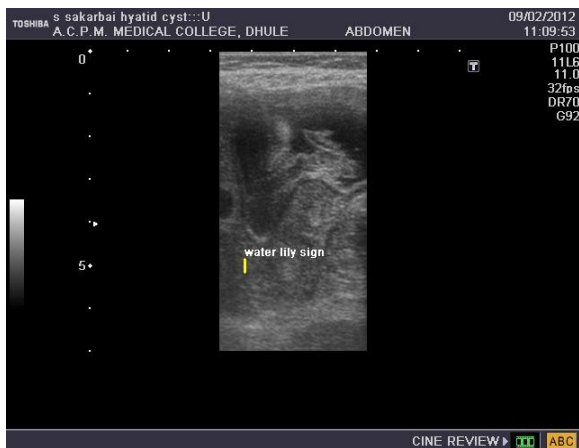

Figure 5. Inner layer of 3rd part separated from outer layer giving classical "Water lily sign" seen in Hydatid cyst.

The 1st & 2nd parts of the cyst contained multiple daughter cyst(scolices) & thick fluid. The right component (1st part) was the part of the cyst that had herniated out of the abdominal wall through the Rt. Hypochondriac region. USG showed the

defect in the abdominal wall through which the cyst had herniated out and also demonstrating the connection between the 1st and 2nd part of the cyst.

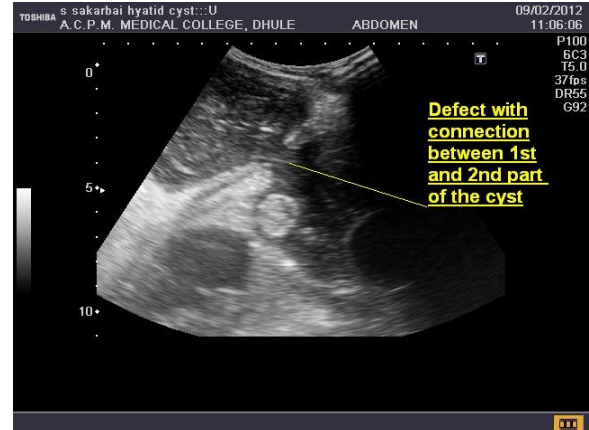


Figure 6. USG showed the defect in the abdominal wall through which the cyst herniated out and also demonstrating the connection between 1st and 2nd part of the cyst.

Treatment: Patient was given albendazole 10 mg/kg/day for 3 weeks, followed by surgery.

Operative findings: During surgery the USG findings were confirmed. The swelling was explored by a dual approach, incision was taken over the swelling & a spherical cystic lump of whitish colour was found deep to the skin and fat. The surrounding area was isolated with packs soaked with Hypertonic saline solution.

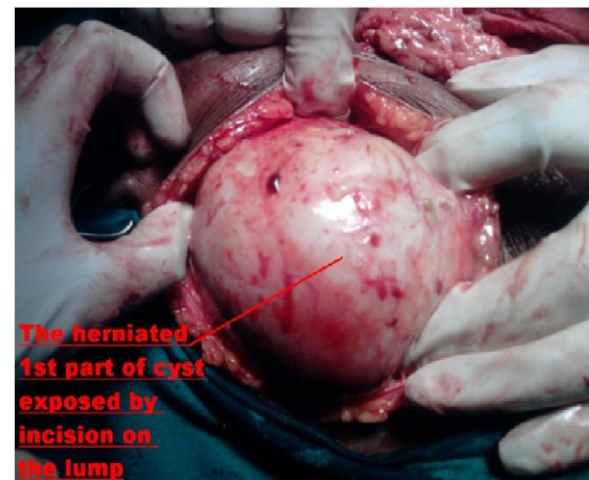


Figure 7. Incision over the swelling revealed the 1st part of the cyst below the subcutaneous fat.

The mass was a herniated part of a single hydatid cyst. Since it was connected to the liver hence could't be removed intact. Under all precautions, preventing spillage of fluid, a stab incision was taken over most prominent part of the cyst. It contained purulent material & numerous daughter cysts, hence the diagnosis was confirmed on exploration to be an infected hydatid cyst.

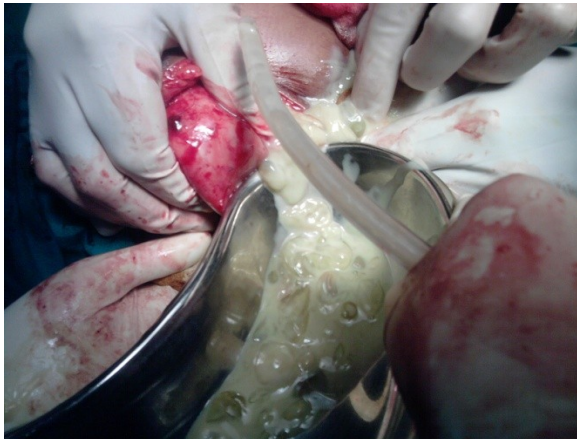


Figure 8. Incision over the swelling expressed purulent fluid with numerous daughter cysts.

Further evacuation of contents showed that the 1st part was connected, through a defect in the abdominal wall, to the middle part (2nd part) of the cyst which was in the right lobe of liver & had same contents.

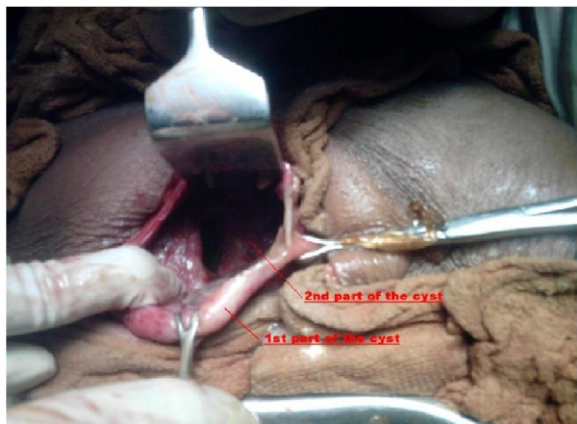

Figure 9. Evacuation of fluid from 1st part revealed the defect in the abdominal wall and the connection of the 1st part through it to the 2nd part.

The empty redundant part of the 1st part was excised with some portion of the 2nd part of the cyst. The middle part was connected to the 3rd part of the cyst which had only pus and membranes but no daughter cysts & was dead & calcified.

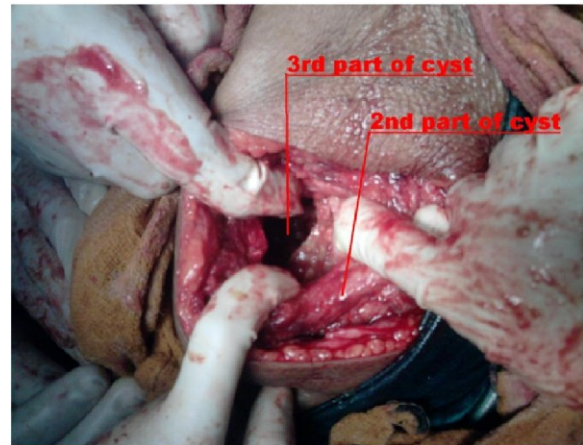


Figure 10. Evacuation of 2nd part revealed the calcified 3rd part of the hydatid cyst.

3rd part then was approached through a upper midline laparotomy incision. 3rd part was partly in the liver parenchyma and partly coming out from the inferior surface of right lobe of liver to become intra-abdominal in location. The 3rd part could't be excised due to its intra-abdominal part having tough attachment to the liver.

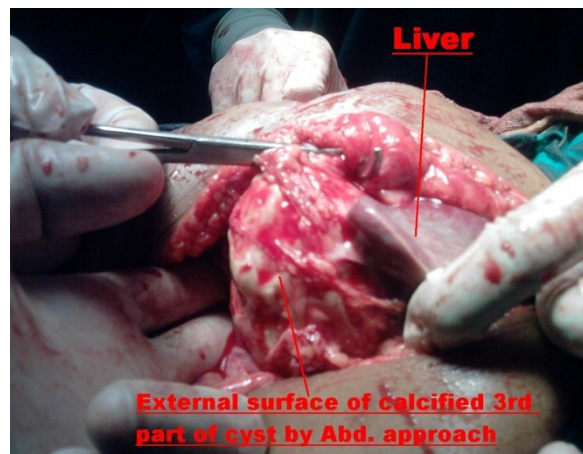


Figure 11. Calcified 3rd part of the hydatid cyst exposed through abdominal approach.

Remanant Cavity of the 3rd part was scooped, washed with 5% povidone iodine & Hypertonic saline solution and packed with omentum.

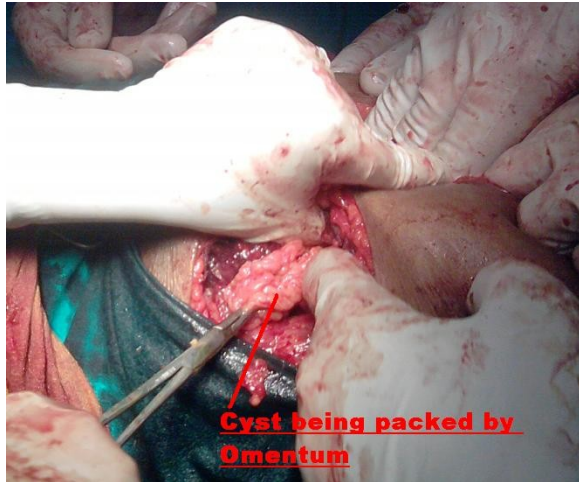

Figure 82. 3rd part of Cyst packed by omentum.

Abdominal cavity was washed with 5% Povidone iodine solution, abdominal drain was placed. Defect in the abdominal wall was 3cm × 3cm in size hence anatomical closure was done. Patient tolerated the procedure well. Histo-pathology examination confirmed it to be a hydatid cyst.

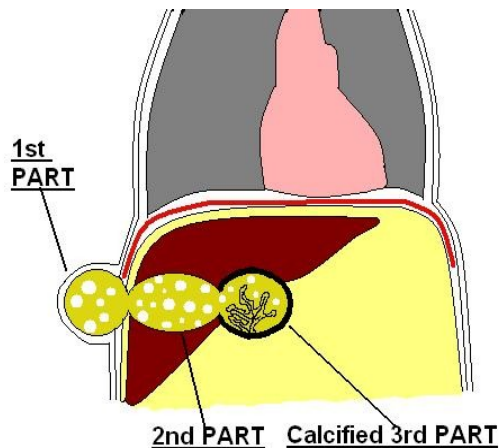


Figure 93. Diagrammatic representation of the structure of the hydatid cyst in this case with respect to the liver and abdominal wall.

Drain was removed on 5th post-operative day. Patient was discharged on

15th post-operative day and started on Albendazole 10mg/kg/day for 4 weeks. On follow up after 1 month, 6 months and 12 months patient was fine and had no evidence of recurrence of the disease.

DISCUSSION

In humans, 50–75% of the cysts occur in the liver, 25% are located in the lungs, and 5–10% distribute along the arterial system. Infection with echinococcal organisms is the most common cause of liver cysts in the world. ^[1]

Reasons of unusual presentation in this case:

1. Patient asymptomatic since 10 yrs after appearance of superficial swelling,
2. Intra-abdominal Hydatid cyst herniating through abdominal wall onto surface, in spite of there being no history of any congenital / acquired abdominal wall defect in the patient.

Hydatid cyst of the liver can with / without getting ruptured spread to various structures around the liver.

Spread of hydatid cyst of liver to the adjacent abdominal wall is called as “ The Parietal complication ” of this disease, which are the subcutaneous rupture of the cyst and spontaneous cutaneous fistula of liver hydatid cyst..

George H Sakorafas, Vania Stafyla and George Kassaras in 9/2006 reported a case of a female with parietal wall swelling discharging fluid and cysts through it. ^[2]

H Bedioui, S Ayadi and colleagues in 11/2006 reported a case of a subcutaneous rupture of hydatid cyst of liver. ^[3]

Florea M, Barbu ST and colleagues reported similar cases in 2008. ^[4]

M Bouassida, S Sassi and colleagues presented two case reports in 10/2012. ^[5]

Parietal complications of hydatid cyst of the liver are extremely rare, clinical presentation can be derailing. The diagnosis is usually

established by ultrasonography and CT-scan [5]

In our case patient had a hydatid cyst of liver, which herniated out of abdomen inspite of no history of any trauma or surgery in past. The swelling was not having any discharge, nor had it ruptured in the subcutaneous space. Hence our case is an “Intact Hydatid cyst of liver herniated through a normal abdominal wall” which is, to the best of our knowledge, the 1st case reported of this type.

CONCLUSION

Hydatid Cyst of liver can herniate out through the anterior abdominal wall even in the absence of any congenital / acquired abdominal wall defect, and present as a superficial abdominal wall swelling . It may rupture to form a fistula discharging daughter cysts or may remain intact as is the case in this case report.

REFERENCES

1. Michael J. Zinner, Stanley W. Ashley; Maingot's abdominal operations; 11th edition, chap28.

2. George H Sakorafas, Vania Stafyla, George Kassaras. Spontaneous cyst-cutaneous fistula: an extremely rare presentation of hydatid liver cyst. *Am Jour Surg* 09/2006; 192(2):205-6.
3. H Bedioui, S Ayadi, K Noura, M Bakhtri, M Jouini, E Ftériche et al. Subcutaneous rupture of hydatid cyst of liver: dealing with a rare observation. *Médecine tropicale: revue du Corps de santé colonial*.11/2006; 66(5):488-90.
4. Florea M, Barbu ST, Crisan M, Silaghi H, Butnaru A, Lupsor M. Spontaneous external fistula of a hydatid liver cyst in a diabetic patient. *Chirurgia (Bucur)*. 2008;103(6):695-8. [PubMed: 19274917].
5. M Bouassida, S Sassi, M M Mighri, A Laajili, F Chebbi, M F Chtourou et al. Parietal complications of hydatid cyst of the liver. Report of two cases in Tunisia. *Bulletin de la Société de pathologie exotique* 10/2012; 105(4):259-61[PubMed: 23086495]

How to cite this article: Singh NB, Chitale AM, Yadav VK. Parietal abdominal wall swelling turning out to be a parietal complication of hydatid cyst of liver - a case report. *Int J Health Sci Res*. 2014;4(3):246-251.
