



Short Communication

Bifurcation of Common Carotid Artery: A Cadaveric Study in South Indian Population

S. Shivaprakash¹, A.G.Vijaykumar²

¹Assistant Professor, Dept of Anatomy, P K Das Institute of Medical sciences, Palakkad, Kerala, India.

²Assistant Professor, Dept of Forensic Medicine & Toxicology, Adhichunchanagiri Institute of Medical Sciences, B G Nagar, Karnataka, India.

Corresponding Author: A.G.Vijaykumar

Received: 03/01/2014

Revised: 21/02/2014

Accepted: 03/03/2014

ABSTRACT

Introduction: Common Carotid Artery [CCA] normally bifurcates at or near the upper border of the thyroid cartilage of larynx (C3-C4 junction).

Aim: The present study was undertaken to study the bifurcation level of the common carotid artery (CCA) with respect to cervical vertebrae in south Indian population.

Materials and Methods: A total of 25 formalin preserved cadavers (50 carotids) were studied during routine dissection for medical students at Kasturba Medical College, Mangalore, Manipal University. Bifurcation levels of the CCA were noted with respect to cervical vertebrae by pushing the midline structures in the neck aside and cervical vertebrae were palpated.

Results: In 12% of cases CCA bifurcated at C2-C3, 28% at C3, 38% at C3-C4, 22% at C4 level. In 72% of Cadavers CCA bifurcated at same level on right and Left side, while in 20% of the cadavers CCA bifurcated higher on left side than right side. In 8% cadavers CCA bifurcated higher on right side than left side.

Conclusion: Carotid artery injury is a rare but potentially devastating event that can occur during anterior cervical approaches. When a neurosurgeon encounters a low-lying bifurcation of the common carotid artery during anterior neck dissection, use of the operating microscope might be helpful in preventing common carotid artery injury.

Key words: Common Carotid Artery [CCA], Bifurcation, cervical vertebrae.

INTRODUCTION

Common Carotid Artery [CCA] normally bifurcates at or near the upper border of the thyroid cartilage of larynx (C3-C4 junction).^[1] But bifurcation may occur as high as C1 or as low as T2.^[2] Several studies have been done to report its level of bifurcation.^[2-10] High bifurcations of the Common Carotid artery do not cause any

problems regarding anterior cervical dissection, but low bifurcation may cause some problems if one is not cautious.^[2] Higher levels of bifurcations are associated with higher incidences of penetrating vascular injuries.^[3] The level of bifurcation of CCA is of significance to vascular surgeons and clinicians in general who may be dealing with a relevant case.

Aim: The present study was undertaken to study the bifurcation level of the common carotid artery (CCA) with respect to cervical vertebrae in south Indian population.

MATERIALS AND METHODS

A total of 25 formalin preserved cadavers (50 carotids) were studied during routine dissection for medical students at Kasturba Medical College, Mangalore, Manipal University. Bifurcation levels of the CCA were noted with respect to cervical vertebrae by pushing the midline structures in the neck aside and cervical vertebrae were palpated.

RESULTS

In 12% of cases CCA bifurcated at C2-C3, 28% at C3, 38% at C3-C4, 22% at C4 level. In 72% of Cadavers CCA bifurcated at same level on right and Left side, while in 20% of the cadavers CCA bifurcated higher on left side than right side. In 8% cadavers CCA bifurcated higher on right side than left side.

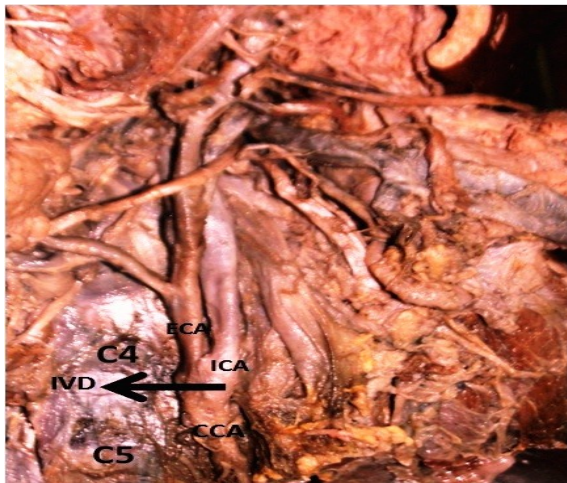


Fig. 1 Photograph of the neck of a cadaver showing the bifurcation of Common Carotid artery with respect to cervical vertebrae. (CCA: Common carotid artery; ICA: Internal Carotid artery; ECA: External Carotid artery; IVD: Intervertebral disc; C4&C5: 4th & 5th cervical vertebrae).

DISCUSSION

The position of the carotid bifurcation reflect the degree of embryological migration of the ECA and is variable.^[4] Several population specific studies have been done to report the level of bifurcation of CCA. Few of them have been mentioned in below table.

Ito & associates reported a high common carotid artery bifurcation in 25 [31.2%], standard bifurcation in 46 [57.5%], low bifurcation in 9 [11.3%] in a total of 80 cases.^[5] Zumre et al have reported that the incidence of C3 bifurcation was noted to be 55% in human fetuses.^[6] Hayashi et al. reported that the position of the bifurcation of the common carotid artery was located around the inferior part of the body of the C3 in Japanese Individuals.^[7] Lo et al. described the carotid artery bifurcation point using its relation with the thyroid cartilage and hyoid bone. They found that the common carotid artery bifurcation point was at the level of the body of the hyoid bone in 40% of the cases, and the level of the bifurcation was asymmetrical between the left and right sides.^[8] Inamasu and associates showed individual variation regarding bifurcation of the common carotid artery in their study^[9]

CONCLUSION

Carotid artery injury is a rare but potentially devastating event that can occur during anterior cervical approaches. When a neurosurgeon encounters a low-lying bifurcation of the common carotid artery during anterior neck dissection, use of the operating microscope might be helpful in preventing common carotid artery injury. A lower location of the common carotid artery bifurcation may obviate some manipulations during anterior cervical approach such as placement of the artificial disc or cage to the intervertebral space on account of its wider transverse diameter.

Source of financial or other assistance: NIL

Competing Interests: The authors declare that they have no competing interests. Both authors have read and approved the final manuscript.

Consent: was taken from the institutional ethics committee.

REFERENCES

1. Standring S. (ed.) Gray's Anatomy. The anatomical basis of clinical practice, 40th ed. Churchill Livingstone, New York, 2008;pp 44.
2. Osborn Anne G: Diagnostic Cerebral Angiography, ed 2. Philadelphia: Lippincott Williams & Wilkins 1999, pp 62-63.
3. Salih Gulsen. An Anatomical Variant: Low-Lying of the Common Carotid Artery, and Its Surgical Bifurcation Implications in Anterior Cervical Discectomy. J Korean Neurosurg Soc.2009; 45: 32-4.
4. Chitra R. Trifurcation of the right common carotid artery. Indian J Plast Surg. 2008; 41: 85-8.
5. Ito H, Mataga I, Kageyama I, Kobayashi K: Clinical anatomy in the neck region-- the position of external and internal carotid arteries may be reversed. Okajimas Folia Anat Jpn.2006; 82: 157-67.
6. Zumre O. Investigation of the bifurcation level of the common carotid artery and variations of the branches of the external carotid artery in human fetuses. Ann Anat. 2005; 187: 361-9.
7. Hayashi N, Hori E et.al. Surgical anatomy of the cervical carotid artery for carotid endarterectomy. Neurol Med Chir (Tokyo) .2005; 45: 25-9.
8. Lo A. Anatomical variations of the common carotid artery bifurcation. ANZ J Surg.2006; 76:970-2.
9. Inamasu J, Guiot BH: Iatrogenic carotid artery injury in neurosurgery. Neurosurg Rev.2005; 28: 239-47.
10. D. Anangwe. Anatomical variations of the carotid arteries in adult Kenyans. *East African Medical Journal*.2008; 85:244-7.

How to cite this article: Shivaprakash S, Vijaykumar AG. Bifurcation of common carotid artery: a cadaveric study in south Indian population. Int J Health Sci Res. 2014;4(3):229-231.

International Journal of Health Sciences & Research (IJHSR)

Publish your work in this journal

The International Journal of Health Sciences & Research is a multidisciplinary indexed open access double-blind peer-reviewed international journal that publishes original research articles from all areas of health sciences and allied branches. This monthly journal is characterised by rapid publication of reviews, original research and case reports across all the fields of health sciences. The details of journal are available on its official website (www.ijhsr.org).

Submit your manuscript by email: editor.ijhsr@gmail.com OR editor.ijhsr@yahoo.com