

Role of Three Dimensional Transvaginal Scan in the Evaluation of Female Pelvic Lesions

Anitha B¹, H. T. Narayana², Satish Tumbal³, Vishal N.S⁴

¹Senior Resident, Department of Radiodiagnosis, Adichunchanagiri Institute of Medical Sciences, B G Nagara, Mandya, Karnataka, India.

²Professor & HOD, Department of Radiodiagnosis, Sathagiri Institute of Medical Sciences, Karnataka.

³Senior Resident, Department of Radiodiagnosis, S.Nijalingappa Medical College, Bagalkote.

⁴Senior Resident, Department of Radiodiagnosis, BLDE Medical College, Bijapur.

Corresponding Author: Anitha B

Received: 08/12//2013

Revised: 07/01/2014

Accepted: 13/01/2014

ABSTRACT

Introduction: Traditional transabdominal approach is still recommended as initial approach though it is associated with limitations, such as patient obesity, bowel gas, an over distended bladder, multipath reflection, pseudo masses, or a retroverted or calcified fibroid uterus; large adnexal masses, masses higher in the pelvis, and uterine fibroids may not be seen adequately during transvaginal scanning, either because they are larger than or outside the probe's more restricted field of view, which is usually seen with transabdominal approach.

Aims and Objectives:

1. Detection of uterine abnormalities.
 - Congenital uterine anomalies (Septate, subseptate, bicornuate, arcuate uterus).
 - Accurate localization of leiomyomas (Submucosal, intramural and subserosal type).
 - Endometrial polyps.
2. To estimate the volume measurements (ovarian volume).
3. In imaging of adnexal lesions to distinguish tubal from ovarian lesions and uterine from ovarian lesions.

Materials and Methods: 1086 patients attended Sagar Hospitals, Obstetrics and Gynaecology Outpatient Department from August 2006 to October 2007. Out of 1086, 490 patients were advised ultrasound pelvis. 335 patients underwent only two-dimensional transabdominal ultrasound due to exclusion criteria. 55 were selected randomly for three-dimensional transvaginal scan and it is a prospective study.

Observation and Results: A Prospective correlation study with 55 patients with pelvic pathology is undertaken to evaluate the correlation of clinical diagnosis, 3D-TVS, with final diagnosis based on postoperative findings/HSG/Histopathology.

Conclusion: Based on the result analysis and observations, we conclude that:

- Three-dimensional TVS is accurate in giving the preoperative details to the gynaecologists.
- Three-dimensional TVS findings correlated with operative findings and histopathological diagnosis.
- Performance of three-dimensional TVS was significant in terms of ovarian lesions followed by ectopic pregnancy, non-neoplastic lesions of uterus and congenital abnormalities of uterus.

Key words: Transvaginal Scan, Female Pelvic Lesions.

INTRODUCTION

Traditional transabdominal approach is still recommended as initial approach though it is associated with limitations, such as patient obesity, bowel gas, an over distended bladder, multipath reflection, pseudomasses, or a retroverted or calcified fibroid uterus; large adnexal masses, masses higher in the pelvis, and uterine fibroids may not be seen adequately during transvaginal scanning, either because they are larger than or outside the probe's more restricted field of view, which is usually seen with transabdominal approach.^[1]

Transvaginal ultrasonography in evaluation of female pelvis has become increasingly widespread since its introduction in 1984 and it is considered integral part of the pelvis sonogram. It closely stimulates a bimanual pelvis examination. It is important to make sure the bladder is completely empty, otherwise the ovaries may reside too far posterior to be seen easily. Tissue characteristics are displayed to advantage with higher frequencies.^[1,2]

Three-dimensional ultrasound measurements of distance and volume are sufficiently accurate to use clinically. Three-dimensional transvaginal sonography main applications include assessment of uterine anomalies, intrauterine pathology, polycystic ovaries, ovarian follicular monitoring and endometrial receptivity. It is also useful for detailed evaluation of failed and/or ectopic pregnancy. Three-dimensional ultrasound allows for new volume rendering displays that show depth, curvature and surface images not available with conventional methods.^[3]

Aims and objectives:

1. Detection of uterine abnormalities.

- Congenital uterine anomalies (Septate, subseptate, bicornuate, arcuate uterus).
 - Accurate localization of leiomyomas (Submucosal, intramural and subserosal type).
 - Endometrial polyps.
2. To estimate the volume measurements (ovarian volume).
 3. In imaging of adnexal lesions to distinguish tubal from ovarian lesions and uterine from ovarian lesions.

MATERIALS AND METHODS

Study Cohort: 1086 patients attended Sagar Hospitals, Obstetrics and Gynaecology Outpatient Department from August 2006 to October 2007. Out of 1086, 490 patients were advised ultrasound pelvis. 335 patients underwent only two-dimensional transabdominal ultrasound due to exclusion criteria. 55 were selected randomly for three-dimensional transvaginal scan and it is a prospective study.

Inclusion criteria: All married females aged between 20-50 years with pelvic pathology are included in this study.

Exclusion criteria:

- Unmarried females are excluded from this study.
- Uncooperative patients.
- Patients with hematometra, acute pelvic inflammatory disease, atrophic or stenotic vagina diagnosed with transabdominal scan.

Transvaginal ultrasound protocol

Voluson 730 Expert (GE Ultrasound Machine) with frequency of 7-9 MHz TVS probe and 3D ultrasound probe are used.

Result Analysis

Statistical Methods: Descriptive statistical analysis has been carried out in the present study. Paired Proportion test - Online statistical software developed by University of Baltimore, USA has been used to find the significance of study parameters between Clinical and 3D-TVS findings

Significant figures

- + Suggestive significance $0.05 < p < 0.10$
- * Moderately significant $0.01 < p \leq 0.05$
- ** Strongly significant $p \leq 0.01$

Table 1: Presenting complaints.

Presenting complaints	Number(n=55)	%
1.Irregular periods	21	38.2
2. Menorrhagia	10	18.2
3.Pain abdomen	9	16.4
4.Backache	9	16.4
5.Primary infertility	8	14.5
6.Amenorrhoea	6	10.9
7. Bleeding per vagina	4	7.3
8.H/o Endometriosis	2	3.6
9 White discharge per vagina	2	3.6
10.Not attained menarche	1	1.8
11.Termination of pregnancy	1	1.8
12 Secondary infertility	1	1.8
13. Distension of abdomen	1	1.8

Table 1 shows presenting complaints of the patient studied. Irregular period was the commonest complaint by 21 patients (38.2%) followed by menorrhagia in 10 patients (18.2%).

Statistical software: The statistical software namely SPSS 15.0, Stata 8.0, MedCalc 9.0.1 and Systat 11.0 were used for the analysis of the data and Microsoft Word and Excel have been used to generate graphs, tables etc.

OBSERVATION AND RESULTS

Study design: A Prospective correlation study with 55 patients with pelvic pathology is undertaken to evaluate the correlation of clinical diagnosis, 3D-TVS, with final diagnosis based on operative findings/HSG/Histopathology.

Table 2 shows diagnosis made by patients 3D-TVS of the patients studied. Commonest diagnosis by three-dimensional transvaginal scan was polycystic ovarian disease (PCOD) in 23 cases (41.8%) followed by fibroid in 8 cases (14.5%).

Table 3 shows correlation between clinical diagnosis of 3D-TVS and final diagnosis (HSG/Histopathology/Operative findings) of the patients studied.

Table 4 shows performance of 3D-TVS in diagnosis of pelvic pathology of the patients studied. Performance of 3D-TVS was significant in terms of ovarian lesions, followed by ectopic pregnancy, non-neoplastic lesions of uterus and congenital abnormalities of uterus.

Table 2: 3D-TVS.

3D-TVS	Number (n=55)	%	90% CI
1.PCOD	23	41.8	31.5-52.9
2.PID	3	5.5	2.2-12.9
3.Fibroid	8	14.5	8.4-24.1
4.Adenomyosis	-	-	-
5.Adenomyoma	-	-	-
6.Cervical polyp	3	5.5	2.2-12.9
7.Endometrial polyp	2	3.6	1.2-10.4
8.Ectopic pregnancy	6	10.9	5.8-19.7
9.Congenital abnormality of uterus	4	7.3	3.3-15.3
10.Simple Ovarian cyst	1	1.8	0.4-7.8
11.Endometriosis	1	1.8	0.4-7.8
12.Ovarian hyper stimulation syndrome	1	1.8	0.4-7.8
13.Hypoplastic uterus	1	1.8	0.4-7.8
14.Ovarian malignancy	1	1.8	0.4-7.8
15.Parovarian cyst	1	1.8	0.4-7.8
16.Fibroid or Adenomyoma	1	1.8	0.4-7.8
17.Fibroid, Adenomyosis & Adenomyoma	1	1.8	0.4-7.8
18.Adenomyosis, Adenomyoma	1	1.8	0.4-7.8

Table 3: Correlation between clinical diagnosis, 3D-TVS and final diagnosis.

Findings	Clinical diagnosis (n=55)	3D-TVS (n=55)	Final diagnosis (n=36)
1.Non-neoplastic lesions of uterus	3 (5.5%)	5(9.1%)	4(11.1%)
2.Ovarian lesions	0	26 (47.3%)	1(2.8%)
3.Cervical lesions	3 (5.5%)	3 (5.5%)	2(5.6%)
4.Congenital abnormalities of uterus	2(3.6%)	4 (7.3%)	3 (8.3%)
5.Pelvic inflammatory disease	1(1.8%)	3(5.5%)	3(8.3%)
6.Endometriosis	0	1 (1.8%)	0
7.Ectopic pregnancy	3(5.5%)	6 (10.9%)	6(16.7%)
8.Benign lesions of uterus	10(18.2%)	10(18.2%)	10 (27.8%)
9.Not significant	36 (65.5%)	-	-

Clinically, diagnoses of ovarian lesions were missed which was picked up by three-dimensional transvaginal scan in 26 cases. Non-neoplastic lesions of the uterus were diagnosed clinically in 3 cases, by 3D-TVS in 5 cases and by HSG/Histopathology/Operative findings in 4 patients who underwent this.

Table 4: Performance of 3D-TVS in diagnosing pelvic pathology.

Findings	Clinical diagnosis (n=55)	3D-TVS (n=55)	p value
1.Non-neoplastic lesions of uterus	3 (5.5%)	5(9.1%)	0.243
2.Ovarian lesions	0	26 (47.3%)	<0.001**
3.Cervical lesions	3 (5.5%)	3 (5.5%)	>0.05
4.Congenital abnormalities of uterus	2(3.6%)	4 (7.3%)	0.205
5.Pelvic inflammatory disease	1(1.8%)	3(5.5%)	0.155
6.Endometriosis	0	1 (1.8%)	0.160
7.Ectopic pregnancy	3(5.5%)	6 (10.9%)	0.162
8.Benign lesions of uterus	10(18.2%)	10(18.2%)	>0.05
9.Not significant	36 (65.5%)	-	<0.001**

p values are obtained based on paired proportion test.

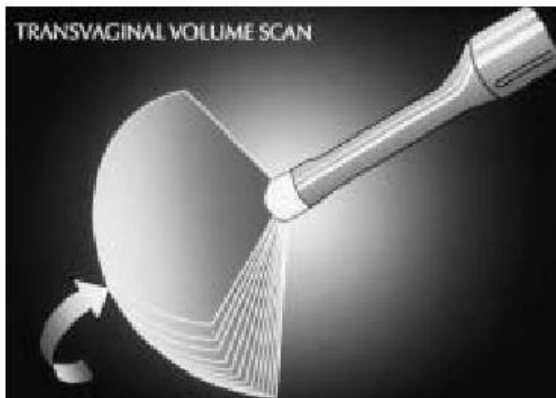


Figure 1 Volume acquisition with a 'fan scan' three-dimensional endovaginal probe (schematic diagram)

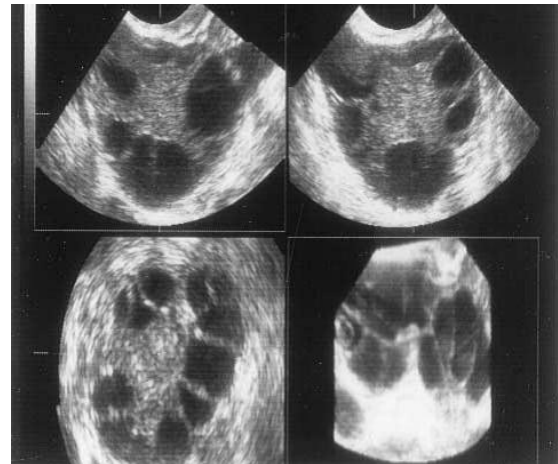


Fig 2: 3 D Ultrasound image of single ovary with 3D rendering possible to locate exact position and observe internal characteristic of each follicle.

DISCUSSION

Since its first introduction in clinical practice since 1993, three-dimensional TVS has been widely used and reported to be a

more sensitive modality when compared to transabdominal scan especially in endometrial pathology, volume calculation, uterine anatomy, congenital uterine

anomalies, ectopic pregnancy, localization of IUCD, preoperative and localization of tumor and postoperative follow-up.^[4]

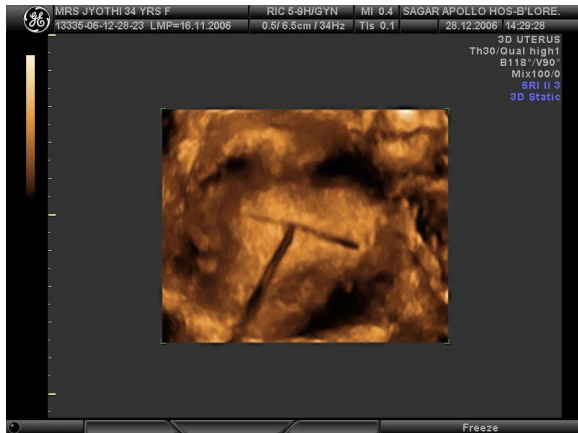


FIG 3: Check of the position of an intrauterine device. Three Dimensional Ultrasound can confirm correct placement of the device and check for proper extension of the arms.

On a practical note, a distended urinary bladder, which was required for transabdominal sonography, has now been

Ultrasound finding	Advantage of three-dimensional ultrasound (n/N)
Fibroid uterus	2/42
Uterine anomaly	20/20
Endometrial polyp	7/8
Endometrial evaluation	10/21
Endometrium during tamoxifen use	11/11
Hematometra	1/4
Remnants of incomplete abortion	3/8
Endometrial carcinoma	24/28
Cervical carcinoma	8/15
Check for intrauterine device	27/27
Intramural pregnancy	2/2
Tubal pregnancy	4/12
Hydrosalpinx	4/10
Polycystic ovaries	6/6
Exclusion of ovarian tumor	4/12
Purely cystic ovarian mass	3/39
Cystic-solid ovarian mass	38/55
Solid ovarian tumor	0/4
Parovarian cyst	2/3
Postoperative lymph cyst	0/6
Recurrent carcinoma in lower pelvis	3/7
Bladder endometriosis	4/5
Bladder carcinoma	2/2
Paraurethral cyst	1/1
Total	186/348 (53.4%)

become detrimental to TVS because it displaces the uterus and ovaries, thereby interfering with optimal real time compression imaging.^[4]

Three dimensional ultrasound volume measurements are accurate to within 5%. Arbitrary plane viewing allows for assessment of pathology in planes that cannot be obtained using 2 dimensional ultrasound transabdominal and transvaginal transducers.^[5]

With the technical development, ultrasound tends to overpass its limits and tend to become the main investigation tool even for situations when it was traditionally considered “second best”. It is more convenient both for patient and doctor and has real diagnostic value. High quality ultrasound equipment offers a series of benefits over any other kind of investigations.^[6]

We studied 55 female patients randomly with known/suspected clinically diagnosed patients with pelvic pathology in the age group of 20-50 years referred for ultrasound pelvis fulfilling inclusion and exclusion criteria to our department during August 2006 to October 2007. The maximum number of patients belonged to age group of 25-29 years (45.5%) followed by the age group of 20-24 years (25.5%).

In 1999, Eberherd Merz undertook the study to evaluate three-dimensional transvaginal ultrasound in gynecological diagnosis. It was a prospective study comprising of 348 patients. The advantage of three-dimensional ultrasound with two-dimensional ultrasound was compared.^[7]

Comparing three and two-dimensional ultrasound in a preliminary study of 348 patients, Eberhard Merz found that in 53% of patients, the four different display modes provided by three-dimensional ultrasound yielded additional or superior information to the two-dimensional

technique. It was concluded that this was mainly due to the availability of transverse planes with the transvaginal approach as well as to the possibility of demonstrating irregular surface structures three-dimensionally. [7]

In our study comprising of 55 patients, the advantage of three-dimensional ultrasound versus two-dimensional ultrasound was compared.

Ultrasound finding	Advantage of three-dimensional ultrasound
Fibroid uterus	5/8
Adenomyoma with adenomyosis	1/3
Uterine anomaly	4/4
Endometrial polyp	2/2
Ectopic pregnancy	6/6
Cervical polyp	3/3
Polycystic ovarian syndrome	23/23
Parovarian cyst	1/1
Ovarian hyperstimulation syndrome	1/1
Ovarian malignancy	0/1
Endometriosis	1/1
PID	3/3
Urinary bladder endometrioma	1/1
Total	52/57 (90%)

Two patients of our study group had multiple findings. We found that advantage of 3D ultrasound over 2D ultrasound was 90% as compared to 53% of Eberhard Merhz study in 1999.

In our study cohort comprising of 55 randomly selected patients, the majority were in the age group patients, the majority were in the age group of 25-29 years. The indications for 3D ultrasound pelvis were irregular periods (21), menorrhagia (10), pain abdomen (9), backache (9), primary infertility (8), amenorrhea (6), Bleeding per vagina (2), not attained menarche (1), termination of pregnancy (1), secondary infertility (1), distension of abdomen.

An important observation in our study was that performance of three-dimensional transvaginal scan was significant in terms of ovarian lesions, followed by ectopic pregnancy, non-

neoplastic lesions of uterus and congenital abnormalities of uterus.

Majority of the studies have concluded that three-dimensional TVS are highly helpful in giving accurate details to the gynecologists and also convenient and beneficial to patients. In our study, three-dimensional TVS proud to be helpful in providing almost all the details required by the gynecologists.

CONCLUSION

Based on the result analysis and observations, we conclude that:

- Three-dimensional TVS is accurate in giving the preoperative details to the gynaecologists.
- Three-dimensional TVS findings correlated with operative findings and histopathological diagnosis.
- Performance of three-dimensional TVS was significant in terms of ovarian lesions followed by ectopic pregnancy, non-neoplastic lesions of uterus and congenital abnormalities of uterus.

Source of financial or other assistance – NIL

Competing interest- The authors declare that they have no competing interest. Both authors have read and approved the final manuscript.

REFERENCES

1. Maija GF, Anne FJ. Transvaginal ultrasonography. RCNA 1992; 30 (5): 955-976.
2. Jurkovic D. Three-dimensional ultrasound in Gynaecology: A critical evaluation. Ultrasound Obstet Gynaecol 2002 Feb; 19 (2): 1009-1017.
3. Dolores HP, Nira BN. Three-dimensional ultrasound in obstetrics

and gynecology. RCNA 2001 May; 39(3):499-521.

4. Nick RF, Arthur CF. Classifying the role of Three Dimensional Transvaginal Sonography in reproductive medicine: as evidence based appraisal. Journal of Experimental and clinical assisted reproduction 2005; 2:10.
5. Dolores H, Nira B, Mickey SC and Thomas RN. Three dimensional ultrasound in Obstetrics and Gynecology. Radiologic clinics of

North America 2001May; 39(3):499-521.

6. Mona Z, Radu V. Conventional versus 3d ultrasound for the investigation of infertile women. Obstetrics and gynecology department, eilios university hospital, bucharest, romania, September 2008.
7. Eberhard M. Three dimensional transvaginal ultrasound in gynecological diagnosis. Ultrasound in obstetrics and gynecology august 1999; 14(2):81-86.

How to cite this article: Anitha B, Narayana HT, Tumbal S et. al. Role of three dimensional transvaginal scan in the evaluation of female pelvic lesions. Int J Health Sci Res. 2014;4(2):109-115.

International Journal of Health Sciences & Research (IJHSR)

Publish your work in this journal

The International Journal of Health Sciences & Research is a multidisciplinary indexed open access double-blind peer-reviewed international journal that publishes original research articles from all areas of health sciences and allied branches. This monthly journal is characterised by rapid publication of reviews, original research and case reports across all the fields of health sciences. The details of journal are available on its official website (www.ijhsr.org).

Submit your manuscript by email: editor.ijhsr@gmail.com OR editor.ijhsr@yahoo.com