

Original Research Article

Study of Periprosthetic Supra-Condylar Femur Fractures in Operated Cases of TKR: Incidence and Outcome

Gandhi Rutul R¹, Purohit Sharad¹, Bhalodia Haresh P², Singh Somesh P³

¹Resident Doctor, ²Hon. Professor, ³Assistant Professor,
Dept. of Orthopaedics, B. J. Medical College and Civil Hospital, Ahmedabad.

Corresponding Author: Gandhi Rutul R

Received: 28/10/2013

Revised: 26/11/2013

Accepted: 07/12/2013

ABSTRACT

Background: Periprosthetic fractures following total knee arthroplasty (TKA) are infrequent, devastating complications. The purpose of study is to compare non operative and open reduction and internal fixation techniques for periprosthetic supracondylar femur fractures.

Methods: We followed 3920 patients of TKR and found 23 patients having periprosthetic fractures. 20 patients were treated by operative method while 3 patients were treated by conservative methods.

Results: The total incidence of the fracture was 0.58 %. 3 patients suffered from infection after surgery. 2 out of 3 conservative treated cases had malunion, while amongst 20 cases treated operatively, 16 had primary union, 2 had union after bone grafting while 2 had non union. The average reduction in the knee score after fracture is 20.53%.

Conclusions: Good results for periprosthetic fracture can be obtained if proper and timely intervention is done. However, short duration of follow up and small number of patients is major limiting factor.

Key words: periprosthetic fracture, total knee replacement (TKR), supracondylar femur fracture, LISS, DFLP

INTRODUCTION

Periprosthetic supracondylar femur fractures following total knee arthroplasty (TKA) are infrequent, but devastating, complications. Although the prevalence is low, ranging from 0.3% to 2.5%, as the number of TKAs performed increases, so

will the number of periprosthetic femur fractures. [1,2]

Many of these periprosthetic fractures occur as a result of low-energy trauma. The risk factors associated with the development of periprosthetic fractures include osteopenia; osteoporosis; and certain disease processes such as rheumatoid

arthritis, seizure disorders, Parkinson's disease, and myasthenia gravis. [1, 3-7] Corticosteroid use, increased patient age, and female sex also have been implicated. [1, 7,8] Processes related to the implant and surgical technique such as anterior femoral notching, malalignment, implant loosening, and osteolysis may play an additional role in the development of periprosthetic fractures. [3,4,7,9]

Treatment options range from nonoperative closed management including casting, traction, and bracing to surgical treatment with open reduction with internal fixation, intramedullary fixation, and, finally, revision arthroplasty. The decision of whether to proceed with nonoperative or operative treatment has been the subject of a great deal of controversy. Rates of nonunion for supracondylar fractures proximal to total knee prostheses are higher than for supracondylar fractures without the implant. [1, 3, 4,10] Stems, rods, screws, and cement may block the medullary canal, preventing intramedullary fixation of fractures. [1, 3, 4,10] Stems and rods also block screw fixation through the medullary canal to hold plates on bone. It has been shown that that patients sustaining a periprosthetic distal femur fracture have increased morbidity (higher incidence of non-union, infection, fixation failure, and revision surgery) and mortality rates compared to those that have a distal femur fracture that does not occur in the presence of prosthesis. If all treatment types are pooled together, the non-union rate is 9%, loss of fixation 4%, the infection rate is 3%, and the revision surgery rate is 13%. [12] The purpose of this study was to compare the outcomes of nonoperative and traditional open reduction and internal fixation techniques for periprosthetic supracondylar femur fractures following TKA and to compare our experience with historical reports in the literature.

METHODS

From January 2004 to December 2010, we followed 3920 operated patients of TKR and found 23 patients operated for TKR having periprosthetic supracondylar fractures. A retrospective analysis of these records was conducted. The details regarding the pre-fracture status and treatment offered were recorded from the Medical Record Department of the hospital.

All the patients were personally visited to assess their present clinical status using the parameters as Detailed history regarding periprosthetic fracture, Pre fracture knee score, Present knee score, Predisposing factors, Management, Re-intervention, if any and Any complicating event. Pre fracture status was difficult to assess exactly as all the patients reported to us after the occurrence of the fracture. However from the history it was clear that they had good range of motion in the degrees of more than 90 and no stiffness.

The functional outcome of the patients was assessed by using the Knee Society Score. The time from index arthroplasty ranged from 5 days to 6 years. There were 17 women and 6 men, and the average age was 68.26 years (range, 52–83 years). 11 of these fractures were the result of low-velocity trauma. The other 12 fractures occurred as the result of motor-vehicle accidents (MVAs). 3 patients with minimally displaced fractures underwent conservative management while others were treated surgically with stable internal fixation mostly with periarticular distal femoral plates.

We classified the patients having supracondylar fractures according to Rorabeck's scheme of classification. Rorabeck et al. divided periprosthetic supracondylar femur fractures into 3 types. Type I involves a nondisplaced fracture in association with a stable prosthesis, type II also involve a stable prosthesis but a

displaced fracture, and type III involves any fracture in the presence of a loose prosthesis. [2]

CONSERVATIVELY TREATED PATIENTS

All patients were given traction and slab initially and then given AK cast. One

patient was given immediate cast due to minimal displacement and swelling. All patients were evaluated at the end of 1 week for plaster condition as well as radiological alignment. The cast was continued for an average period of 10-12 weeks.

Figure 1: Conservatively Managed periprosthetic Fracture.

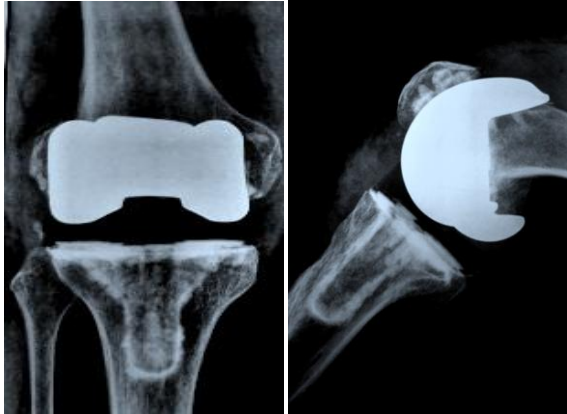


Fig. 1a. Fracture

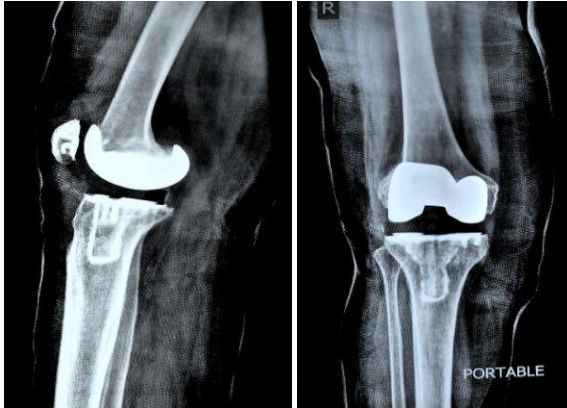


Fig. 1b. 10 week Cast Application

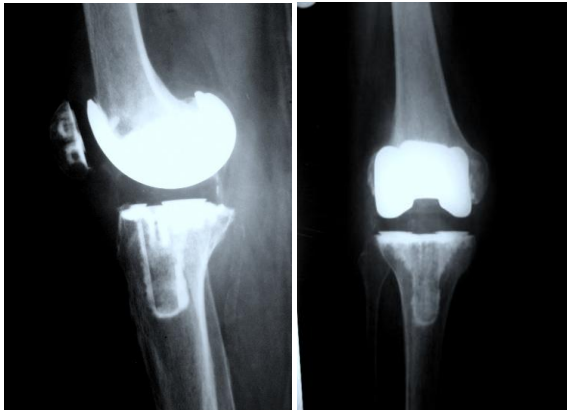

Fig. 1c. Final Followup showing Acceptable Union.

Figure 2: Distal Femoral Locking Plate.

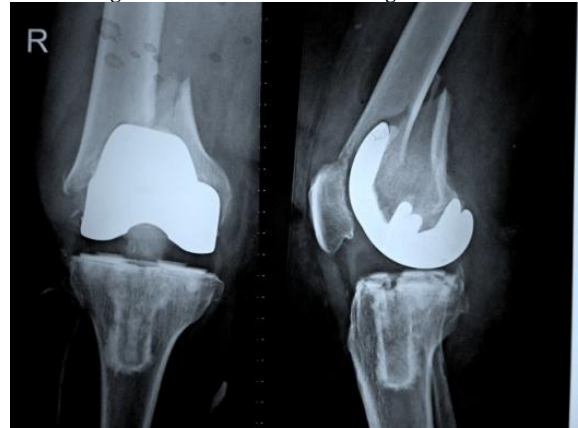


Fig. 2a. Fracture

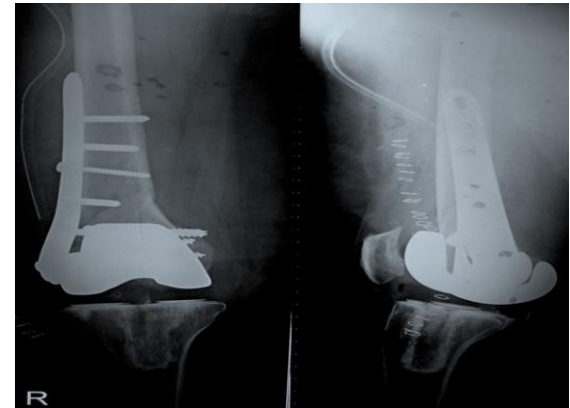


Fig. 2b. Immediate Post-Operative.

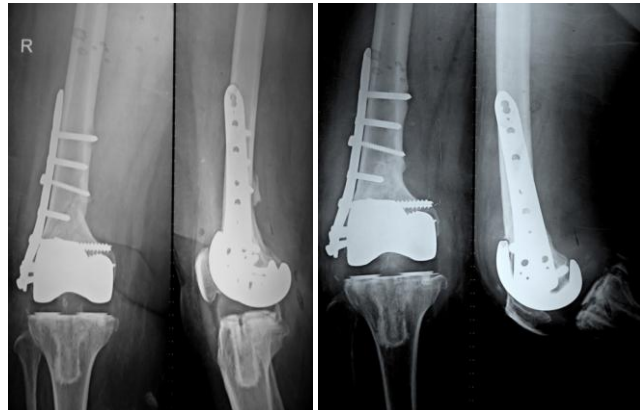

Fig. 2c. 6 month followup.

Fig. 2d. Final (1 year) Follow-up.

Follow-up and Rehabilitation Protocol

The patients were followed-up initially at the end of 1st week and then every month for plaster condition, clinical and radiological evaluation.

Once the signs of satisfactory radiological union appeared, the cast was removed and physiotherapy was started in the form of Static Quadriceps Exercises, Stretching exercises, knee mobilization and Range of Motion exercises. Partial Weight Bearing was allowed for a period of 4-6 weeks and then full weight bearing was started initially with support and then independently wherever possible.

Surgical technique

PLATING

20 of the 23 patients were treated by plating, either Distal Femur Locking Plate (DFLP), Condylar Buttress Plate (CBP) or Low Contact Dynamic Compression Plate(LCDCP) according to position of the fracture.

Follow-up and rehabilitation Protocol

All the patients were followed up first at the time of stitch removal and then every 6 weeks for 3 visits and then depending upon the requirement every 6 monthly for functional as well as radiological parameters

Depending upon the post-op fracture reduction quality and the stability of the fixation, physiotherapy was started in immediate post-operative period. Initially, guarded knee mobilization (with hinged AK-BK brace) was started and gradually, independent knee mobilization was introduced. Gradually, Range of motion and strengthening exercises were introduced and once the signs of clinical and radiological union appeared (decreased pain, increased confidence of the patient, increased range of

motion and slow disappearance of the fracture line on x rays), gradual weight bearing was started.

RESULTS

Total 23 cases of periprosthetic fractures were reported from 3920 consecutive cases of total knee replacements. The total incidence of the periprosthetic fracture in operated case of TKR in our study was 0.58 %.

Postoperative follow-up averaged 26 months (range,5 months to 48 months).

Average age at periprosthetic fracture was 68.26 years; 67.5 years in males and 68.52 years in females. (Range 52-83 years). The interval between TKR and periprosthetic fracture averaged 14.38 months, ranging from 0.1 to 71 months.

Osteoporosis was associated with 6 cases and majority of these fractures associated with osteoporosis occurred following a low velocity trauma.

Anterior femoral notching was associated with total 14 patients, 10 cases were having grade I notching while 4 cases were having grade II notching.

1 case had ipsilateral hip implant, which also increased the risk by acting as a stress riser in the femur distal to the tip of the stem.

Majority patients (n=20) experienced class II fracture (Displaced fracture with intact bone-prosthesis interface); 3 patients with low velocity trauma experienced Class I fracture (Undisplaced Fracture).

Out of 23 patients, 20 patients were treated by operative method while only 3 patients with relatively undisplaced patients were treated by conservative methods.

Out of 20 operated patients 16 underwent Distal Femur Locking Plate, while 3 patients had Condylar Buttress Plating, 1 patient was managed with Low Contact Dynamic Compression Plating.

Table 1: Age, Sex, Predisposing factors, Time interval and Classification of periprosthetic fracture.

No	Age	Sex	Mode of Injury	Interval betnTKR and Periprosthetic Fracture (Months)	Predisposing Factors	Classification Acco to Rorabeck Classification
1	83	M	Low	1	Gr 2 Notching, PD Osteoporosis	R2
2	60	F	High (RTA)	71	Gr 1 Notching Osteoporosis	R2
3	76	F	High (RTA)	22	Gr 2 Notching	R2
4	64	M	High (RTA)	12	Gr 1 Notching	R2
5	73	F	High (RTA)	46		R2
6	64	F	Low	0.5		R2
7	70	M	High (RTA)	12	Gr 1 Notching	R2
8	78	F	Low	0.1	Gr 1 Notching Osteoporosis	R2
9	68	F	High (RTA)	24	PD	R2
10	83	F	Low	0.5	Gr 1 Notching Osteoporosis	R2
11	70	F	High (RTA)	27	RA	R2
12	64	F	Low	4	Gr 2 Notching	R2
13	67	F	High (RTA)	20	Gr 1 Notching	R2
14	59	F	Low	4	Cemented Bipolar	R2
15	65	F	Low	9	Gr 1 Notching, RA	R2
16	72	M	High (RTA)	13	Gr 1 Notching, PD	R2
17	52	M	High (RTA)	17		R2
18	80	F	Low	6	Osteoporosis, RA	R2
19	62	F	High (RTA)	5	Gr 1 Notching	R2
20	64	M	Low	0.5	Gr 2 Notching	R2
21	60	F	Low	2	Gr 1 Notching	R1
22	68	F	Low	2	Osteoporosis	R1
23	68	F	High (RTA)	32		R1

Average duration of hospitalization was 11.08 days; 7.67 days in conservatively managed patients while 11.8 days in operated cases

3 patients suffered from infection after surgery, all in the early post operative period in the form of persistent wound discharge. No organisms could be isolated from the

culture of the discharge. They were treated with surgical debridement and course of IV broad spectrum antibiotics for 4 weeks covering both gram positive and gram negative organisms followed by 2 weeks of oral antibiotics. Serial blood counts, ESR and C reactive protein titers were done and patients were considered to be free of

infection after the titers remained normal for 6 weeks after stopping the antibiotics. With this we could achieve union in the form of malunion in one patient, while the other 2

ultimately progressed to radiological non-union and refused to have any further surgical intervention.

Table 2: Management, Duration of hospitalization, Complications, Knee scores and Outcomes.

No	Interval to Definitive Management	Definitive line of Mx of Periprosthetic Fracture	Duration of Hospitalization for Periprosthetic #	Complications	Knee Score		Functional Outcome	Radiological Union
					Post TKR	Final F ^u p		
					1	2 days	Operative (DFLP)	22 days
2	3 days	Operative (DFLP)	21 days	Infection	92	72	F4 (20)	Malunion
3	2 days	Operative (DFLP)	10 days	Delayed union after BG	94	88	F1 (75)	Present
4	1 day	Operative (DFLP)	7 days		90	84	F2 (60)	Present
5	5 days	Operative (DFLP)	8 days		92	84	F2 (55)	Present
6	3 weeks	Operative (DFLP)	12 days		84	80	F2 (70)	Present
7	2 days	Operative (CBP)	7 days		86	84	F2 (65)	Present
8	4 days	Operative (DFLP)	11 days		90	88	F1 (85)	Present
9	2 days	Operative (DFLP)	12 days		82	80	F2 (65)	Present
10	3 days	Operative (DFLP)	17 days		86	82	F2 (50)	Present
11	3 days	Operative (DFLP + Rev TKR)	18 days	delayed union after BG	86	82	F2 (65)	Present
12	2 days	Operative (DFLP)	7 days		88	88	F1 (85)	Present
13	1 day	Operative (DFLP)	12 days	# S/F (Re-fracture)	88	82	F2 (70)	Present
14	5 days	Operative (DFLP)	11 days		88	84	F2 (55)	Present
15	3 days	Operative (DFLP)	10 days		90	88	F1 (75)	Present
16	6 days	Operative (CBP)	15 days	Infection	80	0 (Non-union)	F4 (15)	Absent
17	28 days	Operative (CBP)	7 days		84	60	F3 (45)	Present
18	6 days	Operative (DFLP)	12 days		84	79	F3 (35)	Present
19	3 days	Operative (LCDCP + TBW)	8 days		90	88	F1 (85)	Present
20	1 day	Operative (DFLP)	5 days		88	86	F1 (80)	Present
21	0 days	Conservative (AK Cast X 12wks)	4 days		92	80	F2 (65)	Malunion
22	14 days	Conservative (AK Cast X 10wks)	14 days		92	82	F2 (70)	Present
23	3 days	Conservative (AK Cast X 10 wks)	5 days		88	78	F2 (60)	Malunion

RTA: road traffic accidents, DFLP: distal femur locking plate, CBP: condylar buttress plating, LCDCP: low contact dynamic compression plating, TBW: tension band wiring

3 patients experienced malunion; 2 of them belonged to conservatively managed group. Average Knee Society Score on final follow-up was 80 in conservatively managed patients and 87.0 in operated patients.

17 out of 23 patients were ambulatory at the latest follow-up, while 2 were non-ambulatory (Functional Category 4). 13 of the 17 patients required assistive devices for ambulation. Most patients were able to achieve limited but independent activities

Residual alignment at last follow-up for operated cases was 3.77° of valgus and that for conservatively treated cases was 8.67° of valgus.

DISCUSSION

This report compares our experience with surgical management of periprosthetic supracondylar femur fractures with historical reports in the literature. The treatment of periprosthetic supracondylar femur fractures poses interesting management challenges. The literature remains fairly divided on the best treatment method since Hirsch et al. first described this entity in the early 1980s. Nonoperative conservative management, using casting, traction, and immobilization, can be complicated by delayed union, muscular atrophy, loss of function, venous thromboembolism, and physical deconditioning. The best operative technique remains somewhat controversial. Multiple factors must be considered before deciding on the treatment plan. These include the fracture pattern, degree of displacement, and type of prosthesis used. The functional status of the prosthesis, including loosening, wear, and instability, as well as the quality of the surrounding bone, also must be taken into account. Good outcomes previously were defined as healed fractures without joint pain and a 90° arc of motion. Furthermore, it has also been suggested that shortening of the affected

limb up to 2 cm and 5° of valgus/varus deformity can be accepted. [1,2] Operative fracture management is undertaken with the goal of achieving fracture stability and union, while allowing for early patient mobilization. The methods of surgical fixation include standard ORIF techniques using condylar buttress plates, condylar screws, or blade plates, retrograde intramedullary rod placement, and the use of supracondylar nails. [13,14,15,18]

The current paper reviews a cohort of total 23 cases of periprosthetic fractures reported from 3920 cases of total knee replacements.

The average age of the series is 68.3 years, the minimum been 52 and the maximum been 83 years. Average age is 67.5 years in males and 68.52 years in females. Thus this is a relatively older population which is quite expected considering the type of the study.

Females outnumbered the males with 17 out of 23 (73.91 %) been females and only 26.09 % been males. The findings reflected that the fractures are common in elderly age group, being commoner in females than in males.

Osteoporosis is a significant risk factor for post-operative periprosthetic fractures. In our study, it was associated with 6 cases and majority of these fractures associated with osteoporosis occurred following a low velocity trauma. Paraschou et al [28] in his study "Results of treatment of periprosthetic supracondylar femoral fractures above total knee arthroplasty" showed that osteoporosis was associated with 7 patients out of 15 patients; all of them due to low velocity trauma; the results are almost similar to our study.

Notching is also an important factor for these fractures; a 3-mm anterior femoral notching resulted in torsion load to failure by 55 N-m. [11, 21, 26,31] The risk of fracture was initially thought to be due to a decrease

in bending and torsion strength associated with notching. These results, however, were based on mathematical and biomechanical studies, but in clinical practice, little evidence is available to support this theory. [32] Ritter et al [5] in their retrospective analysis demonstrated no difference in knees with or without notching. Their observations were attributed to osseous remodeling and stress redistribution. In our study, notching is associated with total 14 patients, 10 cases were having grade I notching while 4 cases were having grade II notching. Out of the 14 cases, 7 cases had fracture within 6 months of TKA, while others had fracture after 6 months.

In 1996, David H. Sochart, Kevin Hardinge [16] studied Nonsurgical management of supracondylar fracture above total knee arthroplasty. Nonoperative treatment of fractures above well-fixed components can, however, be as successful as surgical intervention, and remains a viable first-line approach. 3 patients who fell in Rorabeck's category R1 were treated conservatively. Although 2 out of them were malunited all the 3 fractures united at final follow up and neither of them needed reintervention or had any other complications.

Out of 20 operated patients 16 underwent DFLP, while 3 patients had CBP, and 1 patient was managed with LCDCP. Moran et al [30] reported on 15 displaced fractures treated with DFLP, 13 of them showed acceptable radiological union within 3 months; 1 patient had malunion while one had non-union which later united by bone grafting. Thus, DFLP is now the preferred method for the ORIF. [20,24,27,28]

Average duration of hospitalization was 11.08 days; 7.67 days in conservatively managed patients while 11.8 days in operated cases. 6 out of 20 operated cases required some or the other form of re-intervention after primary management of

periprosthetic fracture which increased the duration of hospitalization ranging from 5-15 days with an average increase of 6 days as compared to the average duration without any re-intervention. The average reduction in the knee score after periprosthetic fracture is 20.53% which shows that the periprosthetic fracture ultimately hampers the functional outcome of TKR. As per functional assessment based on knee score at the final follow up, 25 % achieved category F1 (>75), 55 % achieved category F2 (50-75), 8%F3(25-50) and 12% fell in F4 (<25).

As per radiological assessment 2 out of 3 conservative treated cases had malunion, while amongst 20 cases treated operatively, 16 had primary union including 1 malunion, 2 had union after bone grafting while 2 had non union. Hari P. Bezwada et al [29] reported 3 patients with fracture non-union with varus misalignment at the end of 9 months after operative periprosthetic fracture management. It was treated with autologous bone graft and showed union after 3 months. Thus, bone grafting maybe used as a handy tool for treating delayed union/ non-union whenever necessary. Functional and radiological outcome depends not only on the accurate reduction of the fractures but also the pre-fracture status of the patient as well as operative method and post-operative rehabilitation.

In 2002, Matthew R. Bong et al [17] compared LISS and retrograde IM nailing in periprosthetic fractures after TKR. These results suggested that the retrograde-inserted nail may provide greater stability for the management of periprosthetic supracondylar femur fractures. In 2007, A. Kumar et al [19] studied supracondylar nailing of periprosthetic fractures above TKR in 10 patients. They concluded that supracondylar nailing, despite some limitations, is a satisfactory method of treatment for a majority of displaced periprosthetic fractures above well-fixed total knee arthroplasties.

Thus intramedullary nailing is becoming a method of choice for treatment of fractures at a relatively proximal level due to good results and relatively fewer complications.

In September 2010, Peter Bobak et al [22] studied pericemented nailing using an IM nail augmented with PMMA cement in 5 patients. They showed that nailed cementoplasty is proposed as a salvage procedure in octogenarians unfit for lengthy interventions. In October 2010, Alexandros E. Beris et al [23] reported 3 cases of periprosthetic fractures after total knee replacement treated with Ilizarov external fixator followed-up for 3 years. Uncomplicated fracture healing with lower extremity excellent alignment was achieved in 12 weeks after surgery.

The ultimate goal of management is to restore anatomical alignment, achieve stable fixation and early mobilization. If the prosthesis or implant is Loose, or Bone Quality is Poor - then the implant should be revised. If the prosthesis or implant is Stable and Bone Quality is Adequate for Fixation - then the implant should be retained while the fracture is fixed following standard principles. However, short duration of follow up and small number of patients is major limiting factor of this study.

CONCLUSION

This is a retrospective study of cases of periprosthetic fractures that occurred between period of January 2004 to December 2010. The total incidence of the periprosthetic fracture in operated case of TKR in our study was 0.58 %. Most of the patients fell in R2 category of Rorabeck's classification which is displaced supracondylar shaft femur fracture. DFLP is now the preferred method for the ORIF for distal lying fractures. 6 out of 20 operated cases required some or the other form of reintervention after primary management of periprosthetic fracture which increased the

duration of hospitalization ranging from 5-15 days with an average increase of 6 days as compared to the average duration without any re-intervention. As per radiological assessment, out of 23, 19 had primary union, 2 had union after bone grafting while 2 had nonunion. The average reduction in the knee score after periprosthetic fracture is 20.53%. Good results for periprosthetic fracture can be obtained if proper and timely intervention is done keeping into account the other co morbid conditions.

REFERENCES

1. Dennis DA: Periprosthetic fractures following total knee arthroplasty. Instructional Course Lectures, J Bone Joint Surg Am, 2001, 83 A:1, 120-130
2. Rorabeck CH, Taylor JW: Periprosthetic fractures of the femur complicating total knee arthroplasty, Orthop Clin North Am 30:265-277, 1999
3. Aaron RK, Scott R: Supracondylar fracture of the femur after total knee arthroplasty. Clin Orthop 219:135-139, 1987
4. Culp RW, Schmidt RG, Hanks G, et al: Supracondylar fracture of the femur following prosthetic knee arthroplasty. Clin Orthop 222:212-222, 1987
5. Ritter MA, Keating EM, Faris PM, et al: Rush rod fixation of supracondylar fractures above total knee arthroplasties. J Arthroplasty 10:213-216, 1995
6. Jabczynski FF, Crawford M: Retrograde intramedullary nailing of supracondylar femur fracture above total knee arthroplasty. A new preliminary report of four cases. J Arthroplasty 10:95 - 101, 1995
7. Cain PR, Rubash HE, Wissinger HA, et al: Periprosthetic femoral fractures following total knee arthroplasty. Clin Orthop 208:205- 214, 1986
8. Schmidt AH, Kyle RF: Treatment of complex fractures. Orthop Clin North Am 33:1, 143 - 152, 2002
9. Yoshino N, Takai S, Watanabe Y, et al: Primary total knee arthroplasty for

- supracondylar/condylar femoral fracture in osteoarthritic knees. *J Arthroplasty* 16:4,471-475 2001
10. Reis MD: Prophylactic intramedullary femoral rodding during total knee arthroplasty with simultaneous femoral plate removal. *J Arthroplasty* 13:6, 1998
 11. Scott RD: Anterior femoral notching and ipsilateral supracondylar femur fractures in total knee arthroplasty. *J Arthroplasty* 3(4):381, 1988
 12. Markkunousiainen, MD, FRCS(C). periprosthetic fractures: current concepts. 2010 OTA Annual Meeting, Baltimore MD
 13. Short WH, Hootnickdr, Murray DG. Ipsilateral supracondylar femur fractures following knee arthroplasty. *Clin Orthop Relat Res* [1981(158):111-6]
 14. Sisto DJ, Lachiewicz PF, Insall JN. Treatment of supracondylar fractures following prosthetic arthroplasty of the knee. *Clin Orthop* 1985, 196, p: 265-272
 15. Healy WL, Siliskijm, Incavosj. Operative treatment of distal femoral fractures proximal to total knee replacements. *J Bone Joint Surg Am* [1993, 75(1):27-34]
 16. David H. Sochart, Kevin Hardinge. Nonsurgical management of supracondylar fracture above total knee arthroplasty. *J Arthroplasty*, Volume 12, Issue 7, Pages 830-834, October 1997
 17. Matthew R. Bong, Kenneth A. Egol, Kenneth J. Koval, F. J. Kummer, Edward T. Su, Jordi Bayer, And Paul E. Di Cesare. Comparison of the LISS and a Retrograde-Inserted Supracondylar Intramedullary Nail for Fixation of a Periprosthetic Distal Femur Fracture Proximal to a Total Knee Arthroplasty. *J Arthroplasty* Vol. 17 No. 7 2002
 18. Mark P. Figgie, Victor M. Goldberg, Harry E. Figgie III, Mark Sobel. The results of treatment of supracondylar fracture above total knee arthroplasty. *J Arthroplasty* Volume 5, Issue 3, Pages 267-276, September 1990
 19. A. Kumar, M. Catre, P. Weiler, S. Butt. Supracondylar nailing of periprosthetic fractures above total knee arthroplasties. *Journal of Orthopaedics and Traumatology*, Dec 2007, Volume 8, Issue 4, 177 - 181
 20. Diego Herrera, Philip J Kregor, Peter Cole, Bruce Levy, Anders Jönsson, Michael Zlowodzki. Treatment of acute distal femur fractures above total knee arthroplasty-Systematic review of 415 cases (1981–2006). *Acta Orthopaedica* 2008; 79 (1): 22–27
 21. Gujarathi N, Putti AB, Abboud RJ, Maclean JG, Espleyaj, Kellett CF. Risk of periprosthetic fracture after anterior femoral notching. *Acta Orthop.* 2009 Oct; 80(5):553-6.
 22. Peter Bobak, Ioannis Polyzois, Simon Graham, Zakareya Gamie, Eleftherios Tsiridis. Nailed Cementoplasty: A Salvage Technique for Rorabeck Type II Periprosthetic Fractures in Octogenarians. *J Arthroplasty*; Volume 25, Issue 6, Pages 939-944, September 2010
 23. Berisalexandros E; Lykissasmarios G; Siorosvasileios; Mavrodontidisalexandros N; Korompiliasanastasios V. Femoral periprosthetic fracture in osteoporotic bone after a total knee replacement: treatment with Ilizarov external fixation. *The J Arthroplasty* 2010; 25(7):1168.e9-12.
 24. Platzer Patrick; Schuster Rupert; Aldria n Silke; Prosquill Stella; Krumboeck Anna; Zehetgruber Isabella; Kovar Florian; Schwameis Katrin. Management and Outcome of Periprosthetic Fractures after Total Knee Arthroplasty. *J Trauma* 68 (6): 1464-70 (2010)
 25. Delpont PH, Van Audekercke R, Martens M, Mulierjc (1984). Conservative treatment of ipsilateral supracondylar femoral fracture after total knee arthroplasty. *J Trauma* 24:846–849
 26. Major Scott B. Shawen, Major Philip J. Belmont., Lieutenant Colonel (p) William R. Klemme, L.D. Timmietopoleski, Lieutenant Colonel

- John S. Xenos, Major Joseph R. Orchowski, MD. Osteoporosis and Anterior Femoral Notching in Periprosthetic Supracondylar Femoral Fractures: a biomechanical analysis. J Bone Joint Surg Am volume 85-A · Jan 2003
27. Edward T. Su, Erik N. Kubiak, Hargovind Dewal, Rudi Hiebert, Paul E. Di Cesare. A Proposed Classification of Supracondylar Femur Fractures above Total Knee Arthroplasty. J Arthroplasty. Volume 21, Issue 3, Pages 405-408, April 2006
28. Paraschou S, Flegas P, Anastasopoulos H, Dionellis P, Papapanos A, Alexopoulos J; Results of treatment of periprosthetic supracondylar femoral fractures above total knee arthroplasty. EEXOT Volume 61, (1):59-64, 2010
29. Hari P. Bezwada, Phillip Neubauer, John Baker, Craig I. Israelite, Norman A. Johanson; Periprosthetic Supracondylar Femur Fractures Following Total Knee Arthroplasty. J Arthroplasty Vol. 19 No. 4 2004
30. Moran MC, Brick GW, Sledge CB: Supracondylar femoral fracture following total knee arthroplasty. Clin Orthop 324:196-209, 1996
31. Zalzal P, Backstein D, Gross AE, Papini M. Notching of the anterior femoral cortex during total knee arthroplasty characteristics that increase local stresses. J Arthro 2006; 21: 737-743.
32. Lesh ML, Schneider DJ, Deol G, et. al. The consequences of anterior femoral notching in total knee arthroplasty. A biomechanical study. J Bone Joint Surg Am 2000;82-A:1096–101.

How to cite this article: Gandhi RR, Purohit S, Bhalodia HP et. al. Study of periprosthetic supracondylar femur fractures in operated cases of TKR: incidence and outcome. Int J Health Sci Res. 2014;4(2):98-108.

International Journal of Health Sciences & Research (IJHSR)

Publish your work in this journal

The International Journal of Health Sciences & Research is a multidisciplinary indexed open access double-blind peer-reviewed international journal that publishes original research articles from all areas of health sciences and allied branches. This monthly journal is characterised by rapid publication of reviews, original research and case reports across all the fields of health sciences. The details of journal are available on its official website (www.ijhsr.org).

Submit your manuscript by email: editor.ijhsr@gmail.com OR editor.ijhsr@yahoo.com