



Case Report

## Isolated Lingual Cysticercosis: A Report of Three Cases and Review of Literature

Deb K. Boruah, Skandesh B.M., Arjun Prakash, Manupratap N., Vinay Kumar DP

Department of Radiodiagnosis, Assam Medical College and Hospital, Dibrugarh, Assam, India.

Corresponding Author: Skandesh B.M

Received: 28/10/2014

Revised: 20/11/2014

Accepted: 27/11/2014

### ABSTRACT

**Introduction:** Cysticercosis is caused by the larval stage of *Taenia solium*, the pork tapeworm. It has a relatively high prevalence in developing countries because of the co-existence of poor sanitary conditions and domestic pig raising. However lingual cysticercosis is a very rare occurrence even in countries with very high prevalence of cysticerci infections.

**Case presentation:** We report three cases of isolated lingual cysticercosis after excluding intracranial or orbital cysticercosis with clinical, radiological and ophthalmological examinations. Diagnosis of lingual cysticercosis was established by the characteristic appearances on Ultrasonography (USG) and Magnetic Resonance Imaging (MRI).

**Conclusion:** USG and MRI are excellent diagnostic tools to establish a diagnosis of lingual cysticercosis and helps in differentiating from other cystic lesions of tongue.

**Keywords:** Cysticercus cellulosae, scolex, Magnetic Resonance Imaging, 3D CISS.

### INTRODUCTION

Cysticercosis is a potentially fatal parasitic disease caused by the larva (cysticercosis cellulosae) of tapeworm *Taenia solium*.<sup>[1]</sup> The larva of *Taenia solium* form cysts commonly in the brain, meninges and eyes, which together constitute 86% of the cases.<sup>2</sup> Few cases are located in the muscles, heart, lungs and peritoneum. Cases in the maxillofacial region, including the tongue and cheek are rarely reported.<sup>[2-4]</sup> Lingual cysticercosis is rare and not suspected for an isolated swelling over the tongue and produces a diagnostic dilemma for the clinicians and hence imaging play an

important role in establishing the diagnosis.<sup>[5]</sup>

### CASE REPORT

#### Case 1

A 40yr old male patient presented with a painless nodule over inferior aspect of anterior third of tongue. On examination there was no visible external swelling, however on digital palpation, a firm, non tender nodule was noted. USG was done in Siemens Acuson Antares Machine using a high frequency 7.5 MHz probe. It revealed a well defined, oval to elliptical hypoechoic thin walled cystic lesion with an eccentric hyperechoic scolex. (Figure 1A and B).

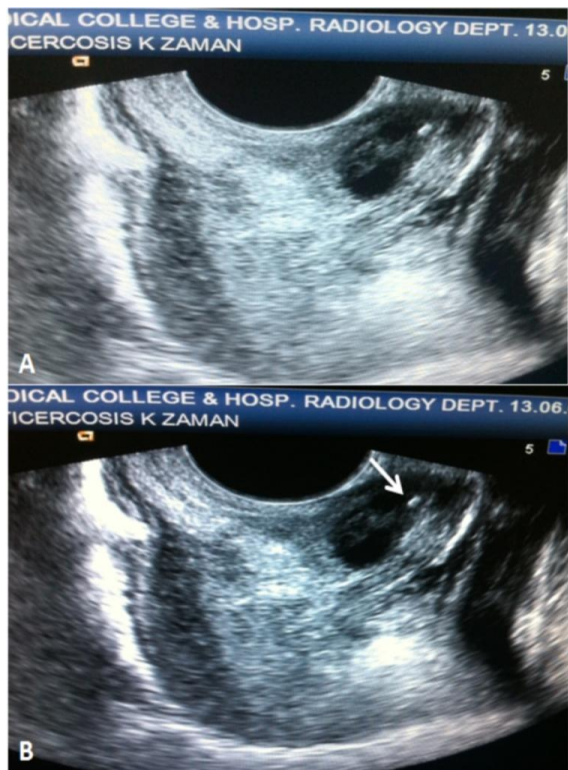

Figure 1 (A, B): USG of anterior tongue revealed a well defined, ovoid thin walled cystic lesion with an eccentric hyperechoic scolex (arrow).

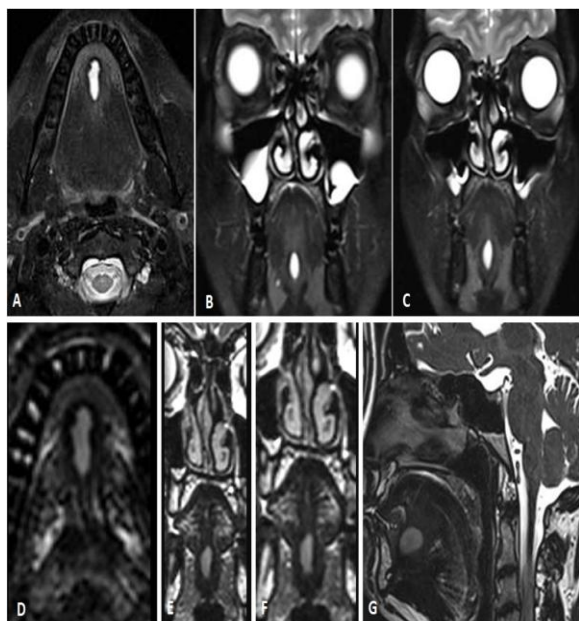


Figure 2 (A- G): Axial (A) and Coronal (B,C) T2FS MR images at the level of anterior tongue revealed a well defined hyperintense midline elliptical cystic lesion over inferior aspect of anterior third of tongue with an eccentric small hypointense scolex, which was well appreciated on axial (D) Coronal (E, F) and Sagittal (G) 3D-ClISS images.

The patient was subjected to MRI using 1.5 Tesla Siemens Magnetom Avanto B15 System (Made in Germany). MRI revealed a midline elliptical cystic lesion which was hypointense on T1weighted (T1W) and hyperintense on T2 weighted (T2W) images in inferior aspect of anterior third of tongue involving the midline lingual septum. A small T2 hypointense eccentrically located scolex was identified, which was well demonstrated on 3D ClISS (Constructive Interference in Steady State) images. (Fig.2A-G). No other cysticercus lesions were noted in the brain, orbital globe or extra-ocular muscles on MRI.

The patient underwent treatment with tablet Albendazole 400 mg twice daily for 21 days. A follow up USG and MRI done 2 months later revealed complete resolution of the cysticercus lesion. (Figure 3A-C)

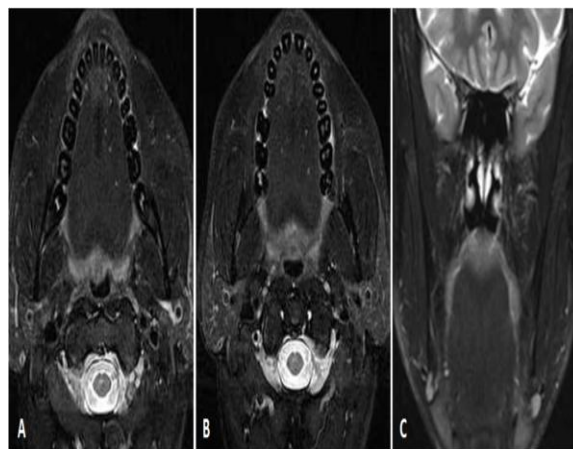


Figure 3 (A-C): Follow up MRI after 2 months; Axial (A, B) and Coronal (C) T2FS MR images of the same patient (as in Figure 2) after 21 days course of Albendazole showed complete resolution of the cystic lesion.

### Case -2

A 12 years old female presented with complaint of feeling a swelling over tongue during swallowing. On examination, no visible swelling was noted externally as well as on digital palpation.

An initial USG scan was not able to localize the lesion. MR imaging revealed a

small oval shaped T1 hypointense and T2 hyperintense cystic lesion in posterior third of tongue in right paramedian location along the plane of superior longitudinal muscle (intrinsic muscle). An eccentric T2 hypointense scolex was identified within the cystic lesion (Figure 4 A-D). MRI scan of brain and orbit did not reveal any other cysticercus lesion. The patient was treated with tablet Albendazole 400 mg twice daily for 21 days. A follow up MRI was done 2 months later, which revealed complete resolution of the cysticercus lesion.

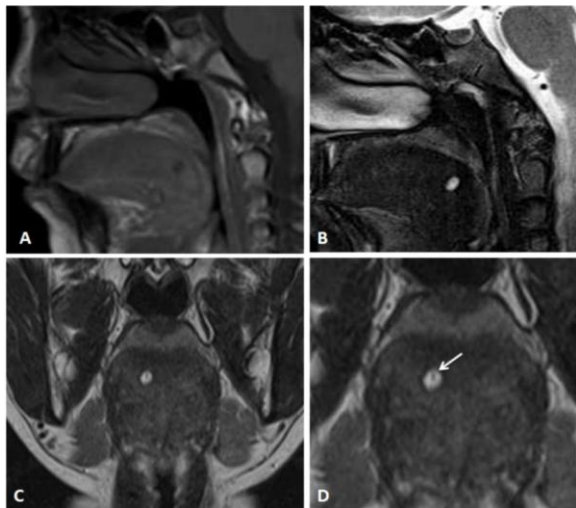


Figure 4 (A-D): Sagittal T1 (A) and T2FS (B) and Coronal T2W (C, D) MRI images showed a small oval shaped T1 hypointense and T2 hyperintense cystic lesion in the posterior third of tongue in the right paramedian location along the plane of superior longitudinal muscle with an eccentric T2 hypointense scolex (arrow) within.

### Case-3

A 30 yr old female patient presented with a painless nodule over inferior aspect of anterior third of tongue. A firm, non tender nodule was noted on digital palpation. USG revealed a well defined, oval to elliptical hypoechoic thin walled cystic lesion with an eccentric hyperechoic scolex. (Figure 5 A, B). CT scan of brain and orbit did not show any other cysticercus lesions. The patient underwent excisional biopsy, followed by Histopathological examination

(HPE), which revealed larval stage of *Taenia solium* (Figure 6).

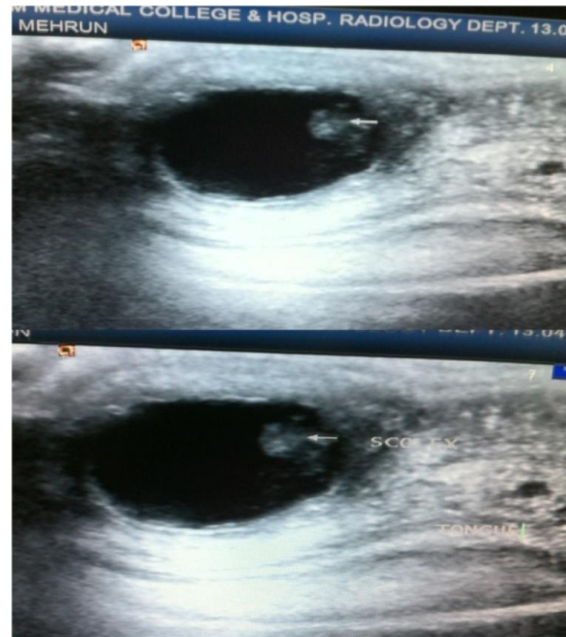


Figure 5 (A, B): USG of anterior tongue revealed a well defined ovoid cystic lesion in the dorsum of anterior third of tongue which showed an eccentric hyperechoic scolex within.

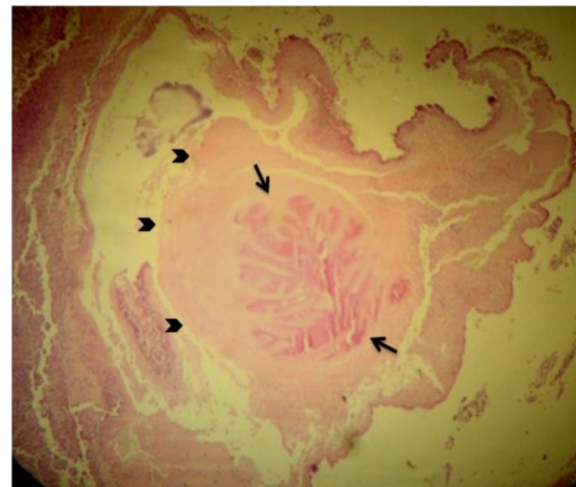


Figure 6: HPE image showed the outer cyst wall (arrow heads), consisting of undulating tegument covered with microvilli and the central invaginated scolex (straight arrows) suggestive of larval stage of *Taenia solium*. (Hematoxylin & Eosin stain; 10x).

### DISCUSSION

Cysticercosis is the result of infestation with the larval stage of tapeworm (*Taenia solium*). Aristophanes and Aristotle in 3rd century BC first described cysticercosis in pigs. [1] Tapeworm

infestation is common in developing countries where the combination of rural society, crowding and poor sanitation allows greater contact between humans and pigs and thus more opportunities for faecal contamination of food and water. Latin America, Southern Africa, India, Southeast Asia and Eastern Europe are the most frequent locations of occurrence. [4,6-8] It is the most common parasitic disease worldwide, with an estimated prevalence of more than 50 million individuals infected. [9]

The pork tapeworm (*Taenia solium*) can cause two distinct forms of infection. The form that develops depends on whether humans are infected with adult tapeworms in the intestine (Taeniasis) or with larval forms in the tissues (cysticercosis). Humans are the only definitive hosts for *T. solium*; pigs are the usual intermediate hosts, although dogs, cats and sheep may harbour the larval forms. On reaching the alimentary canal of the intermediate host, these eggs rupture and oncospheres are liberated. They penetrate the gut wall and via the systemic circulation are lodged in different organs and muscles of the intermediate host. Here, they develop into larvae referred to as cysticercosis cellulosae especially in subcutaneous tissue, striated muscles, brain and ocular tissue. [2,7,8]

Cysticercosis of the oral cavity is an uncommon presentation of the infection even in endemic areas. Besides the tongue, other sites in the oral cavity include buccal mucosa and lips. Only few cases of oral cysticercosis have been reported in the literature. Among the oral lesions the most frequently involved sites were tongue (42.15%), followed by the lips (26.15%) especially the lower lip and the buccal mucosa (18.9%). [10] Most cases of oral cysticercosis appear as asymptomatic submucosal nodules that resemble mucus retention cyst or benign mesenchymal neoplasm. [11] The usual patient complaint is

a swelling, although pain is not a frequent feature, it has been reported in secondarily infected cases. [12] It was suggested that lesion on the tongue could interfere with movement, causing discomfort during speaking and eating. [3]

In most cases, the diagnosis is not suspected on clinical grounds in view of rarity of the site of involvement. Definitive diagnosis requires visualization of the cysticercus in an involved tissue by USG, CT, MRI scan or HPE. [4,7] A combination of ultrasound and MRI increases the diagnostic confidence. [13]

High-frequency USG has become relatively inexpensive and is a readily available and reliable diagnostic modality for the diagnosis of soft tissue cysticercosis. The most common USG appearance of soft tissue cysticercosis is that of an abscess with an eccentrically situated typical cyst with a scolex within. [14-16] The second most common appearance was that of a typical cysticercosis cyst with a scolex within and surrounding mild edema but no abscess. This was observed in our cases. The least common appearance was that of an irregular cyst with no scolex within but with minimal fluid surrounding the cyst on one side indicating leakage of fluid. [14,16]

MRI is also used to diagnose soft tissue cysticercosis, since many patients with soft tissue swelling often go directly for MRI. [16-18] Cysticercosis is seen as a cystic lesion that appears hyperintense on T2W and hypointense on T1W images. The scolex is also appreciated as a tiny T2 hypointense central or eccentric speck within the T2 hyperintense cyst. [18] High resolution and heavily T2 weighted sequence like 3D CISS (Siemens) or 3D FIESTA (General Electronics) sequence having superb spatial resolution and high signal to noise ratio helps in identification of cysticercus cyst and the scolex.

MRI assess the degree of infection and exact plane of lodgement of cyst in soft tissues. It well visualizes the perilesional edema and the degenerative changes of the parasite. Findings may differ according to the growth stage of parasite and host's immune response. [19] Demonstration of the characteristic appearance on MRI is considered an absolute indication for diagnosis of cysticercosis which was demonstrated in our cases. Post-contrast peripheral rim enhancement is also a characteristic feature of a cysticercus cyst. [20] However, Gadolinium injection seems to be of little diagnostic value, especially when a clear cyst with scolex is seen. [13] Specific criteria for diagnosis of cysticercosis have been proposed and include absolute as well as major and minor criteria. MR imaging with a characteristic lesion is an absolute criteria, and a highly suggestive lesion on MRI is a major criterion. ELISA and a lesion responsive to antiparasitic therapy are minor criteria. [20] Another characteristic feature of these lesions is the typical orientation of cyst along the direction of muscle fibers, and they are usually oval or elliptical in shape. [21]

The main entities to be considered in differential diagnosis of lingual cystic lesion are mucus retention cyst, epidermoid cyst, lymphangioma, foregut duplication cyst and thyroglossal duct cyst. Mucus retention cysts show low to intermediate signal on T1W and high signal on T2W images depending on its protein content. [22] Epidermoid cyst shows diffusion restriction on DWI with variable ADC value. Lymphangioma appears as multilocular masses with high signal on T1W and T2W images with fluid-fluid levels if complicated by hemorrhage. Foregut duplication cysts are usually seen in neonates with signal intensity varying depending on its protein content. [22] Thyroglossal duct cyst in tongue appears as

a midline cystic lesion with signal intensity varying depending on its content but is usually bright on both T1 and T2W images. [23]

Histopathological examination makes up a diagnosis of cysticercosis by the detection of a cystic space containing the cysticercus cellulosae. The scolex has four suckers and double crown of rostellar hooklets. A duct like invaginated segment, lined by a homogenous anhistic membrane, comprises the caudal end. The eosinophilic membrane that lines the capsule is double layered, consisting of an outer acellular and inner sparsely cellular layer. [24]

Management of cysticercosis is multidimensional. The treatment depends on symptoms and accessibility of the lesion. Neurocysticercosis and multiple cysts are treated with drugs like Praziquantel and Albendazole. [25] Treatment of choice in a solitary accessible lesion is surgical excision. [25,26]

## CONCLUSION

It is important to consider the diagnosis of cysticercosis in a solitary cystic lesion of tongue in people living in an endemic area. Awareness of this rare possibility is important as this might prevent unnecessary surgery. Evaluating with USG and MRI is an important tool not only for diagnosis but also for follow up. Application of heavily T2 weighted sequences like 3D CISS helps in better delineation of the characteristic features of lingual cysticercus cyst with scolex and also helps to differentiate it from other cystic lesions of tongue.

## REFERENCES

1. Richa, Ray JG, Pattanayak S, Vibha. An asymptomatic tongue nodule. Contemp Clin Dent 2012;3:464-6

2. Pandey SC, Pandey SD. Lingual cysticercosis. *Indian J Plast Surg* 2005; 38:160-1.
3. Sharma AK, Misra RS, Mukherjee A, Ramesh V, Jain RK. Oral Cysticercosis. *Int J Oral Maxillofac Surg* 1986;15:349-51.
4. Gupta SC, Gupta SC. Cysticercosis of the tongue. *Ear Nose Throat J* 1995; 174:177-8.
5. Kinger A, Kawatra M, Choudhary TS. Case of lingual cysticercosis and review of literature. *J Lab Phys* 2012;:56-8.
6. Saran RK, Rattan V, Rajwansi A, Nijkawan R, Gupta SK. Cysticercosis of the oral cavity: Report of five cases and a review of literature. *Int J Paediatr Dent* 1998;8:273-8.
7. Gadbail AR, Korde S, Wadhwan V, Chaudhary M, Patil S. Oral cysticercosis: report of two cases with review of literature. *Oral Surgery* 2010;3:51-6.
8. Jain RK, Gupta OP, Aryya NC. Cysticercosis of the tongue. *J Laryngol Otol* 1989;103:1227-8.
9. Garcia HH, Del Brutto OH. Cysticercosis Working Group in Peru. Neurocysticercosis: updated concepts about an old disease. *Lancet Neurol* 2005; 4:653-61.
10. Agrawal Ranjan, Kumar Mukta. Isolated lingual cysticercosis. *Indian Journal of Medical specialities* Jul 2012; 3(2):29
11. Delgado-Azañero WA, Mosqueda-Taylor A, Carlos-Bregni R, Del Muro-Delgado R, Díaz-Franco MA, Contreras-Vidaurre E. Oral cysticercosis: A collaborative study of 16 cases. *Oral Surg Oral Med Oral Pathol Oral Radiol Endod.* 2007; 103:528-33.
12. Mishra Y.C, Nadkarni N. Oro-Facial Cysticercosis. *Ann. Dent* 1988; 47: 23-25.
13. Jankharia BG, Chavhan GB, Krishnan P, Jankharia B. MRI and ultrasound in solitary muscular and soft tissue cysticercosis. *Skeletal Radiol* 2005; 34:722-726
14. Vijayaraghavan SB. Sonographic appearances in cysticercosis. *J Ultrasound Med* 2004; 23:423-7.
15. Sidhu R, Nada R, Palta A, Mohan H, Suri S. Maxillofacial Cysticercosis - Uncommon appearance of a common disease. *J Ultrasound Med* 2002; 21:199-202.
16. Asrani A, Morani A. Primary sonographic diagnosis of disseminated muscular cysticercosis. *J Ultrasound Med* 2004; 23:1245-8.
17. Jhankaria BG, Chavhan GB, Krishnan P, Jhankaria B. MRI and ultrasound in solitary muscular and soft tissue cysticercosis. *Skeletal Radiol* 2005; 34:722-6.
18. Tripathy SK, Sen RK, Sudes P, Dhatt S. Solitary cysticercosis of deltoid muscle in a child: The diagnostic dilemma and case report. *J of Orthopaedics* 2009; 6:e11.
19. Holzapfel BM, Schaeffeler C, Banke IJ, Waldt S. Case report: A 37-year-old man with a painless growing mass of the thorax. *Clin Orthop Relat Res* 2010; 468:1193-98.
20. Del Brutto OH, Wadia NH, Dumas M, Cruz M, Tsang VC, Schantz PM. Proposal of diagnostic criteria for human cysticercosis and neurocysticercosis. *J Neurol Sci.* 1996; 142:1-6.
21. Tripathy SK, Tahasildar N, Sen RK, Akkina N, Hampannavar A. Role of ultrasonography and magnetic resonance imaging in the diagnosis of intramuscular cysticercosis. *Skeletal Radiol* 2012; 41:1061-66
22. Houshmand G, Hosseinzadeh K, Ozolek J. Prenatal magnetic resonance imaging (MRI) findings of a foregut duplication cyst of the tongue. *Ultrasound Med.* 2011;30:843-850.
23. King AD, Ahuja AT, Mok CO, Metreweli C. MR imaging of thyroglossal duct cysts in adults. *Clin Radiol.* 1999;54:304-308.
24. Patel K, Shah M, Patel B and Doshi N (2011). Subcutaneous oral

- cysticercosis. National Journal of Community Medicine 2(2) 311-313.
25. Saran RK, Rattan V, Rajwanshi A, Nijkawan R, Gupta SK. Cysticercosis of the oral cavity: Report of five cases and a review of literature. Int J Pediatr Dent. 1998; 8:273–8.
26. Mukesh S, Kacker SK, Kapilla K. Cysticercosis of the oral cavity- A clinicopathological study of ten and a half years. J Indian Dent Asso 1986; 58:257–9.

How to cite this article: Boruah K, Skandesh BM, APrakash A et. al. Isolated lingual cysticercosis: a report of three cases and review of literature. Int J Health Sci Res. 2014;4(12):387-393.

\*\*\*\*\*

#### **International Journal of Health Sciences & Research (IJHSR)**

#### **Publish your work in this journal**

The International Journal of Health Sciences & Research is a multidisciplinary indexed open access double-blind peer-reviewed international journal that publishes original research articles from all areas of health sciences and allied branches. This monthly journal is characterised by rapid publication of reviews, original research and case reports across all the fields of health sciences. The details of journal are available on its official website ([www.ijhsr.org](http://www.ijhsr.org)).

Submit your manuscript by email: [editor.ijhsr@gmail.com](mailto:editor.ijhsr@gmail.com) OR [editor.ijhsr@yahoo.com](mailto:editor.ijhsr@yahoo.com)