



Case Report

Diagnosis of Gouty Tophi on Fine Needle Aspiration in a Clinically Unsuspected Case

Deepti Vijay Mankar¹, Nanda Jaywant Patil²

¹Lecturer, ²Associate Professor,
Department of Pathology, Krishna Institute of Medical Sciences, Karad, Maharashtra.

Corresponding Author: Deepti Vijay Mankar

Received: 15/10/2014

Revised: 13/11/2014

Accepted: 18/11/2014

ABSTRACT

Background: Demonstration of monosodium urate crystals in synovial fluid or biopsy is the gold-standard for the diagnosis of gouty arthropathy. The less invasive Fine Needle Aspiration Cytology (FNAC) of gouty tophi can be reliably and safely used for diagnosis.

Case Report: We present a clinically unusual case of gouty arthritis in a sixty-two year old chronic alcoholic male, with multiple subcutaneous swellings of varying duration over bilateral lower extremities, with no significant clinical history. Radiological and laboratory investigations were non-contributory.

FNAC of the swellings yielded a chalky-white amorphous aspirate which revealed slender, needle-shaped, refractile crystals in Haematoxylin & Eosin and Leishman stained smears on light microscopy and brilliant negative birefringence on polarizing microscopy, confirming the presence of monosodium urate. Thus, a diagnosis of gouty tophi was made on cytology.

Conclusion: FNAC is a simple, safe, cost-effective, rapid and reliable investigation in the diagnosis of gouty tophi. It should be considered as an alternative to the more invasive synovial biopsy. Also, the pathologist should be aware of cytological features of gouty tophi, especially in cases with unusual clinical presentation.

Keywords: Gouty tophi, FNAC diagnosis, monosodium urate crystals.

INTRODUCTION

Demonstration of monosodium urate crystals in synovial fluid or biopsy is the gold-standard for the diagnosis of gouty arthropathy. [1] The less invasive Fine Needle Aspiration Cytology (FNAC) of gouty tophi can be reliably and safely used for diagnosis.

CASE REPORT

A sixty-two year old, thin-built chronic alcoholic male presented with multiple subcutaneous swellings of varying duration, on bilateral lateral malleoli and dorsum of the left foot. There was no complaint of painful arthropathy, restriction of movement, paraesthesia or any other symptom associated with the swellings. The patient gave no significant drug or dietary history. His past, family, medical and personal histories were insignificant.

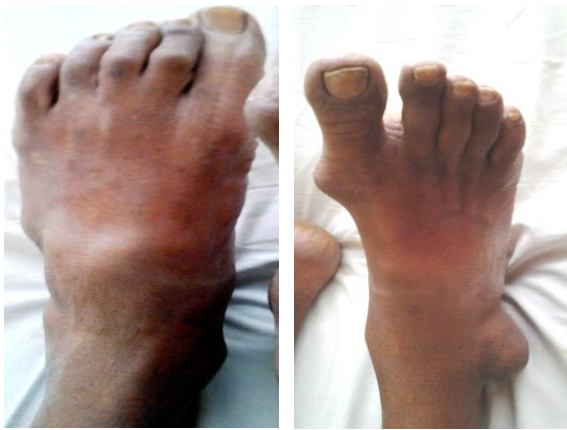

Fig.1: Photograph of subcutaneous swellings over bilateral feet.

Radiology revealed corresponding soft tissue densities without calcification and no underlying bone or joint involvement.

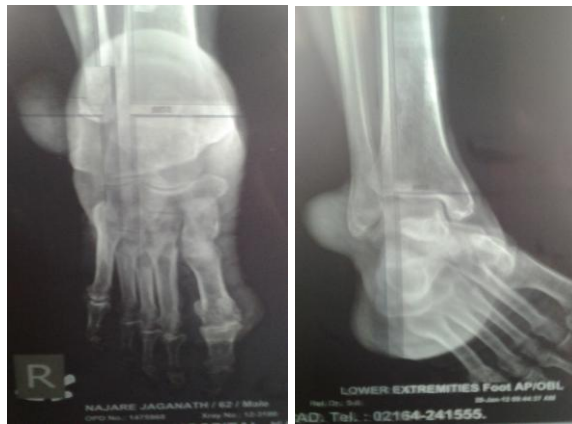

Fig.2 : X-Ray (Right Foot) in AP and Oblique views.

All laboratory investigations, including serum uric acid levels, were within normal limits.

A presumptive clinical diagnosis of neurofibroma or ganglion was made and the patient was advised FNAC of the swellings.

Multiple subcutaneous swellings, which were firm and non-tender on palpation, were aspirated. The largest of these was present over the right lateral malleolus since 5-6 years and measured 5x4x2 cm.

A chalky-white amorphous aspirate was obtained. Light microscopy of haematoxylin & eosin and Leishman stained smears revealed numerous slender, needle-shaped, refractile crystals in sheaves and scattered singly. These were admixed with many foreign - body type giant cells, some with engulfed needle-shaped crystals, histiocytes and scattered neutrophils.

The crystals showed brilliant negative birefringence on uncompensated polarizing microscopy, which confirmed the presence of monosodium urate. Thus, a diagnosis of gouty tophi was made on cytology.

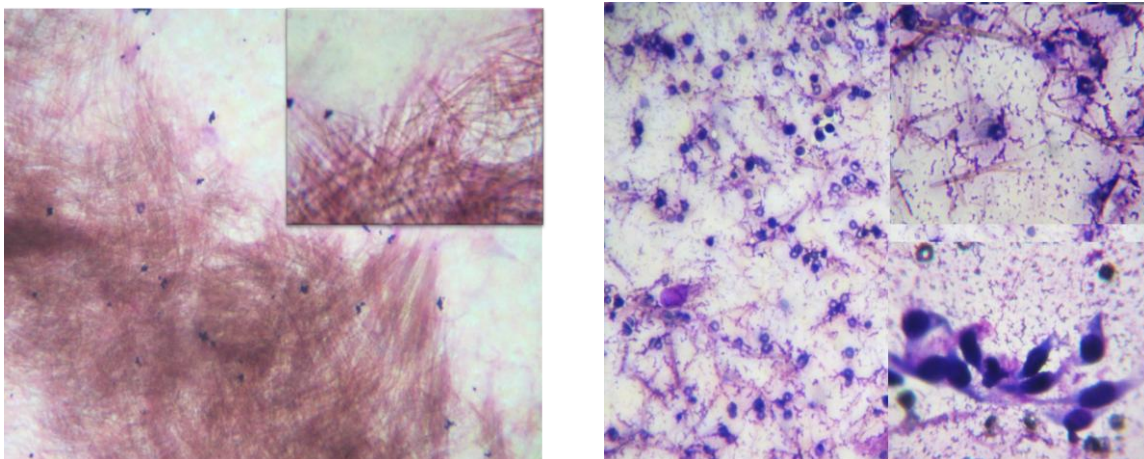


Fig.3: (a) and (b) Photomicrographs showing needle-shaped crystals arranged in sheaves and scattered singly, admixed with histiocytes and neutrophils. [(a) Haematoxylin & Eosin, 40x (Inset, 100x); (b) Leishman, 40x (Inset, 100x)].

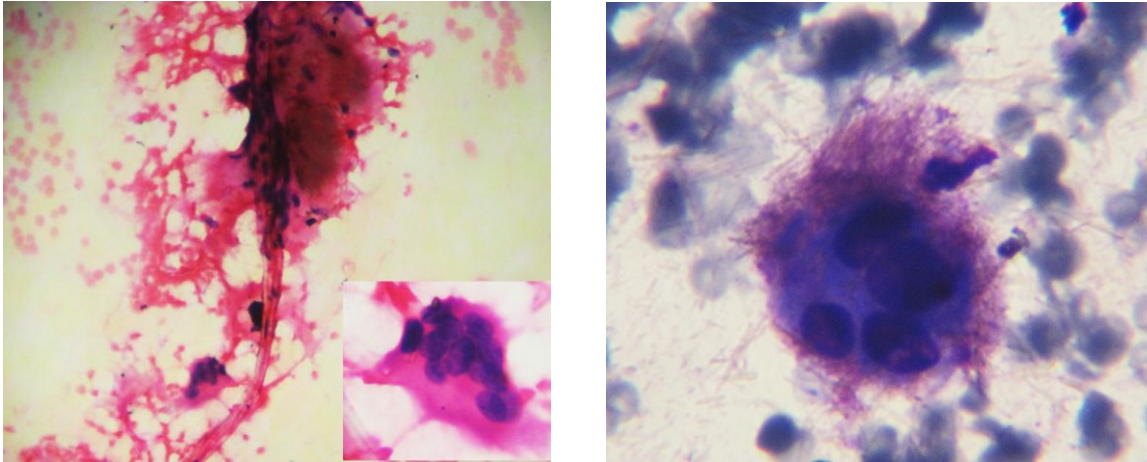


Fig.4: (a) Photomicrograph showing foreign-body type giant cells admixed with neutrophils and histiocytes. [Haematoxylin & Eosin, 100x (Inset-1000x)]; (b) Giant cell with engulfed needle-shaped crystals. [Leishman, 1000x].

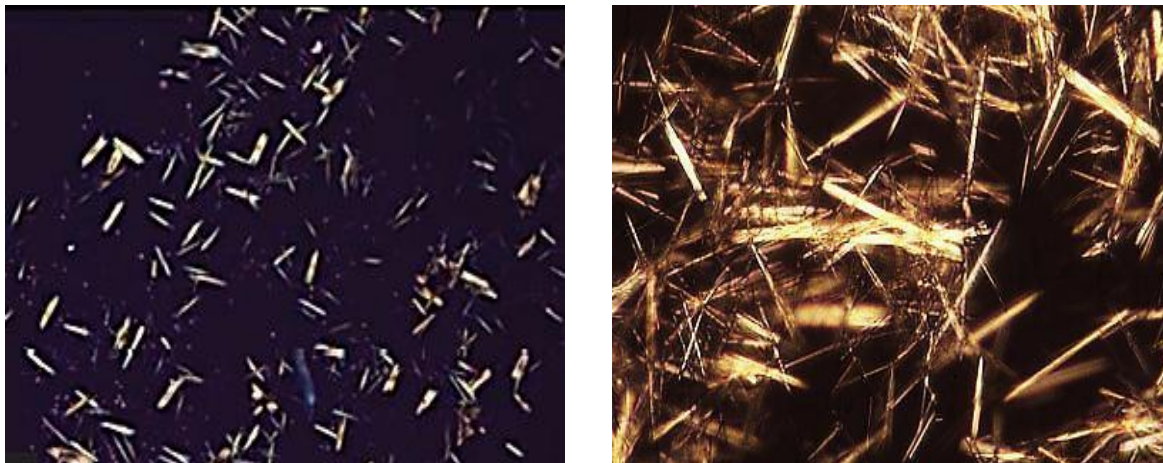


Fig.5: Photomicrograph showing brilliant negatively birefringent crystals on polarizing microscopy [(a) 40x, (b) 1000x].

DISCUSSION

Gout, a hyperuricaemic crystal-induced inflammatory arthritis is characterized by transient attacks of acute arthritis, leading to chronic arthritis with deposition of tophi, which are large aggregates of urates in joints and soft tissues. [2] The hyperuricaemia may be either primary (idiopathic, genetic or hormonal) or secondary (excessive alcohol consumption, renal insufficiency, thiazide diuretics, pyrazinamide, leukaemias, obesity, chronic lead poisoning, psoriasis etc.). [2] Gout rarely appears before 20-30 years of hyperuricaemia and runs in families. [2]

The differential diagnoses of gouty tophi include peri-articular nodules of

pseudogout (chondrocalcinosis articularis), rheumatoid arthritis, pigmented villonodular synovitis, ganglion cysts, synovial chondromatosis, tumour calcinosis and synovial sarcoma. [3]

The prevalence of gout has been on the rise in recent years, theorized to be related to increased longevity, alcohol consumption, obesity, widespread diuretic use for hypertension treatment [4] and hypothyroidism. [5]

Hyperuricemia is the most important risk factor for the development of gout. But the level of serum uric acid may be normal, especially in diabetics and alcoholics. [6]

Tophi can develop without concomitant arthritis. Iglesias et al.,

proposed the term 'gout nodulosis' to describe subcutaneous deposits of monosodium urate in the absence of gouty arthritis. [7]

Our patient had no history or clinical evidence of arthritis. He was not obese and had no systemic illness, endocrinopathy, family history or history of hyperuricaemic drug or dietary intake. His serum urate levels were normal and radiology of the lesions was inconclusive. In this unusual setting, gout as a possible diagnosis remained unsuspected.

The gold standard for diagnosis of gouty arthritis is the demonstration of urate crystals in synovial fluid or biopsy, [1] which are characteristically slender, needle-shaped and negatively birefringent on polarising microscopy. [2,3]

However, in clinical practice, this test is performed only on a minority of patients. Radiology usually provides only verification of gout via a late-stage finding of peri-articular erosion.

The crystal demonstration in alcohol-fixed cytology smears is superior to histopathology sections where crystals are more commonly lost during fixation and processing. [1]

In clinically equivocal or unsuspected cases of gout, the demonstration of monosodium urate crystals on FNAC can clinch the diagnosis. In fact, granular, chalky-white amorphous aspirate from a peri-articular nodule should prompt smear examination under polarising microscope by the cytopathologist. [1]

CONCLUSION

We cite this case because of the unusual clinical presentation and because

tophaceous gout was diagnosed on FNAC alone, which is not routine practice.

FNAC is a fast, simple, safe, non-invasive, cost-effective and reliable investigation in the diagnosis of gouty tophi and should be considered as an alternative to the more invasive synovial biopsy.

Also, a granular, chalky-white aspirate from a peri-articular nodule should prompt an investigation for gout, especially in clinically unsuspected cases.

REFERENCES

1. Rege J, Shet T, Naik L. Fine needle aspiration of tophi for crystal identification in problematic cases of gout. A report of two cases. *Acta Cytol* 2000; 44:433-6.
2. Rosenberg A. Bones, joints and soft tissue tumours. In: Kumar V, Abbas A, Fausto N, Aster J (ed). *Robbins and Cotran Pathologic basis of disease*, 8th ed, Saunders 2010; 1243-6.
3. Dodd LG, Major NM: Fine needle aspiration cytology of articular and periarticular lesions. *Cancer* 2002; 96:157-65.
4. Hunter DJ, York M, Chaisson CE, Woods R, Niu J : Recent diuretic use and the risk of recurrent gout attacks: the online case-crossover gout study. *J Rheumatol* 2006; 33:1341-5.
5. Erickson A, Enzenauer RJ, Nordstrom DM, Merenich JA. The prevalence of hypothyroidism in Gout, *Am J Med* 1994; 97:231-4.
6. McCarty DJ. Gout without hyperuricemia. *JAMA* 1994; 271:302-3.
7. Iglesias A, Londono JC, Saaibi DL, Pepa M, Lizarazo H, Gonzalez EB. Gout nodulosis: widespread subcutaneous deposits without gout. *Arthritis Care Res* 1996; 9:74-7.

How to cite this article: Mankar DV, Patil NJ. Diagnosis of gouty tophi on fine needle aspiration in a clinically unsuspected case. *Int J Health Sci Res.* 2014;4(12):379-382.
