



Original Research Article

## External and Endoscopic Dacryocystorhinostomy in Nasolacrimal Duct Obstruction: A Comparative Study

Asim Kumar Dey<sup>1\*</sup>, Ganesh Chandra Gayen<sup>2\*\*</sup>, Subhasis Jana<sup>3</sup>, Sumi Ghorai<sup>4</sup>, Ashim Sarkar<sup>5\*\*</sup>, Purban Ganguly<sup>5\*</sup>

<sup>1</sup>Associate Professor, <sup>2</sup>Assistant Professor, <sup>5</sup>MS PGT,

<sup>\*</sup>Department of Ophthalmology, <sup>\*\*</sup>Department of Otorhinolaryngology, Burdwan Medical College, Burdwan.

<sup>3</sup>Senior Resident, Department of Ophthalmology, Lions Seva Eye Hospital, Jamalpur, Burdwan.

<sup>4</sup>Assistant Professor, Department of Anatomy, Burdwan Medical College, Burdwan, India.

Corresponding Author: Subhasis Jana

Received: 28/10/2014

Revised: 17/11/2014

Accepted: 17/11/2014

### ABSTRACT

**Introduction:** Dacryocystorhinostomy (DCR) is the mainstay management of choice for Chronic Dacryocystitis. External DCR is the standard treatment procedure of choice. In the recent past it has been observed that endoscopic DCR is growing as an equally successful substitute for the management of chronic acquired naso-lacrimal duct obstruction.

**Aims:** This study intends to compare the final result of surgical management of acquired naso-lacrimal duct obstruction between external DCR and endoscopic endonasal DCR.

**Method:** This is an observational study. This study was carried out in the Ophthalmology department and Otorhinolaryngology department, Burdwan Medical College and Hospital from October 2013 to September 2014. Total 60 patients were included for DCR operation. Out of which 30 patients underwent endoscopic endonasal DCR in the department of otorhinolaryngology and 30 patients underwent external DCR in the department of ophthalmology. Data were collected and analyzed on the basis of ocular examination, lacrimal pathway, postoperative complications and finally surgical outcome. Resolution of patient's symptoms and patency of lacrimal drainage system were used to define as successful surgical outcome. Postoperatively persistent of symptoms and non patency of the lacrimal pathway were used to define as failure. Statistical analysis was done with the help of Statistical software Epi Info Version 7. P value of <0.05 was considered statistically significant.

**Results:** Total 60 patients were included in this study. 30(50%) study population were male and 30(50%) were female. Evaluation of surgical outcome showed that conventional and endoscopic endonasal DCR had nearly similar success rate. P value was more than 0.05 in respect to endoscopic endonasal DCR. Majority of the surgery were completed in between 1hour in both external and endonasal DCR. Post operative complication mainly non-patency of nasolacrimal drainage system occurred near 15% of external DCR group and 20% of those with endoscopic endonasal DCR surgery at the end of 48 weeks [p value 1.00].

**Conclusions:** Surgical outcome of both endoscopic endonasal DCR and conventional DCR for Chronic Dacryocystitis was comparable. In both types of surgeries, it was seen that the complication rate was low and comparable. Endoscopic surgery produces less external scar as compared to external DCR.

**Keywords:** outcome, dacryocystorhinostomy, endoscopic, external.

## INTRODUCTION

Dacryocystitis is the inflammation of the lacrimal sac. Spontaneous resolution does not occur without treatment. [1] Treatment of choice for this disorder is dacryocystorhinostomy (DCR). Dacryocystorhinostomy involves the establishment of an alternative pathway for drainage of tear. This pathway is established in between lacrimal sac and middle meatus of nose. Dacryocystorhinostomy (DCR) can be done either by an external approach (conventional DCR) or by an endoscope (endonasal endoscopic DCR). [2]

Toti in 1904 formerly described about the technique of external DCR. [3] Caldwell was the pioneer of the endonasal approach. All through in its beginning, this procedure was unsuccessful because of technical difficulty and lack of technology. [4] Later on Endonasal DCR gained popularity due to subsequent emergence of the nasal endoscope. [5] McDonough et al introduced the current technique of endonasal DCR. [6]

The previously published literature shows success rate of both the approaches ranges from 63% - 97%. [7,8] This wide range of success could be due to different surgical methods, patients demographic and lack of standardized procedure to measure the outcome. [9] This study intends to compare the final result of surgical management of acquired naso-lacrimal duct obstruction between external DCR and endoscopic endonasal DCR.

## MATERIALS AND METHODS

The present observational study was conducted in the department of Ophthalmology and department of otorhinolaryngology Burdwan Medical College and Hospital, Burdwan, West Bengal, India from October 2013 to September 2014. Total 60 patients were included for DCR operation. Out of which 30 patients underwent endoscopic endonasal

DCR in the department of otorhinolaryngology and 30 patients underwent external DCR in the department of ophthalmology. Patient particulars were recorded. A detail history was taken. Thorough ophthalmological and otorhinolaryngological examinations were done. Patients having symptoms of watering and discharge with evidence of regurgitation on syringing were included in the study. Patients presenting with history of previous DCR operation, obvious lower lid laxity, intranasal pathology i.e. deviated nasal septum, nasal polyp, and younger than 18 years were excluded from the study. Successful surgical outcome was defined by getting symptom free with patent lacrimal drainage system. Failure was defined as lack of symptomatic improvement and persistence of watering and/or discharge along with postoperatively non-patent lacrimal drainage system.

All operations were performed under local anesthesia. Silicon tube was inserted intra operatively in all cases of endoscopic DCR. Post operative follow up was done for a period of 48 weeks. Silicon tube was removed after 6 weeks and patency test was done in first 4 weeks, 24 weeks and 48 weeks respectively. Statistical analysis was done with the help of Statistical software Epi Info Version 7. Categorical data were expressed in percentage (%). P value of <0.05 was considered statistically significant.

## RESULTS

Total 60 patients were included in this study. 30(50%) study population were male and 30(50%) were female. In conventional DCR there were 93.33% successful surgical outcome and in endoscopic endonasal DCR it was 90%. Evaluation of surgical outcome showed that conventional and endoscopic endonasal DCR had nearly similar success rate. P value

was more than 0.05 in respect to endoscopic endonasal DCR. Majority of the surgery were completed in between 1-1.5 hours in both external and endonasal DCR [Table 1]. Complication rate was very low in both types of surgery. Post operative complication mainly non-patency of nasolacrimal drainage system occurred near 12% of external DCR group and 15% of those with endoscopic endonasal DCR surgery at the end of 48 weeks (p value 1.00) [Table 2].

Table 1: Showing duration of surgery in both external and endonasal DCR.

Duration of surgery(minutes)	External DCR(n=20)	Endonasal DCR(n=20)	P value (Fisher's Exact test)
45 minutes	5	1	P=0.194
1-1.5 hour	20	23	P=0.567
> 1.5 hour	5	6	P=1.00

(Statistically Significant p value < 0.05)

Table 2: Shows Surgical results of study population

NLP patency	External DCR (n=20)	Endonasal DCR(n=20)	P value (Fisher's Exact test)
	No(%)	No(%)	
4 Weeks	30(100%)	30(100%)	P=0.00
24 Weeks	30(100%)	28(93.33%)	P=0.491
48 Weeks	28(93.33%)	27(90%)	P=1.00

(Statistically Significant p value < 0.05)

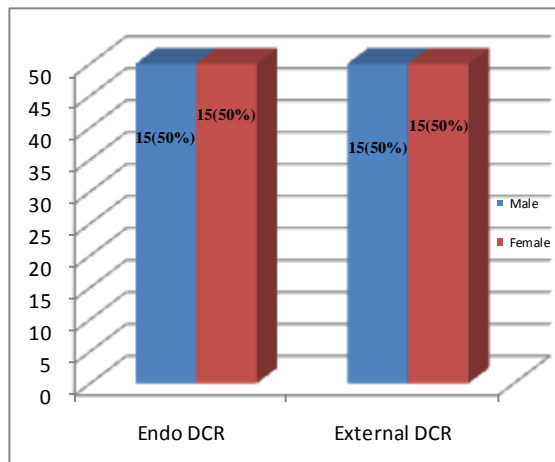


Figure 1: Showing gender distribution of endoscopic and external DCR.

## DISCUSSION

In chronic dacryocystitis, there is persistence of low grade infection in the nasolacrimal sac which ultimately comes to

end with complete nasolacrimal duct (NLD) obstruction. The treatment of choice for Chronic Dacryocystitis is DCR. [10] External DCR still remains the gold standard treatment for NLD obstruction. Direct visualization of the anatomical structures of nose in external DCR has got advantages over endoscopic DCR. But it has got some disadvantages like cutaneous scar, injury to the angular vein and medial canthal structures, lacrimal pump failure and cerebrospinal fluid (CSF) rhinorrhea. [11]

Endonasal endoscopic DCR has got some advantages over external DCR. It's popularity increases due to its equally promising outcome and cosmetic superiority. Lacrimal sac pathology can be directly visualized through the endoscopic procedure and allows immediate diagnosis and management of nasal pathology. [9] Complication of endonasal endoscopic DCR is slightly more than external DCR. Intra operative bleeding, re-stenosis of the nasolacrimal opening, and some time injury to the orbital contents is associated with this procedure. External or endoscopic DCR is only indicated when the obstruction is away from the common canaliculus. [12]

In our study, right sided involvement was found in 67.7% of the cases. This finding is correlated with previous studies. [13,14] The exact cause of dacryocystitis in the right eye was not known. In our study, the most common presenting symptom was epiphora as found in earlier studies. [14-16] Probing of nasolacrimal duct and syringing for detection of nasolacrimal duct patency was done preoperatively in the operating eye. To find out the level of obstruction in the lacrimal apparatus Jone's dye test was also performed.

In a study in Bangladesh, Khan et al., reported that for endoscopic DCR the surgical duration was higher than external DCR, which were 59.7±8.8 minutes and 54.3±5.6 minutes respectively. [9]

Hartikainen et al., showed that average duration of surgery was 38 minutes and 78 minutes for endoscopic and external DCR respectively. [17] Muscatello et al., in their study found that duration of surgery ranges from 15-110 minutes and mean time for endonasal endoscopic DCR was 30 minutes. They also conclude that, with increasing surgical skill, duration of surgery progressively decreased. [18] In this present study we found that average time require to complete the surgery was 1 hour and 1-1.5 hours for endoscopic endonasal DCR and external DCR respectively. In our study, most of the surgery was done by junior residents who do not have much surgical experience. So the time taken to complete the surgeries was comparatively longer in duration. In this study, we can conclude that duration of surgery is directly related to the surgical skill and experience of the surgeon and intra-operative bleeding. In both types of surgeries, it was seen that the complication rate was low and comparable. This finding was correlate with study done by Moras et al. [19]

We followed up our patients post operatively for 48 weeks. The surgical success rate in external and endoscopic DCR group was 100 % and 93.33% respectively after 24 weeks of follow-up period. At the end of 48 weeks of follow-up, 27(90%) out of 30 cases finally free from symptoms and had a patent pathway in endoscopic DCR. On the other hand, in external DCR it was 28 (93.33%) out of 30 cases. This difference was not statistically significant ( $P = 0.661$ ).

The success rate for endoscopic DCR was ranging from 78% to 97% in comparison to the “gold standard” external approach. [20,21] In our study surgical outcome in two groups is comparable to previously published studies worldwide. Khan et al, in their study, showed that successful surgical outcome was 73.3% with endoscopic approach as compared to 80%

with external approach. [9] Karim et al, has found similar success rate in two approaches, endoscopic DCR 82.4% versus external DCR 81.6% ( $P = 0.895$ ). [15] The study conducted by Gupta et al, reported that 90% cases of endonasal DCR had successful surgical outcome after a single procedure and it increases to 95% after revision procedure. This revision results was equal to the external approach. [22] In the study from west Bengal, Saha et al reported that surgical success rate of both the procedures were 93.3% in external DCR and 92% in endoscopic DCR after 6 month of follow up. [13] Both the above finding is nearly analogous to our study.

## CONCLUSION

From the above study, we can conclude that both external and endoscopic endonasal DCR has similar success rate and minimal complications. Yet endoscopic endonasal DCR produces no external scar. So, we suggest that endoscopic endonasal DCR should be the preferable intervention of choice for chronic dacryocystitis.

### *Limitation of the study:*

Since our study was a hospital-based study, some bias regarding patient selection exists. The duration of our study and the total sample size are short. As the surgeries were performed by different surgeons, this might have affected the final surgical outcome.

## ACKNOWLEDGEMENT

The authors of this article gratefully acknowledge the inspiration and help received from the scholars whose articles have been cited in the reference section.

## REFERENCES

1. Sihota R, Tandon R. Parsons' Diseases of the Eye. 20th Ed. New Delhi: Butterworth Heinemann Elsevier India; 2007. p.446-447.

2. Vinod Gauba V. External Versus Endonasal Dacryocystorhinostomy In A Specialized Lacrimal Surgery Center. Saudi Journal of Ophthalmology. 2014;28: 36–39.
3. Toti A. Nuovometodoconservatore di cura radicle dellesuppurazoni-croniche del saccolacrimale (Dacriocistorinostomia). Clin Mod Firenze 1904;10:385–7.
4. Caldwell GW. Two new operations for obstruction of the nasal duct, with preservation of canaliculi, and with an incidental description of a new lacrimal probe. Am J Ophthalmol 1893; 10: 189-193.
5. Stammberger H. Endoscopic endonasal surgery: concepts in treatment of recurring rhinosinusitis. Part II. Surgical technique. Otolaryngol Head Neck Surg 1986; 94(2):147–56.
6. McDonough M, Meiring JH. Endoscopic transnasal dacryocystorhinostomy. J Laryngol Otol 1989; 103:585–7.
7. Tarbet KJ, Custer PL. External dacryocystorhinostomy, surgical success, patient's satisfaction, and economic cost. Ophthalmology 1995; 102: 1065-1070.
8. Durvasula V, Gatland DJ, Endoscopic Dacryocystorhinostomy: Long term results and evolution of surgical technique. J Laryngol Otol 2004; 118: 628-632.
9. Khan MKH, Hossain MA, Hossain MJ, Al-Masud A, Rahman MZ. Comparative Study Of External And Endoscopic Endonasal Dacryocystorhinostomy For The Treatment Of Chronic Dacryocystitis. JAFMC Bangladesh. 2011; 2:15-17.
10. American Academy of Ophthalmology: BSCSC. Section-7. 2009-2010. p29.
11. Shun-Shin GA, Thurairanjan G. External dacryocystorhinostomy – an end of an era? Br J Ophthalmol 1997; 81: 716-717.
12. Kanski JJ. Clinical Ophthalmology A Systemic Approach. 7th ed. London: Butterworth Heinemann Elsevier; 2007. p.75-78.
13. Saha R, Sinha A, Phukan JP. Endoscopic versus external approach dacryocystorhinostomy: A comparative analysis. Niger Med J. 2013; 54:165–69.
14. Nichlani SS, Jagade MV, Ganeshan A. A comparative study between endoscopic and external approach dacryocystorhinostomy. Bombay Hosp J. 2010;52:189–96.
15. Karim R, Ghabrial R, Lynch TF, Tang B. A comparison of external and endoscopic endonasal dacryocystorhinostomy for acquired nasolacrimal duct obstruction. Clin Ophthalmol. 2011;5:979–89.
16. Aslam S, Awan AH, Tayyab M. Endoscopic dacryocystorhinostomy: A Pakistani experience. Pak J Ophthalmol. 2010;26:2–6.
17. Hartikainen J, Antila J, Varpula M, Puukka P, Sepp H, Grénman R. Prospective randomized comparison of endonasal endoscopic dacryocystorhinostomy and external dacryocystorhinostomy. Laryngoscope. 1998;108:1861–6.
18. Muscatello L, Giudice M, Spriano G, Tondini L. Endoscopic dacryocystorhinostomy: Personal experience. Acta Otorhinolaryngol Ital. 2005;25:209–13.
19. Moras K, Bhat M, Shreyas CS, Mendonca N, Pinto G. External dacryocystorhinostomy versus endoscopic dacryocystorhinostomy: A comparison. J Clin Diagn Res. 2011;5:182–6.

20. Smith W, Merkonidis C, Draper M, Yung M. Endoscopic dacryocystorhinostomy in warfarinized patients. Am J Otolaryngol. 2006;27:327–9.
21. Jin HR, Yeon JY, Choi MY. Endoscopic dacryocystorhinostomy: Creation of a large marsupialized lacrimal sac. J Korean Med Sci. 2006;21:719–23.
22. Gupta S, Goyal R, Thakur AS, Singh H. Conventional dacryocystorhinostomy versus endonasal dacryocystorhinostomy - a comparative study. Peoples J Sci Res. 2008;1:1–4.

How to cite this article: Dey AK, Gayen GC, Jana S et. al. External and endoscopic dacryocystorhinostomy in nasolacrimal duct obstruction: a comparative study. Int J Health Sci Res. 2014;4(12):115-120.

\*\*\*\*\*

**International Journal of Health Sciences & Research (IJHSR)**

**Publish your work in this journal**

The International Journal of Health Sciences & Research is a multidisciplinary indexed open access double-blind peer-reviewed international journal that publishes original research articles from all areas of health sciences and allied branches. This monthly journal is characterised by rapid publication of reviews, original research and case reports across all the fields of health sciences. The details of journal are available on its official website ([www.ijhsr.org](http://www.ijhsr.org)).

Submit your manuscript by email: [editor.ijhsr@gmail.com](mailto:editor.ijhsr@gmail.com) OR [editor.ijhsr@yahoo.com](mailto:editor.ijhsr@yahoo.com)