



Case Report

Unusual Presentation of Anaplastic Large Cell Lymphoma Arising in Branchial Cyst

Nagesh T Sirsath^{1*}, Lakshmaiah KC¹, Premalatha CS², D Lokanatha¹, Govindbabu K¹, Guruprasad B¹

¹Department of Medical Oncology, Kidwai Memorial Institute of Oncology, Banglore-560029, Karnataka, India.

²Department of Pathology, Kidwai Memorial Institute of Oncology, Banglore-560029, Karnataka, India.

*Correspondence Email: nagesh.sirsath@yahoo.com

Received: 7/03/2013

Revised: 01/04/2013

Accepted: 12/04/2013

ABSTRACT

Branchial cysts are epithelial cysts, which arise on the lateral part of the neck. Branchial cyst commonly presents as a solitary, painless mass in the neck. In some instances, branchial cyst patients may present with locally compressive symptoms. It is an important differential diagnosis of neck swelling and should not be confused with metastatic lymph node. Although very rare, malignancy can arise in a branchial cyst. Anaplastic large cell lymphoma (ALCL) is a CD30 positive T-cell lymphoma and accounts for approximately 2% of all non-Hodgkins lymphomas. ALK positive ALCL (ALCL, ALK+) occurs in children and young adults and 50-70% of these have extranodal involvement. It is very important to recognize ALCL at unusual extranodal sites because it is a highly treatable type of lymphoma. We herein describe a case of ALK-positive ALCL arising in a branchial cyst.

Keywords: anaplastic, lymphoma, branchial cyst.

INTRODUCTION

Branchial cleft cysts are epithelial cysts, which arise on the lateral part of the neck. Histologically the cysts are lined by squamous and occasionally respiratory epithelium. There is often robust underlying lymphoid infiltrate often with germinal centres hence they are also called lymphoepithelial cysts. Branchial cysts that undergo malignant transformation do exist, but are extremely rare. [1] Bronchogenic carcinomas and even papillary thyroid cancer have been reported to arise in branchial cyst. This is the first reported case of ALCL arising in a branchial cyst.

Anaplastic large cell lymphoma (ALCL) represents approximately 2% of all non-Hodgkins lymphomas. [2] It can present either with systemic involvement or isolated cutaneous involvement. Patients with systemic ALCL are divided into two groups, depending on the expression of a protein called anaplastic lymphoma kinase (ALK). The ALK positive subtype usually affects children and young adults. The ALK negative subtype is more commonly found in patients over 60 years of age. A significant number of ALCL cases (approximately 50-70%) have extranodal disease. [3] The commonly involved extranodal sites in decreasing order of

frequency are skin, bone, soft tissues, lung, liver, bronchus, breast and rarely GIT & CNS. [4]

Occurrence of lymphoma in a branchial cyst is not reported till date. We herein describe a case of ALK-positive ALCL arising in a branchial cyst.

CASE REPORT

A 25 years male was being evaluated at regional tuberculosis centre for progressive dyspnea, intermittent mild haemoptysis, fever and weight loss. The possibility of tuberculosis was ruled out after chest X-ray and sputum examination. The patient also had swelling on anterolateral aspect of neck since 4 months. It was soft, fluctuant and tender clinically suggestive of infected cyst. Blood

investigations and serology tests were normal. Ultrasound and X-ray neck revealed prevertebral soft tissue lesion opposite C6, C7 and T1 vertebrae causing compression of tracheal wall. Contrast enhanced computed tomography (CECT) neck showed 4.2×4.1cm soft tissue cystic mass in right paratracheal region displacing trachea and causing luminal narrowing (figure1). Patient was started on antibiotics for infected cystic lesion. However patient's condition did not improve, he had abrupt deterioration and developed stridor for which emergency excision of neck cyst, cyst abscess drainage and tracheostomy was done. Histopathologic examination of excised specimen suggested the possibility of lymphoma and hence the patient was referred to our hospital.

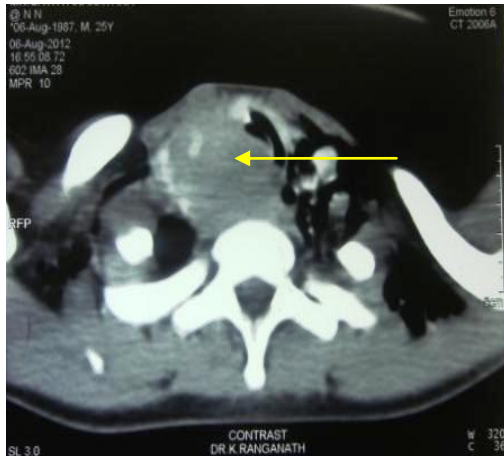


Figure 1: CECT neck showing 4.2×4.1cm soft tissue mass in Right paratracheal region displacing trachea and causing luminal narrowing (arrow).

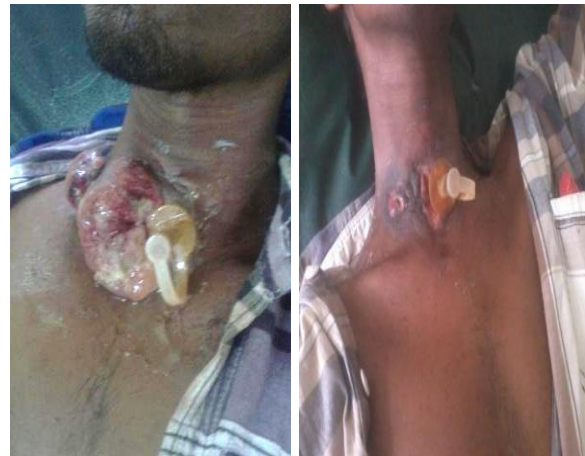

Fig2: Showing neck wound at the site of cyst excision with tracheostomy tube in situ (before chemotherapy and after 4 cycles of CHOP).

On clinical examination at our centre the patient had performance score of 3(ECOG scale). He had a wound on the anterolateral aspect of neck with the tracheostomy tube in situ (figure2a). General physical examination did not reveal any lymphadenopathy.

Nasal and oral cavity examinations were within normal limits. Systemic

evaluation including abdomen and testicular examination were within normal limits.

Histopathology revealed cyst wall suggestive of branchial cleft cyst, lined by a single layer of stratified squamous epithelium with poorly differentiated malignant neoplasm with focal infiltration of overlying epithelium (figure 3a). Scattered embryo like cells was seen (figure 3b). On

immunohistochemistry the neoplastic cells were positive for leucocyte common antigen (LCA), epithelial membrane antigen (EMA), CD30 and ALK (figure4); negative for cytokeratin(CK) , S100 and CD15. A diagnosis of ALK-positive ALCL arising in a branchial cyst was made. Bone marrow

examination showed no marrow involvement. CT thorax, abdomen and pelvis were within normal limits. The patient was started on CHOP chemotherapy. He has finished 4 cycles of chemotherapy and is on regular follow up. (figure2b).

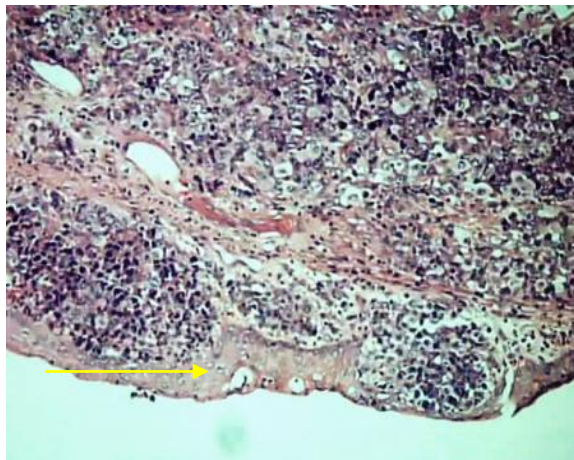


Fig.3a(Haematoxylin and Eosin): showing cyst wall lined by stratified squamous epithelium(arrow) with a malignant neoplasm causing focal infiltration of overlying epithelium (H&E100).

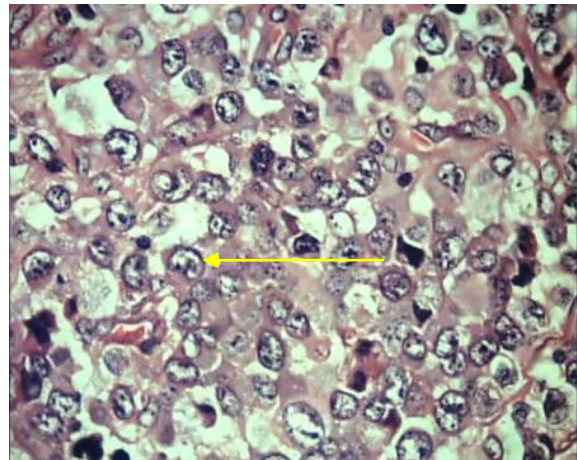


Fig.3b(H&E100): Scattered embryo like cells(arrow) characteristic of ALCL

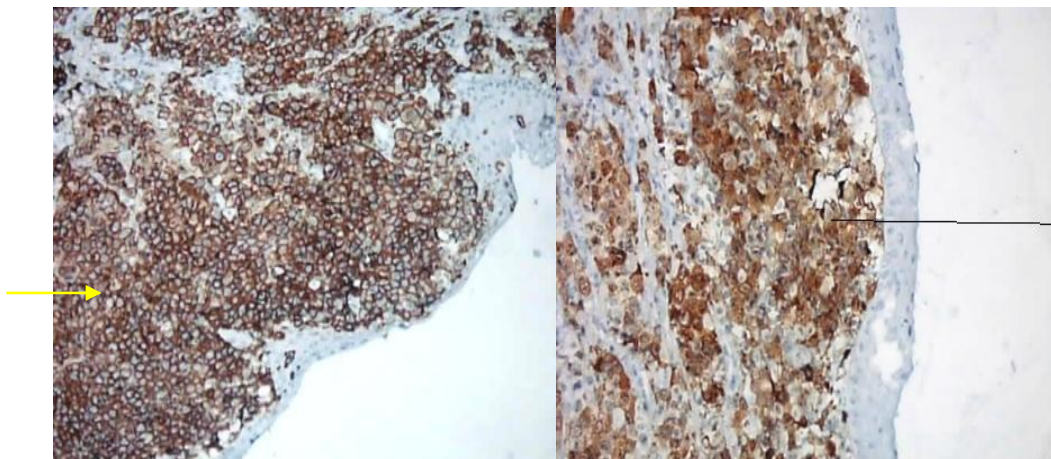


Fig 4: Neoplastic cells showing membranous positivity for CD 30 & ALK. (Immunoperoxidase technique, HPR polymerase method $\times 100$)

DISCUSSION

To the best of our knowledge this is the first reported case of ALCL arising in a branchial cyst. The branchial cyst wall is composed of either squamous or columnar cells with lymphoid infiltrate, often with prominent germinal centers. The theory for origin of branchial cyst is controversial, with

some proposing the developmental theory.^[5] and others supporting the theory that these lesions are derived from epithelial inclusions in lymph nodes.^[6] Although very rare, malignancy can arise in a branchial cyst. The theory of branchial cyst arising from epithelial inclusion in lymph node may explain the origin of ALCL in our patient.

ALCL, ALK+ is a clinically aggressive lymphoma that most commonly occurs in the first 3 decades of life with a typical male predominance. They usually present as an advanced-stage disease with frequent B symptoms and extranodal involvement. Skin (21 to 35%), soft tissue (17%), and bone (8 to 17%) are common extranodal sites, whereas the gastrointestinal tract and central nervous system are rarely involved. [7] Morphologically ALCL is characterized by lymphoid cells which are large with a bizarre horse shoe shaped or embryo-like nuclei and abundant cytoplasm. The tumor cells grow in a cohesive pattern and often preferentially involve the lymph node sinuses or paracortex. The tumour cells are CD 30 positive and usually express CD 25 and epithelial membrane antigen. They are typically CD45+ and CD15 negative. Approximately 60% express one or more T-cell associated antigens: CD2 and CD4 are most consistently expressed. The ALK positive type responds extremely well to CHOP, rendering over a 70 percent long-term disease-free survival, whereas the ALK negative type has a poorer prognosis with less than 45 to 50 percent long-term disease-free survival. [3] Relapse protocols for non-Hodgkins lymphoma followed by a stem cell transplant or newer drugs like brentuximab vedotin and crizotinib. [8] May be prescribed for patients with relapsed or refractory systemic anaplastic large cell lymphoma (ALCL).

CONCLUSION

Although ALCL represents only a small percentage of non-Hodgkins lymphomas, it is very important to recognize them especially when they present with extra nodal disease because it is a highly treatable type of lymphoma with an excellent overall survival rate.

Conflict of interest: The authors declare that they have no conflict of interest.

REFERENCES

1. Delank KW, Freytag G, Stoll W. Clinical relevance of malignant lateral branchial cyst. *Laryngorhinootologie* 1992; 71(12):611-7.
2. Armitage JO, Weisenburger DD. New Approach to Classifying Non-Hodgkin's Lymphomas: Clinical Features of the Major Histologic Subtypes, Non-Hodgkin's Lymphoma Classification Project. *J Clin Oncol* 1998; 16: 2780-95
3. Vose JM, Neumann M, Harris ME. International Peripheral T-Cell and Natural Killer/T-Cell Lymphoma Study: Pathology Findings and Clinical Outcomes, International T-Cell Lymphoma Project. *J Clin Oncol* 2008; 26:4124-4130
4. Savage KJ, Harris NL, Vose JM, Ullrich F, Jaffe ES, Connors JM, et al. ALK- anaplastic large-cell lymphoma is clinically and immunophenotypically different from both ALK+ ALCL and peripheral T-cell lymphoma, not otherwise specified: report from the International Peripheral T-Cell Lymphoma Project. *Blood* 2008; 111(12):5496-504.
5. Regauer S, Gogg-Kamerer M, Braun H, Beham A. Lateral neck cysts--the branchial theory revisited. A critical review and clinicopathological study of 97 cases with special emphasis on cytokeratin expression. *APMIS*. 1997 Aug; 105(8):623-30.
6. Crocker J, Jenkins R. An immunohistochemical study of branchial cysts. *J Clin Pathol* 1985;38:784-790
7. Stein H, Foss HD, Durkop H, Marafioti T, Delsol G, Pulford K, et

al. CD30(+) anaplastic large cell lymphoma: a review of its histopathologic, genetic, and clinical features. Blood 2000;96:3681–3695

8. Foyil KV, Bartlett NL. Brentuximab vedotin and crizotinib in anaplastic large-cell lymphoma. Cancer J. 2012; 18(5):450-6.

How to cite this article: Sirsath NT, Lakshmaiah KC, Premalatha CS et. al. Unusual presentation of anaplastic large cell lymphoma arising in branchial cyst. Int J Health Sci Res. 2013;3(5):111-115.
