



Case Report

## Primary Carcinoid Tumour of Testis - A Rare Case Report

Kishor H. Suryawanshi<sup>1\*</sup>, Rajshri P. Damle<sup>1</sup>, N.V. Dravid<sup>2</sup>, Dhiraj B. Nikumbh<sup>3</sup>, Yogesh R. Tayade<sup>4</sup>

<sup>1</sup>Assistant Professor, <sup>2</sup>Professor & Head, <sup>3</sup>Associate Professor, <sup>4</sup>Assistant Lecturer  
A.C.P.M.Medical College, Dhule.Maharashtra

\*Correspondence Email: ompathologylab@gmail.com

Received: 25/02/2013

Revised: 29/03/2013

Accepted: 02/04/2013

### ABSTRACT

Carcinoid tumour of the testis is very rare (0.23 %). Most carcinoid tumours occur commonly in the appendix or ileocaecal region (85%), while less common (15%) sites are lung, liver, and genitourinary tract. Carcinoid tumours that occur outside the gastrointestinal tract are usually metastatic. Pure primary testicular carcinoid tumour has good prognosis and treated as a benign lesion, while metastatic carcinoid tumour has a poor prognosis whatever may be site of primary tumour. We report a case of primary carcinoid tumour of the testis and review the literature. Detailed work-up of patient by USG, chest x-ray, GI contrast study and CT scan of the abdomen did not reveal any tumour at other sites and 24 hour urinary 5-HIAA estimation was normal.

**Keywords:** primary carcinoid, 5-HIAA, testis tumour

### INTRODUCTION

Carcinoid tumours (85%) occur commonly in the appendix or ileocaecal region and may present in extra intestinal sites i.e. lung, liver, respiratory tract, uterus, ovary and breast or kidney. Carcinoid tumour found outside the gastrointestinal tract are usually metastatic.<sup>(1,2)</sup> Testicular carcinoid tumours are very rare and account for less than 1% of all testicular tumours.<sup>(3)</sup> Testicular carcinoid tumour may occur as primary tumour, as a part of teratoma or as a carcinoid tumour metastatic to the testis.<sup>(2)</sup> In 1930, Cope described the first case of metastatic testicular carcinoid tumour from the small bowel and in 1954 Simon et al

reported the first case of primary testicular carcinoid tumour.<sup>(4,5)</sup> Age group of patients reported in the literature ranged from 10 to 83 years.<sup>(6)</sup> Commonest presentation of carcinoid tumour is usually painless testicular mass, or testicular pain or uncommonly with features of carcinoid syndrome.<sup>(7)</sup> We report a case of primary carcinoid tumour of the testis without features of carcinoid syndrome.

### CASE REPORT

A 55 years old male presented with gradually increasing painless right testicular swelling since 9 months. Detailed clinical history revealed no history of trauma,

urinary tract or sexually transmitted infection. On physical examination firm mass was noted in right testis suggestive of testicular tumour. Other testis was normal in appearance. Symptoms related to carcinoid syndrome were absent. An ultrasound examination of scrotum revealed enlarged right testis with 4x4 cm heterogeneous area suggestive of tumour mass. Detail work-up of patient by USG, chest x-ray, GI contrast study and CT scan of the abdomen did not reveal any tumour and 24 hour urinary 5-HIAA estimation, beta human chorionic gonadotropin and alpha fetoprotein were normal. With clinical diagnosis of testicular tumour, right orchiectomy was performed. Grossly, testis was replaced by well circumscribed tumour mass measuring 4.5x4 cms surrounded by thin rim of normal testis. Cut surface was homogenous yellow-tan in colour. The spermatic cord and epididymis were grossly uninvolved by tumour.

Histologically, the tumour was well separated from the surrounding testicular parenchyma. The tumour cells were arranged in solid nests, tubules and trabeculae separated by delicate fibrovascular stroma. The tumour cells were round or polygonal and had eosinophilic granular cytoplasm. The nuclei were round with evenly dispersed granular chromatin. Focal nuclear pleomorphism was noted. Occasional mitoses were encountered. The residual testicular parenchyma around the tumour was compressed. Tunica albuginea showed mild thickening. Based on these morphological features diagnosis of carcinoid tumour of testis was done. Immunohistochemical study showed tumour cells positive for chromogranin, synaptophysin and neuron specific enolase. The patient was followed up clinically and urinary 5-HIAA estimations were found normal for last one year.

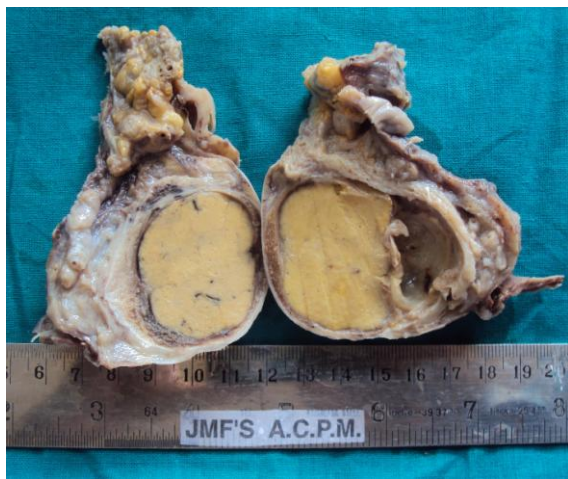


Fig.1: Gross appearance of the cut open right orchiectomy specimen showing homogenous yellow-tan well circumscribed tumour mass surrounded by compressed normal testis.

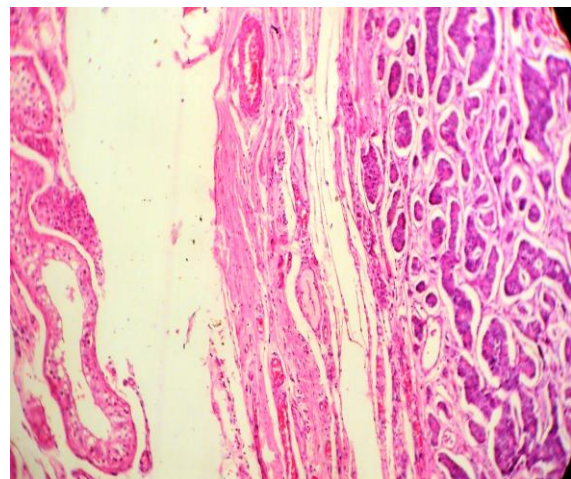


Fig.2: Photomicrograph showing normal testis and well separated tumor showing tumor cells arranged in nests, tubules and trabeculae separated by delicate fibrovascular stroma. (H&E, x100)

## DISCUSSION

Carcinoids are the most common tumours of the appendix and small intestine. Up to 15 % of all carcinoids are found in lung, liver and genitourinary tract. Involvement of testis by carcinoid tumour is

exceedingly rare, and may appear clinically as a primary or metastatic lesion. Most patients present in the fifth to seventh decades. Age group of patients reported in the literature ranged from 10 to 83 years. The left testis was more frequently affected

than the right one, while in one case the tumour was bilateral. (7, 8) In our case right testis is affected by carcinoid tumour. The incidence of carcinoid tumour in the testis is about 0.23% of all testicular neoplasms. (9) The commonest clinical presentation of

testicular carcinoid is painless mass and prominent testicular enlargement. Other symptoms include a painful testis, hydrocele, undescended testis, and carcinoid syndrome. (10)

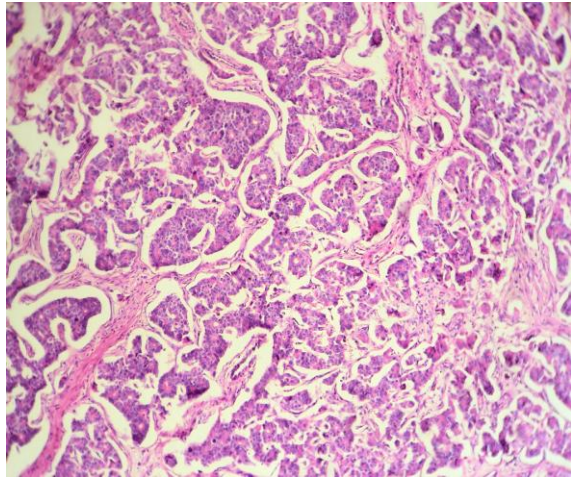


Fig.3: Photomicrograph of the testicular tumor showing tumor cells with round nuclei with evenly dispersed granular chromatin and eosinophilic granular cytoplasm. (H& E, x 400).

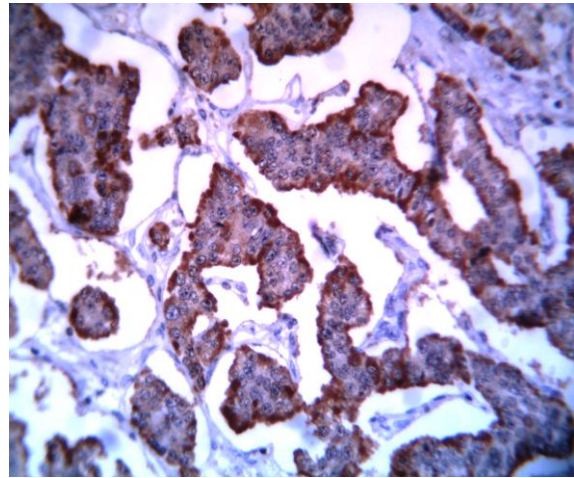


Fig.4: Immunohistochemistry for chromogranin showing diffuse cytoplasmic positivity.

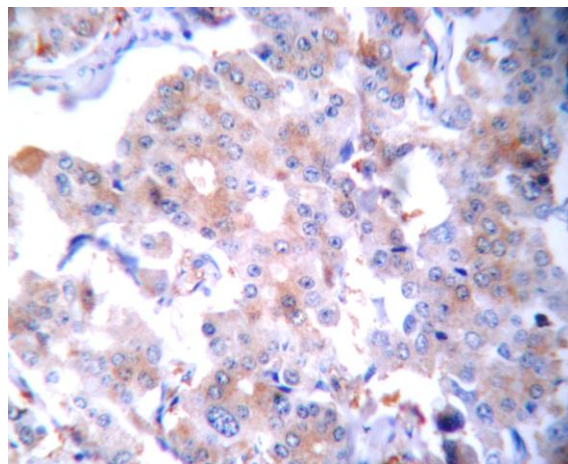


Fig.5: Tumour cells show diffuse positive staining for NSE (Neuron specific enolase).

In a review of 62 published cases of primary testicular carcinoid tumour, the majority (79%) of patients presented with painless testicular lump indistinguishable from other tumours. (6) Carcinoid syndrome (diarrhoea, flushing, and bronchospasm) is quite rare; only 16 % cases have been reported in the literatur. (7) Lack of carcinoid syndrome in

most of the testicular carcinoid tumour is thought to be due to the fact that the peptides secreted by the tumour are either in an inactive form or that they are secreted in insufficient amount to cause the clinical syndrome, or they are rapidly metabolized, which results in the atypical clinical presentation. (10) Testicular carcinoid



tumours have been described into three categories: 1) *primary testicular carcinoid*; 2) *carcinoid metastasis to the testis*; and 3) *carcinoid arising in testicular teratoma*.<sup>(11)</sup> Primary and metastatic carcinoid tumours have similar histomorphology so exclusion of primary tumour in another location is necessary before confirming the diagnosis of a primary testicular carcinoid tumour.<sup>(12)</sup> The histogenesis of primary testicular carcinoid is unclear. The possible origins are the differentiation of totipotential germ cells to argentaffin like cells or the development of a monodermal teratoma without other teratomatous elements.<sup>(11)</sup> Radical orchiectomy is the treatment of choice for testicular confined carcinoid as performed in this case.<sup>(2)</sup> Grossly, the tumour presents as a solid mass, yellowish in colour and a cyst or calcification is sometimes noted. Light microscopy of the tumour reveals an eosinophilic granular cytoplasm, and a round to oval uniform nucleus. Immunohistochemical study shows that tumour cells are reactive to antibodies to chromogranin-A, synaptophysin and NSE. Clinically, pure primary testicular carcinoid tumours have been treated as a benign lesion, while metastatic carcinoid tumours have a poor prognosis regardless of the primary site.<sup>(11)</sup> Long term prognosis of carcinoid is dependent on size, association with teratoma and presence of metastases. Zavala-Pompa et al showed that larger tumours (7.3 vs 2.9 cm) and presence of carcinoid syndrome predicted increased metastatic potential and hence poorer prognosis.<sup>(7)</sup> Testicular carcinoids rarely metastasize. However, some of the tumours develop metastases five to nineteen years after the orchiectomy with the overall incidence estimated at 11%.<sup>(9,13)</sup> Fifty percent of carcinoid tumours with metastasis had carcinoid syndrome, compared with only 3 of 51 cases of carcinoids without metastasis.<sup>(7,13)</sup> Almost 10% of testicular

carcinoids are metastases from another location.<sup>(6)</sup> To rule out the possibility of a metastasis from an extra-testicular primary carcinoid, careful and thorough postoperative whole body surveys are important. Chest X-ray, chest CT (or MRI), abdominal and pelvic CT (or MRI), octreotide scintigraphy, or a small bowel follow-through should be carried out to detect gastrointestinal tract or extra-intestinal primary or carcinoid metastasis.<sup>(14)</sup> A review of the literature suggests that metastatic potential exists for such tumours and regular follow up is indicated. Sutherland et al suggested to check urine 5-hydroxyindolacetic acid (5-HIAA), review the history and perform a physical examination every 3 months for 1 year and then yearly thereafter.<sup>(13)</sup>

## CONCLUSION

Carcinoid tumours are a rare cause of testicular swelling. It is essential to rule out extra testicular primary or metastases once the diagnosis of testicular carcinoid has been made. Long term biochemical and radiological investigations are useful in follow up and in excluding disease recurrence.

## REFERENCES

1. Shurtleff BT, Shvarts O, Rajfer J. Carcinoid tumour of the kidney: Case report and review of literature. *Rev Urol* 2005; 7(4):229-233.
2. Grunshaw ND, Gopichandran TD. Case report: primary carcinoid tumour of the testis- ultrasound appearances. *Clin Radiol* 1993; 47:290-1.
3. Reyes A, Moran CA, Suster S, Michal M, Dominquez H. Neuroendocrine carcinomas (carcinoid tumour) of the testis –A clinicopathological and immune-

- histochemical study of ten cases. *Am J Clin Pathol* 2003;120(2):182-7.
4. Cope Z. Metastasis of an argentaffin carcinoma in the testicle. *Br J Urol* 1930;2:268-72.
  5. Simon HB, McDonald JR, Culp DS. Argentaffin tumour (carcinoid) occurring in a benign cystic teratoma of the testicle. *J Urol* 1954;72:892-4.
  6. Stroosma OB, Delaere KPJ. Carcinoid tumours of the testis. *Br J Urol* 2008;101(9):1101-5.
  7. Zavala-Pompa A, Ro JY, El-Naggar A, Ordonez NG, Amin MB, Pierce PD, Ayala AG. Primary carcinoid tumour of testis. Immunohistochemical, ultrastructural, and DNA flow cytometric study of three cases with a review of the literature. *Cancer* 1993;72:1726-32.
  8. Saxena A, Watkin SW. Bilateral malignant testicular carcinoid. *Br J Urol* 1990;65:302-303.
  9. Berdjis CC, Mostofi FK. Carcinoid tumour of the testis. *J Urol* 1977;118:777-82.
  10. Ordonez NG, Ayala AG, Sneige N, Mackay B. Immunohistochemical demonstration of multiple neurohormonal polypeptides in a case of pure testicular carcinoid. *Am J Clin Pathol* 1982;78:860-4.
  11. Terhune DW, Manson AL, Jordon GH, Peterson N, Auman JR, MacDonald GR. Pure primary testicular carcinoid: a case report and discussion. *J Urol*. 1988;139:132-3.
  12. Pompa AZ, Ordonez NG, Ayala AG. Primary carcinoid tumour of testis. *Cancer* 1993;72:1726-32.
  13. Sutherland RS, Wettlaufer JN, Miller GJ. Primary carcinoid tumour of the testicle: a case report and management schema. *J Urol*. 1992;148:880-2.
  14. Glazier DB, Murphy DP, Barnard MN, Cummings KB, Wiess RE. Primary carcinoid tumour of testis. *BJU International* 1999;83:153-4.

How to cite this article: Suryawanshi KH, Damle RP, Dravid NV et. al. Primary carcinoid tumour of testis - a rare case report. *Int J Health Sci Res*. 2013;3(4):131-135.

\*\*\*\*\*