

*Case Report***A Rare Case of Follicular Dendritic Cell Sarcoma of Cervical Lymph Node**Mahesh Kalloli^{1*}, Sudhir M Naik^{2**}, Ashish Dinesh Shah^{3***}, Purushotham Chavan^{3****}, Ashok Shenoy^{2*****}

*Senior Resident, **Fellow, ***Junior Resident, ****Asst. Professor, *****Professor

¹Dept of Surgical Oncology, KMIO, Bangalore²Dept of Head and Neck Oncology, KMIO, Bangalore³Dept of Pathology, KMIO, Bangalore

*Correspondence Email: mahesh.kalloli@gmail.com

*Received: 04/02/2013**Revised: 22/03/2013**Accepted: 27/03/2013***ABSTRACT**

Follicular dendritic cell sarcoma is a rare tumour that usually presents as a single mass in the head and neck, although it is not a lymphatic tumour, it tends to involve cervical lymph nodes and behave as other sarcomas. Diagnosis should be done by suspicion and confirmed by immunohistochemistry. Surgical resection with adjuvant therapy is recommended with regular follow up in search relapses. We report this rare entity occurring in a 26 year male patient who was managed with wide excision followed by post operative radiotherapy.

Key-words: Follicular dendritic cell sarcoma, Immunohistochemistry, Wide excision, Adjuvant therapy

Key Messages

Follicular dendritic cell sarcoma is a rare tumor. Diagnosis should be done by suspicion and confirmed by immunohistochemistry. Surgical resection with adjuvant therapy is recommended with regular follow up in search relapses.

INTRODUCTION

Follicular dendritic cell sarcoma (FDCS) is an uncommon rare tumor arising from the antigen-presenting cells of the B-cell follicles of the lymph nodes. [1] Two thirds of this type of sarcoma appear in cervical lymph nodes but there appearance in the mediastinum, axilla, mesentery and retro peritoneum are also reported. [2] The most common extra nodal sites include the palatine tonsils, mouth, pharynx and intra-abdominal organs such as the liver and spleen. [1-2] A primary neoplasm arising

from the follicular dendritic cell was reported in 1986 by Monda et al and more than 150 cases have been reported in literature worldwide, very few in India. [3-4]

Diagnosis often requires availability of specific antibodies to confirm follicular dendritic cell (FDC) lineage. [1] These cells are positive for CD21, CD35, CD1 and S100. [5] Histologically FDCS are composed of spindle to ovoid cells that are arranged in fascicles, storiform patterns and whorls. [5] Definitive diagnosis always requires

confirmation by immunohistochemistry or ultra structural studies. [2]

We report a rare case of FDCS of the right cervical lymph node successfully diagnosed and treated with surgery and adjuvant therapy.

CASE REPORT

A 26 year male patient presented to our outpatient with an asymptomatic swelling in the right side of the neck since 15 months. The globular swelling was about 8x6 cm in size slowly enlarged over the period of 15 months. The swelling was firm with the skin over the swelling intact.

Oral, oropharyngeal, indirect laryngoscopic, postnasal and anterior rhinoscopic examinations were all within normal limits. Nasal endoscopic, 90° Hopkin laryngoscopic examination did not reveal any pathology. All baseline blood and urine examination were within normal limits. Esophago-gastro-duodenoscopy, x-ray of the

chest and soft tissue neck were normal. Fine-needle aspiration cytology suspected paraganglioma. Contrast enhanced computerised tomography of the neck revealed an apparent 8×6 cm mass of solid and heterogenous opacity on the right side of the neck and compressing the large ipsilateral neck vessels.

Patient underwent a planned neck exploration and excision under general anaesthesia. Histopathological examination showed effacement of the nodal architecture by a neoplastic lesion exhibiting sheets of large tumour cells with moderate amount of cytoplasm and spindle appearance. The nuclei showed moderate to severe pleomorphism and hyperchromasia (Figure 1). Occasional prominent nucleoli were seen. Abundant mitotic figures were present around 12-14/10 HPF (Figure 2). No glycogen positivity was seen on special stains.

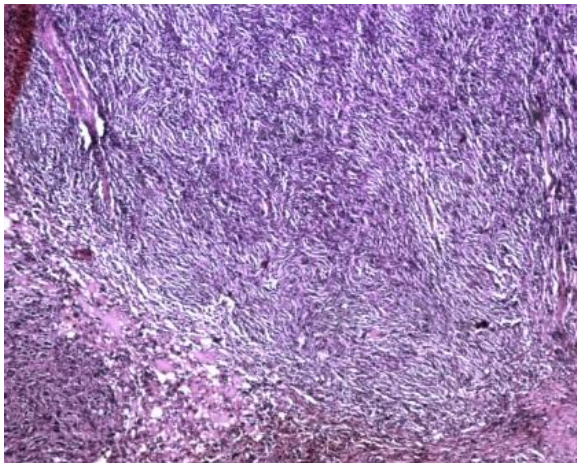


Figure 1: H & E Sections showing effaced nodal architecture by large tumour cells with moderate cytoplasm and pleomorphic nuclei. (Mag 20x)

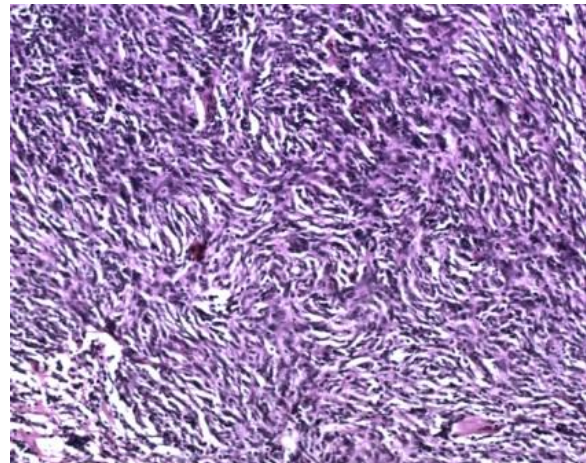


Figure 2: Follicular dendritic cell sarcoma (electron microscopy). Numerous long cytoplasmic processes are seen to intermingle often joined by desmosomes.

Initial panel of immunohistochemistry was negative for epithelial markers (cytokeratin, EMA) and lymphoid panel (LCA, Pan B markers and CD 20) and S-100, CD31, CD34, HMB45, Vimentin, ASMA and Desmin. CD21 and CD23 markers characteristic of FDC were detected (Figure 3).

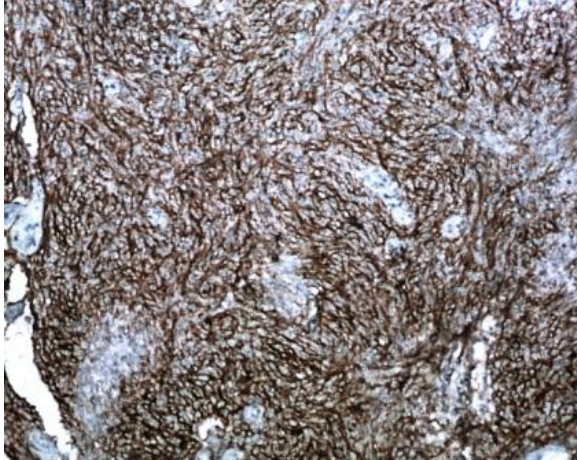


Figure 3: Follicular dendritic cell sarcoma (immunohistochemistry, 200×). Intense, diffuse membrane CD21 antibody positivity.

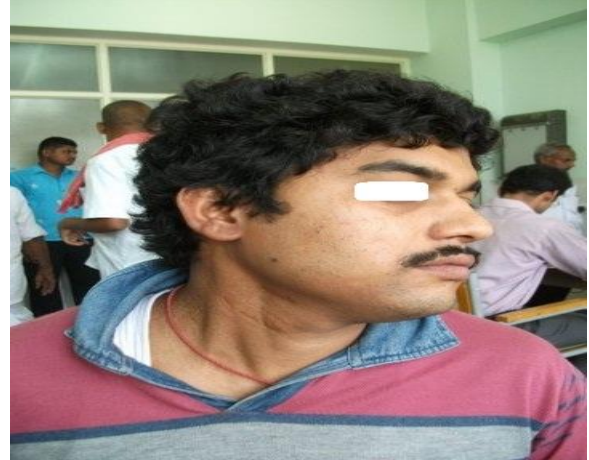

Figure 4: The patient at 36 months of follow up without any relapse.

The case was diagnosed as FDSC according to WHO/REAL classification system. Patient was treated with adjuvant treatment with external beam radiotherapy of 60 Gy in 30 fractions. 36 months following surgery and 33 months after completing radiotherapy, the patient has not shown any clinical signs of relapse (Figure 4).

DISCUSSION

Sarcomas are uncommon tumours of mesenchymal origin, accounting for less than 1% of all head and neck tumours. [6] In 1978, Lennert was the first to predict the possible existence of FDC tumours which was confirmed a decade later by Monda et al. [3] These neoplasms arise from antigen presenting cells of the mononuclear phagocytic system which are the reticular, dendritic looking cells in charge of generating and regulating the immune response in germinal centres, although without phagocytic activity. [7]

It is difficult to analyze the clinical and evolutionary characteristics of FDSC given that it is such an uncommon diagnosis. [7] FDC is also called as dendritic reticulum cells which are essential for antigen presentation and germinal center reaction regulation. [8] They are found in lymphoid

follicles, at nodal or extranodal sites, and present antigen to B lymphocytes and form meshwork within lymphoid follicles via cell to cell attachments. [9] They trap and store antigen-antibody complexes and provide important stimuli to B cells, such that B-cell activation in the follicle cannot take place in their absence. [9]

These sarcomas occur both in nodal and extranodal site. The initial cases of extranodal presentation were confused as reactive response, inflammatory pseudotumor, malignant fibrous histiocytoma, meningioma, mesenchymal tumor with neural differentiation, schwannoma, stromal tumor, thymoma, gastrointestinal stromal tumor, and interdigitating reticulum cell sarcoma and carcinoma. [9]

Diagnostic suspicion is based on the clinical history, imaging studies and fine needle aspiration cytology of the swelling; If it is not conclusive, a broader biopsy or complete resection of the tumour should be performed and subsequently studied. [10] They are highly undifferentiated, with nodular or moruliform areas and high rate of mitosis. [10]

The abundance of small, mature lymphocytes surrounding the vessels is

characteristic but immunohistochemistry is confirmatory. [10-11] Markers such as CD21, CD35 and CD23 are considered to be a distinctive feature of this tumour. [10-11] Negativity for cytokeratins, CD20, CD1a and skeletal muscle and vascular markers establish the differential diagnosis with various poorly differentiated carcinomas, thymic and Castle type tumours, with which they may be confused on the histopathology. [12] Variability for S-100 should also be taken into account in making a differential diagnosis with some melanomas. [13]

CD21 and CD35 antibodies are negative in meningioma, thymoma, malignant fibrous histiocytoma, and interdigitating dendritic cell sarcoma. [2, 14] Positive clusterin staining distinguish FDSC from other dendritic cell neoplasms. [15] These tumours are considered to have a low or intermediate degree of malignancy due to its variable behaviour. [16] Recent reports and long term follow up has concluded that FDSC is an intermediate-grade malignancy which is more aggressive than reported earlier. [1] Additional data show overall recurrence, metastatic, and mortality rates of 43%, 24%, and 17%, respectively, prompting consideration of this malignancy to be of at least intermediate grade. [17] Distant metastasis generally appears in the lung and liver with 15% mortality. [2, 18]

The treatment of choice is complete surgical excision. Role of radiotherapy and chemotherapy is not well reported. [2, 18] Use of adjuvant COP plus PEG liposomal doxorubicin after wide excision with a documented very good response at 5 years of follow-up is reported. [1] Chan et al. reported a recurrence rate of 40% and a metastasis rate of 25% with a mortality rate of 16.7%. [17] So they advocated adjuvant radiotherapy or chemotherapy after adequate wide resection. [19-20] A 5-year recurrence-free survival rate was 27.4% were reported after analyzing 25 cases of extra nodal

FDSC. [21] Intra-abdominal location of the tumor, size more than 6 cm, mitotic count more than 5 per 10 high-power fields, coagulative necrosis, significant nuclear pleomorphism, and lack of adjuvant therapy all denote worse prognosis as recurrence. [17, 21]

Analysis of associations between possible prognostic factors and recurrence-free survival showed no statistical significance for age, sex, intra-abdominal involvement, size, lymph node involvement or distant metastasis at time of presentation, mitotic rate, necrosis, or the use of neoadjuvant or adjuvant therapy. [17, 21] Limited experience has deterred from defining optimal treatment for FDSC so the current approach is to apply therapeutic guidelines similar to those used for soft tissue sarcomas of high grade. [9]

We opted for postoperative radiation in the light of the size and high degree of nuclear pleomorphism, the presence of peritumour necrosis and neovascularisation despite the fact that the surgical margins were free of tumour infiltration.

CONCLUSION

In conclusion, FDSC is a very rare tumour that usually presents as a single mass in the head and neck; although it is not a lymphatic tumour, it tends to involve cervical lymph nodes and behave as other sarcomas. Diagnosis should be done by suspicion and confirmed by immunohistochemistry. Radical surgical resection with adjuvant therapy is recommended with regular follow up in search of local or distant relapses. A more thorough analysis of the clinical behaviour and standardizing the treatment protocol is the need of the hour.

REFERENCES

1. F Pisani, M Marino, S Sentinelli, et al. Follicular dendritic cell sarcoma

- of the neck: Report of a case treated by surgical excision and COP plus (PEG)-liposomal doxorubicin: *Journal of Experimental & Clinical Cancer Research* 2008, 27:33.
2. Chan JK, Fletcher CD, Nayler SJ, et al. Follicular dendritic cell sarcoma clinicopathologic analysis of 17 cases suggesting a malignant potential higher than currently recognized. *Cancer* 1997; 79: 294-313.
 3. Monda L, Warnke R, Rosai J. A primary lymph node malignancy with features suggestive of dendritic reticulum cell differentiation, a report of 4 cases. *Am J Pathol* 1986; 122: 562- 72.
 4. Malik A, Veniyoor A, Fanthome B, et al. Follicular dendritic cell sarcoma: A diagnostic challenge! *J Can Res Ther* [serial online] 2012 [cited 2012 Aug 3]; 8:306-7.
 5. Khalid S, Yaqoob N, Pervez S. Follicular dendritic cell sarcoma of lymph node – a rare entity. *J Pak Med Assoc* 2006, 56:137-139.
 6. Mendenhall WM, Mendenhall CM, Werning JW, et al. Adult head and neck soft tissue sarcomas [revision]. *Head Neck*. 2005; 27:916-22.
 7. Foucar K, Foucar E. The mononuclear phagocyte and immunoregulatory effector (MPIRE) system: evolving concepts. *Semin Diagn Pathol*. 1990; 7:4-18.
 8. Tu XY, Sheng WQ, Lu HF, et al. Clinicopathologic study of intraabdominal extranodal follicular dendritic cell sarcoma. *Chin J Pathol* 2007, 36(10):660-665.
 9. K E Youens, M S Waugh. Extranodal follicular dendritic cell sarcoma: *Arch Pathol Lab Med*, Vol 132, October 2008.
 10. Zhong GP, Sun WY, Gan MF, et al. Follicular dendritic cell sarcoma: a clinic pathological study of five cases. *Chin J Pathol* 2006, 35(10):612-615.
 11. Biddle DA, Ro JY, Yoon GS, et al. Extranodal follicular dendritic cell sarcoma of the head and neck region: three new cases, with a review of the literature. *Mod Pathol* 2002, 15:50-8.
 12. Ruco LP, Gearing AJ, Pigott R, et al. Expression of ICAM-1, VCAM-1 and ELAM-1 in angiofollicular lymph node hyperplasia (Castleman's disease): evidence for dysplasia of follicular dendritic reticulum cells. *Histopathology*. 1991; 19:523–528.
 13. Moz U, Pignatelli U, Forner P, et al. [Follicular dendritic cell tumour of the cervical lymph node: case report and brief review of literature]. *Acta Otorhinolaryngol Ital*. 2004;24:223-5.
 14. Weiss LM, Grogan TM, Muller-Hermelink H-K, et al. Follicular dendritic cell sarcoma/tumour. In: Jaffe ES, Harris NL, Stein H, Vardiman JW, eds. *Tumours of Haemotopoietic and Lymphoid Tissues*. Lyon, France: IARC Press; 2001:286– 288. World Health Organization Classification of Tumours.
 15. Grogg KL, Lae ME, Kurtin PJ, et al. Clusterin expression distinguishes follicular dendritic cell tumors from other dendritic cell neoplasms: report of a novel follicular dendritic cell marker and clinicopathologic data on 12 additional follicular dendritic cell tumors and 6 additional interdigitating dendritic cell tumors. *Am J Surg Pathol*. 2004;28: 988–998.

16. Vargas H, Mouzakes J, Purdy SS, et al. Follicular dendritic cell tumor: an aggressive head and neck tumor. *Am J Otolaryngol.* 2002; 23: 93-8.
17. Chan JK, Fletcher CD, Nayler SJ, et al. Follicular dendritic cell sarcoma: clinicopathologic analysis of 17 cases suggesting a malignant potential higher than currently recognized. *Cancer.* 1997; 79: 294–313.
18. Perez-Ordóñez B, Rosai J. Follicular dendritic cell tumor: review of the entity. *Semin Diagn Pathol.* 1998; 15:144-54.
19. Fonseca R, Yamakawa M, Nakamura S, et al. Follicular dendritic cell sarcoma and interdigitating reticulum cell sarcoma: a review. *Am J Hematol* 1998, 59:161- 167.
20. Nakashima T, Kuratomi Y, Shiratsuchi H, et al. Follicular dendritic cell sarcoma of the neck; a case report and literature review. *Auris Nasus Larynx* 2002, 29:401-403.
21. Shia J, Chen W, Tang LH, et al. Extra nodal follicular dendritic cell sarcoma: clinical, pathologic, and histogenetic characteristics of an under recognized disease entity. *Virchows Arch.* 2006; 449(2):148–158.

How to cite this article: Kalloli M, Naik SM, Shah AD et. al. A rare case of follicular dendritic cell sarcoma of cervical lymph node. *Int J Health Sci Res.* 2013;3(4):121-126.
