



Case Report

## Hemosuccus Pancreaticus: An Uncommon Presentation

Kanetkar Amol Vijay<sup>1\*</sup>, Monty Khajanchi<sup>2</sup>, Ram Prajapati<sup>3</sup>, Rajiv Satoskar<sup>4</sup>

<sup>1</sup>Resident, <sup>2</sup>Assistant Professor, <sup>3</sup>Associate Professor, <sup>4</sup>Professor  
Department of General Surgery, Seth G S Medical College & KEM Hospital, Mumbai.

\*Correspondence Email: avkanetkar@rediffmail.com

Received: 28/01/2013

Revised: 27/02/2013

Accepted: 07/03/2013

### ABSTRACT

Hemosuccus Pancreaticus (HP) is a rare & potentially life threatening clinical entity. It is described as bleeding from Ampulla of Vater via the Pancreatic Duct (PD). This condition is classically attributed to erosion of Splenic artery Aneurysm into the PD or bleeding into a pseudocyst as a result of Acute or Chronic Pancreatitis causing intermittent severe upper gastrointestinal (GI) bleeding. It poses a significant diagnostic & therapeutic dilemma because of its rarity, anatomic location & intermittency of bleeding. When Obscure GI bleeding is encountered, HP should be considered in cases of pancreatitis. Mesenteric Angiographic intervention remains the modality of choice for diagnosis & treatment. However if embolization of bleeding vessel fails, emergency surgery should be undertaken. We describe our experience with a case of HP who presented to us with hematochezia with hemodynamic instability and the diagnostic as well as therapeutic difficulties faced.

**Key Words:** Hemosuccus Pancreaticus, Chronic Pancreatitis, Obscure GI bleed, Mesenteric Angiography.

### INTRODUCTION

Hemosuccus Pancreaticus (HP) is described as bleeding from the Ampulla of Vater via the pancreatic duct. It is the least frequent cause of upper gastrointestinal bleed (1/1500) & is observed predominantly in males (M: F 7:1).<sup>[1]</sup> This potentially life threatening entity is often difficult to diagnose because of its rarity, anatomic location & intermittency of bleeding and equally difficult to manage.

### CASE REPORT

A 40 year old male patient presented as hematochezia with hemodynamic

instability. After initial stabilization upper gastrointestinal endoscopy (UGI) & colonoscopy were normal, CT angiography suggested chronic calcific pancreatitis. As the patient stabilised with no active bleeding elective mesenteric angiography was planned. During elective waiting period patient had second episode of hematochezia with hemodynamic instability. RBC scan revealed area of bleed from stomach & duodenum. Repeat UGI scopy revealed spurt from duodenal papilla. CT angiography was re-evaluated which suggested a splenic artery pseudoaneurysm. As there was no vascular intervention available during that

hour, emergency surgery was performed, ligating the Splenic artery at its origin. A week after surgery, repeat CT angiography revealed proximal occlusion of Splenic artery with distal filling up (Figure.1). Patient rebled in the same admission & emergency vascular intervention performed

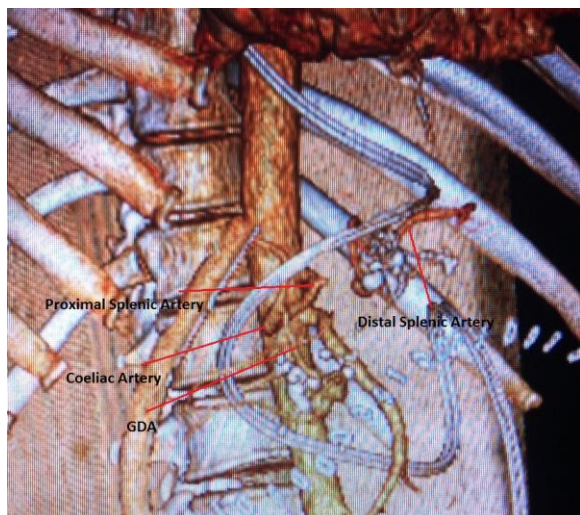


Figure.1: CT Angiography with 3D reconstruction showing filling up of distal splenic artery from pancreatic collaterals.

revealing Gastroduodenal artery pseudoaneurysm & filling up of distal splenic artery from pancreatic collaterals (Figure.2), these were embolised using coils. Patient had uneventful course there after & was followed up for a period of three months without any complaints.

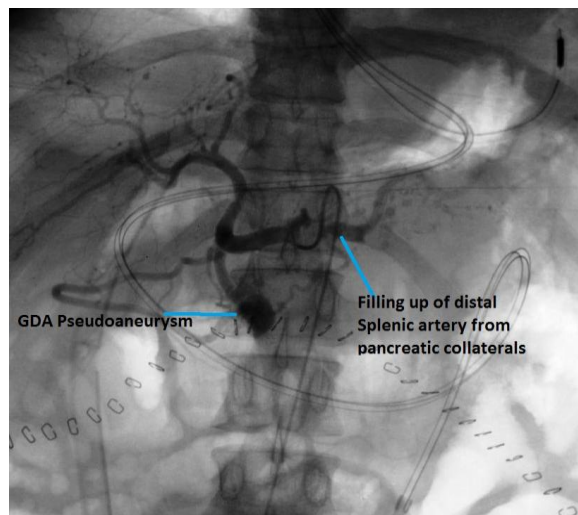


Figure.2: Mesenteric angiography showing GDA Pseudo aneurysm & Filling up of distal splenic artery from pancreatic collaterals.

## DISCUSSION

Lower & Farrel in 1931 first reported bleeding from pancreatic duct (PD) due to rupture of splenic artery. [2] Sandblom in 1970 first coined the term Hemosuccus Pancreaticus (HP).

It occurs most commonly as a result of rupture of pseudoaneurysm of splenic artery into the PD in the setting of chronic pancreatitis though the same can occur with acute pancreatitis also. [3] Other causes include pancreatic trauma, pancreatic neoplasms, pancreatolithiasis, a divisum & in present era following endoscopic interventions of pancreas. [4]

Diagnosis can be best reached after an UGI scopy to rule out other common causes of gastrointestinal bleed followed by selective angiography of mesenteric vessels which has a sensitivity of 96 per cent. [5]

Selective transcatheter embolisation of bleeding artery has a success rate of 80 per cent. [6] Stenting compared to embolisation bleeding vessel is associated with lower rates of ischemic complications. [7]

In the absence of radiological interventions surgery is the only resort which includes either ligation of culprit vessel or resectional surgery i.e. pancreatoduodenectomy or distal pancreatectomy with splenectomy depending upon the location of bleeder. These procedures are associated with high mortality rates of 16 & 43 per cent respectively. [8]

Conclusions:

When GI bleeding from an obscure source is encountered, HP should be considered in cases of pancreatitis. Mesenteric angiographic intervention should

be the modality of choice for diagnosis as well as treatment & should be done without any time lag. However if embolisation or stenting fail or not available, surgery should be undertaken immediately. Ligation of bleeding vessel on both sides of the defect is essential. Authors didn't find the technique of ligation of splenic artery from both sides described in the management of HP in the literature.

## REFERENCES

1. Suter M, Doenz F, Chapuis G et al. 1995. Haemorrhage into the pancreatic duct (Hemosuccus Pancreaticus): Recognition & management. *Eur J Surg.* 161: 887-892.
2. Lower WE, Farrel JI. 1931. Aneurysm of the splenic artery: report of a case and review of literature. *Arch Surg.* 23: 182-190.
3. Forsmark CE; 'Chronic pancreatitis'. In: M Feldman, LS Friedman, MH Sleisenger, eds. *Sleisenger & Fordtran's Gastrointestinal and Liver Disease.* 7th Ed. Philadelphia:Saunders, 2002 p. 943 – 969.
4. Jutabha R, Jensen DM. Uncommon causes of upper gastrointestinal bleeding. *UpToDate.* Wellesley, 2005, vol 13.3. <http://www.uptodate.com>.
5. Mandel SR, Jaques PF, Mauro MA et al. 1987. Nonoperative management of peripancreatic arterial aneurysms. *Ann Surg.* 205(2):126-128.
6. Dasgupta R, Davies NJ, Williamson RCN et al. 2002. Hemosuccus Pancreaticus:treatment by arterial embolization. *Clinical Radiology.* 57: 1021-1027.
7. Benz CA, Jakob P, Jakobs R et al. 2000. Hemosuccus pancreaticus a rare cause of gastrointestinal bleeding: diagnosis and interventional radiological therapy. *Endoscopy.*32:428 – 431.
8. Bender JS, Bouwman DL, Levison MA et al. 1995. Pseudocysts and pseudoaneurysms: surgical strategy. *Pancreas.* 10: 143-147.

How to cite this article: Vijay KA, Khajanchi M, Prajapati R et. al. Hemosuccus Pancreaticus: An Uncommon Presentation. *Int J Health Sci Res.* 2013;3(3):72-74.

\*\*\*\*\*