

*Case Report***An Unusual Presentation of a Non Organic Visual Loss**Hegde Vidya^{1@}, Vaishali NH², Anupama B¹, Jain Rashmi¹¹Department of Ophthalmology²Department of Psychiatry

Yenepoya Medical College, Deralakatte, Mangalore - 575018

@Correspondence Email: vidya_radhesh@rediffmail.com

*Received: 27/12/2012**Revised: 15/01/2013**Accepted: 22/01/2013***ABSTRACT**

We report a case of a young male child who presented with acute onset of monocular diplopia, mild pain with decreased vision in the left eye, and alternating esotropia of variable degree. A normal fundus examination with abnormal Visual Evoked Potential (VEP) in the left eye suggested a possible diagnosis of retro bulbar neuritis for which he received intravenous methylprednisolone. However, over the next 48 hours, the child developed unexplained spasm of near reflex along with nonspecific generalized body ache. Following psychiatry evaluation, a diagnosis of non organic visual loss was made. The child was diagnosed to have conversion disorder and he showed dramatic improvement with resolution of diplopia and attaining orthophoria following psychotherapy. This case of conversion disorder is of interest as the abnormal VEP led to a misdiagnosis of retro bulbar neuritis.

Key words: monocular diplopia, VEP, spasm of near reflex, non organic visual loss

INTRODUCTION

Non organic visual loss is defined as any decrease in visual function in which the degree of subjective visual symptoms cannot be explained by the objective evaluation. [1] Its prevalence in children in a study was found to be approximately 1.75%. [2] Recognizing nonorganic visual loss and managing it appropriately minimizes patient distress, inappropriate referrals, and unnecessary health care and disability expenditures. We report a case of non organic visual loss in a male child who presented with monocular diplopia and spasm of near reflex, and who responded to psychotherapy.

CASE REPORT

A twelve year old boy, a hostel resident, presented with acute onset of monocular diplopia of three days duration in the left eye. He also complained of seeing a pattern in that eye. There was associated mild pain in the left eye and worsening of deviation of eyes. Three months prior to the presentation, he had recent onset of deviation of eyes. He was then diagnosed to have alternating esotropia (60 PD) with hypermetropia of one diopter, for which he was prescribed spectacles. Clinical examination revealed presence of alternating esotropia of variable degree. Ocular movements revealed normal ductions in both the eyes. There was limitation of

movements in left gaze while testing for versions. Best corrected visual acuity (BCVA) was 20/20 in right eye (RE) and 20/60 in left eye (LE). Anterior segment and fundus examinations were unremarkable. Diplopia charting showed presence of triplopia in primary, up and down gazes. Forced duction and force generation tests were negative. Cycloplegic refraction showed one diopter of hypermetropia in both eyes. Routine blood investigations were within normal limits. He received Azithromycin along with combination of paracetamol and chlorpheniramine maleate for rhino sinusitis. Over a period of 48 hours, he had retro-orbital pain and limitation of abduction in LE. BCVA in the RE was 20/40 and LE was 20/200. Magnetic Resonance Imaging (MRI) brain study was normal. Pattern VEP study showed LE delayed latency. (Figure 1) A diagnosis of LE retrobulbar neuritis was made for which he received intravenous methylprednisolone in the dose of 1 gm/ day. He developed severe myalgia after two doses of methylprednisolone, along with spasm of near reflex (Figure 2) and generalized nonspecific body ache. His BCVA in RE was 20/200 and LE was 20/250.

Psychiatry evaluation revealed interpersonal problems at home and about fear of failing in the upcoming exam. (Figure 3) He was diagnosed to have conversion disorder. Cognitive behaviour therapy with emphasis on enhancing coping skills and problem solving was initiated, along with a course of antidepressants. The child showed dramatic improvement with orthophoric gaze (Figure 4), normal ocular movements, BCVA of 20/20 in both the eyes and resolution of diplopia after two days of psychotherapy. He was followed up twice in a month's duration. Psychotherapy was continued each time and the stressors were addressed. He maintained orthophoric

gaze and BCVA of 20/20 in each eye during the follow up visits.




Figure 1 VEP study by pattern reversal method showing delayed latency in LE

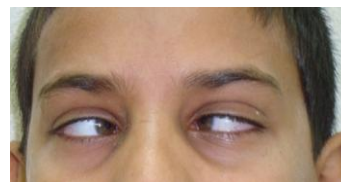

Figure 2 Photograph of patient showing spasm of near reflex



Figure 3 Photograph of drawing done by the boy depicting his problems

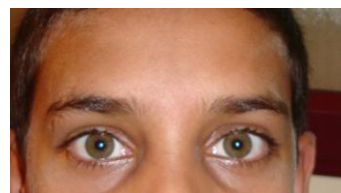

Figure 4 Photograph of patient showing orthophoric gaze

DISCUSSION

Rapidly progressive visual loss in children is an alarming symptom, which requires urgent diagnosis and management. It is important that one needs to be aware of neurological causes such as occipital epilepsy, migraine as well as ophthalmic conditions like early onset macular dystrophies and hereditary optic neuropathies. The main diagnostic dilemma for a clinician facing a child with acute or sub acute visual loss and no objective

ophthalmologic or neurologic signs is exclusion of retro bulbar neuritis.

In children, non organic visual loss is more common in prepubertal age group. Ocular manifestations of non organic visual loss include visual field defects, nystagmus, pupillary disturbances, convergence and accommodation insufficiency, spasm of near reflex, ptosis, blepharospasm and paralysis of horizontal and vertical gaze. [3] Spasm of near reflex is an ocular motility disturbance. The degree of convergence is variable and may be marked involving both eyes resulting in a marked esotropia. [3, 4] Monocular diplopia with two separate and equal images of object or triplopia is also manifestation of non organic visual loss. [4-6]

VEP is one of the techniques used to differentiate non organic from organic vision loss. [7] Suppiej et al have shown that VEP is of value in confirming clinical suspicion of non organic visual loss, particularly when clinical overlap with optic neuritis occurs. [1] Also they demonstrated high sensitivity for the test. However, Thompson has shown that the response of pattern VEP could be consciously repressed by convergence maneuvers, by meditation or by fixing away from the centre of the monitor. [8] Uren et al have shown that consistent changes could be produced in the latency by eccentrically fixing on the target monitor. [9] Careful monitoring of subject cooperation is very crucial while performing the test particularly when recording in children who have limited attention span.

In our case, the child was in prepubertal age group. Rapid visual loss in the left eye with delayed latency in pattern VEP made us suspect retrobulbar neuritis. Later spasm of near reflex with generalized body ache, suggested the possibility of non organic visual loss.

Dissociative / conversion disorders are a group of disorders in which there is disruption in the usually integrated functions

of consciousness, memory, identity or perception. The disturbance may be sudden or gradual, transient or chronic. [10] Precipitating factors include life stressors of all types, involving either the child directly or the whole family. [11] There were interpersonal problems in the family of this child, because of which he was sent to a boarding school. He used to remain absent from school frequently to visit home as he was missing his parents. This led him to fear of failure in his exams. All these acted as precipitating factors for the child's current presentation. The presenting disability may be explained in terms of the body's physical functions, with a person's feelings/emotions and social/interpersonal situation interacting with one another.

CONCLUSION

This case report is an unusual presentation of non organic visual loss in the form of monocular diplopia and spasm of near reflex that was managed effectively by psychotherapy.

Key Message:

Unexplained rapid visual loss in a child requires psychological evaluation. Also VEP finding in a case of unexplained visual loss should be evaluated in the clinical context.

REFERENCES

1. Suppiej A, Gaspa G, Cappellari A et al. The role of Visual Evoked Potentials in the differential Diagnosis of Functional Visual Loss and Optic neuritis in children. *J Child Neurol* 2010; 26 (1): 58-64.
2. Lim SA, Siatkowski RM, Farris BK. Functional Visual Loss in adults and children. Patient Characteristics, Management and outcomes. *Ophthalmology* 2005;112:1821-8.

3. Miller NR, Keane JR. Neuro-ophthalmologic manifestations of nonorganic disease. In : Miller NR, Newman NJ, eds. Walsh and Hoyt's Clinical Neuro-ophthalmology, 5th ed. Baltimore: Williams & Wilkins, 1998; vol.1, 1765 – 86.
4. Bain K E, Betty S, Llyod C. Non organic visual loss in children. *Eye* 2000; 14 (5): 770- 2.
5. Mojon DS, Flueckiger P.A new optotype chart for detection of nonorganic visual loss. *Ophthalmology* 2002; 109:810-15.
6. Campbell AMG, Cross AG. Ocular Neurosis. *Br J Ophthalmol* 1944;28(8): 394-402.
7. Holder GE. Electrodiagnostic testing in malingering and hysteria. In: Heckenlively JR, Arden GB, eds. Principles and Practice of Clinical Electrophysiology of Vision. St. Louis: Mosby Year Book, 1991; 573-7.
8. Thompson HS. Functional visual loss. *Am J Ophthalmol* 1985; 100:209-13.
9. Uren SM, Stewart P, Crosby PA. Subject co operation and the visual evoked response. *Invest Ophthalmol Vis Sci* 1979; 18: 648-52.
10. Benjamin James Sadock, Virginia Alcott Sadock. In: Kaplan and Sadock's synopsis of psychiatry. Behavioral Sciences/ Clinical Psychiatry, 10th ed. Philadelphia: Wolter Kluwer/Lippincott Williams & Wilkins, 2007; 665.
11. M. Rutter, DVM Bishop, D.S.Pine et al. In: Rutter's child and Adolescent psychiatry, 5th ed. Carlton, Victoria: Blackwell Publishing Asia Pty Ltd, 2008; 939.

How to cite this article: Vidya H, Vaishali NH, Anupama B et. al. An unusual presentation of a non organic visual loss. *Int J Health Sci Res.* 2013;3(1):65-68.
