



Case Report

## High Risk Gestational Trophoblastic Neoplasia Following Recurrent Partial Molar Pregnancy: A Case Report and Review of Literature

Shakuntala PN\*, Bafna UD, Anbukani S, Rajshekar K, Umaevi K

Department of Gynaecologic Oncology, Kidwai Memorial Institute of Oncology, Dr.M.H. Mari Gowda Road, Bengaluru-560029, Karnataka, India.

\*Correspondence Email: shakuntala\_pn@yahoo.com

Received: 17/11/2012

Revised: 22/12/2012

Accepted: 04/01/2013

### ABSTRACT

Recurrent partial molar pregnancy is a rare entity and therefore, only a few case reports are available. Five cases of Persistent Gestational Trophoblastic Tumour (PGTT) following partial molar pregnancy were reported by Bagshawe KD et al in 1990 for the first time and since then about 50 cases of PGTT (16 high risk) have been reported in the English medical literature. We present the 17<sup>th</sup> case, a woman who had 4 molar pregnancies, first and second were complete molar pregnancies, third and fourth pregnancies were partial molar pregnancies. The fourth pregnancy progressed to persistent disease not responding to single agent methotrexate. She required immediate change over to multi agent chemotherapy consisting of Etoposide, Methotrexate, Adriamycin, Cyclophosphamide and Vincristine (EMACO) regimen. After 5 cycles without any surgical intervention she is in remission, and is on follow up for 6 months with no clinical, radiological or biochemical evidence of recurrence.

**Key words:** Recurrent Partial Molar Pregnancy, High Risk, Persistent trophoblastic tumour, Multi agent Chemotherapy.

### INTRODUCTION

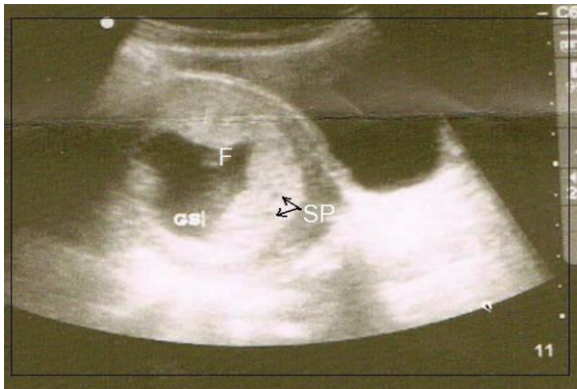Recurrent Partial molar pregnancy (RPMP) is a very rare clinical entity with about 8 cases published.<sup>[1]</sup> It is even rarer to come across Recurrent Partial Molar Pregnancy progressing to invasive partial molar pregnancy resistant to single agent chemotherapy. About 50 cases of persistent trophoblastic disease or invasive partial molar disease have been reported following partial moles, about 16 cases were high risk and needed multiagent chemotherapy. We report the 17<sup>th</sup> case and have discussed the clinical characteristics and management.

### CASE REPORT

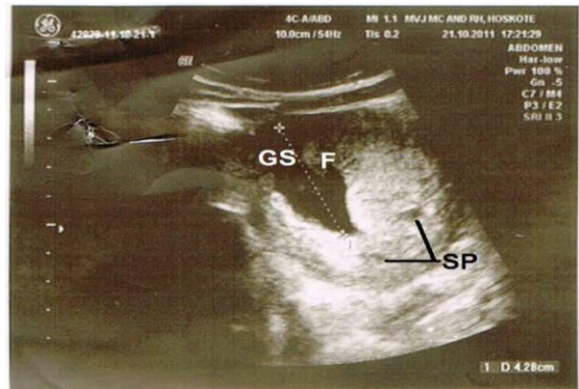
A 24 year old lady was referred with history of abortion at 9 weeks of amenorrhoea with a histopathologic diagnosis of partial molar pregnancy. Her past history confirmed previous two molar pregnancies. Third pregnancy was a partial molar pregnancy detected by ultrasound at 7 weeks of pregnancy; figure 1 and resulted in surgical termination of pregnancy with histopathologic evidence of partial mole. She was on follow up for 6 months with serum beta human chorionic gonadotrophin (S  $\beta$  hcg) values which normalised 2 weeks after the evacuation. She was lost to follow

up. Following 6 months, the fourth pregnancy resulted in an abortion of a partial molar pregnancy at 9 weeks of gestation confirmed sonologically and histologically, figure-2. All the four pregnancies were with the same partner. A pre- evacuation S-  $\beta$  hcg value was  $> 2,00,000$  mIU/ml. Post evacuation S-  $\beta$  hcg levels is represented in figure-3. By the end of the 4<sup>th</sup> week of evacuation, there was an increase in the S-  $\beta$  hcg values and hence single agent Methotrexate  $50 \text{ mg/M}^2$  was administered once weekly, intramuscularly. S-  $\beta$  hcg values continued to rise even after the third weekly dose. Sonography performed for recurrent bleeding, acute pain abdomen revealed the presence of an ill defined area of altered echogenicity measuring  $5.3 \times 3.8$

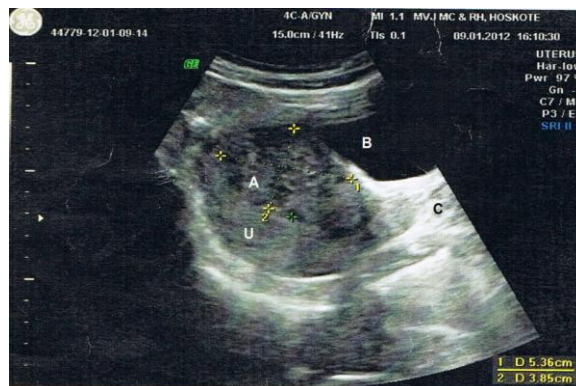cms, with areas of cystic degeneration in the anterior uterine wall with a possibility of invasive mole with impending rupture, figure-4. Her WHO score was 8, figure 5. Karyotyping of both partners was normal. She was immediately started on E- Etoposide, M-Methotrexate, A- Actinomycin, on day1 and day2, C- cyclophosphamide, O- vincristine on day8 (EMA-CO) and her S-  $\beta$  hcg regression curve is as depicted in the figure-6. She required totally 5 cycles. The last two cycles were administered following normalisation of the S-  $\beta$  hcg values. She is on follow up for 6 months and there is no clinical, radiological and biochemical evidence of recurrence and the couple are following barrier method of contraception.



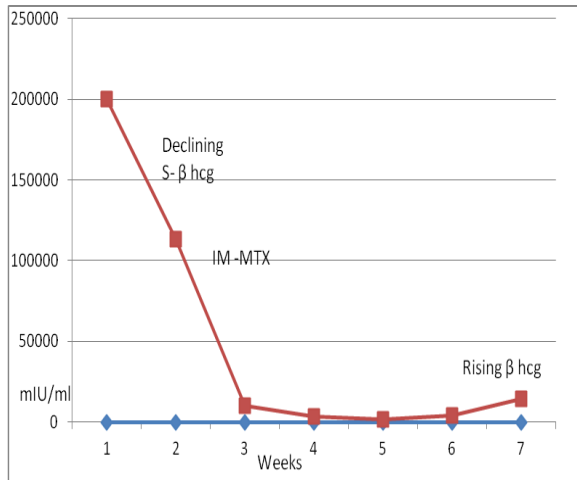
**Figure: 1** First partial molar pregnancy resulted in suction evacuation. GS- gestational sac. F- fetal pole, SP: cystic spaces in the placenta.



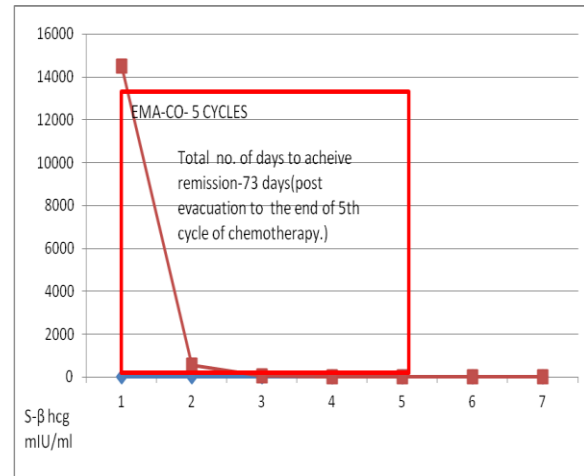
**Figure2:** Second partial molar pregnancy, GS- gestational sac. F- fetal pole, SP: cystic spaces in the placenta.



**Figure:3.** Pre-evacuation value  $> 2,00,000$  mIU/ml; post evacuation- 1<sup>st</sup> week: 1,13,250.80 mIU/ml; 2<sup>nd</sup> week- 10,408.80 mIU/ml, 3<sup>rd</sup> week- 3,403.38 mIU/ml, 4<sup>th</sup> week- 1818.00 mIU/ml; 5<sup>th</sup> week- 3,817.85 mIU/ml; 6<sup>th</sup> week- 14,523.14 mIU/ml. As there was inadequate log fall following the 2<sup>nd</sup> week of evacuation single agent, weekly once, IM- intramuscular MTX-methotrexate was started. By the 5<sup>th</sup> week the S-  $\beta$  hcg level started increasing.



**Figure 4:** Partial molar pregnancy progressing to invasive partial molar pregnancy. U- uterus, C-cervix, B-bladder, A- anterior uterine wall shows an ill defined area of altered echogenecity measuring 5.3x3.8 cms, with areas of cystic degeneration- mostly invasive mole with impending rupture



**Figure-6:** Prechemotherapy value -14, 523.14 mIU/ml, At the end of first cycle-548 mIU/ml  
At the end of second cycle-4.49 mIU/ml; At the end of third cycle-10.29 mIU/ml  
At the end of fourth cycle-5.04 mIU/ml; At the end of fifth cycle- 3.67 mIU/ml (first follow up)  
Second follow up- <0.100 mIU/ml ;Third follow up- <0.100 mIU/ml

**Figure-5** WHO scoring for gestatonal trophoblastic neoplasia.

PARAMETERS	SCORE-0	SCORE-1	SCORE-2	SCORE-4
Age (yr)	<40 *	≥40		
Antecedent pregnancy	MOLE*	ABORTION	TERM	
Interval months from index pregnancy	<4 MONTHS*	4-7 MONTHS	7-13 MONTHS	>13 MONTHS
Pretreatment serum hCG (IU/L)	<10 <sup>3</sup>	10 <sup>3</sup> -10 <sup>4</sup>	10 <sup>4</sup> -10 <sup>5</sup>	>10 <sup>5</sup> *
Largest tumor size (including uterus)		3CMS -5CMS	>5CMS*.	
Site of metastases	Lung	KIDNEY, SPLEEN	GASTROINTESTINAL TRACT /LIVER	BRAIN
Number of metastases	-	1-4	5-8	>8
Pre.failed CT	-	-	SINGLE DRUG*	2 OR MORE DRUGS.

\* SCORE-8-high risk

## DISCUSSION

The present case has many clinical implications, first it is very rare for a partial mole to recur about 8 cases have been published so far. [1] Second, to the best of our knowledge about 50 cases of persistent

gestational trophoblastic tumour or invasive partial moles following partial moles have been reported. 16 among them were high risk and required multi agent chemotherapy, the present case is the first case following recurrent partial molar pregnancies and 17<sup>th</sup>

case of post partial molar pregnancy progressing to persisting disease resistant to single agent chemotherapy and progressing to invasive partial mole and being successfully treated with 5 cycles of multi agent chemotherapy, sparing the uterus for future reproduction reported in the English medical literature. [2-8]

Studies have observed 0.9%- 2.8% of all partial molar pregnancy(PMP) patients needed treatment for malignant sequelae. The risk of a patient with PMP requiring chemotherapy for gestational trophoblastic tumour is of the order of 1 in 200, compared with 1 in 12 after a complete mole. The commonest site of metastasis is lungs and need for post evacuation follow up has been discussed. [2,4,7,8]

Growdon WB et al [9] have opined that a hCG level >199 mIU/mL in the third through eighth week following molar evacuation was associated with at least a 35% risk of Gestational Trophoblastic Neoplasia(GTN). Women with partial mole who have elevated hCG levels within the first few weeks (as early as the second week) after molar evacuation are at an increased risk for developing GTN. [10] Similar experience is shared by us as shown in figure 3. In the present case since the pre-evacuation S  $\beta$  hcg was > 2,00,000 mIU/mL and a week later 1,13,250 mIU/mL. She was administered intramuscular Methotrexate 50 mg/M<sup>2</sup> once weekly once for 3 weeks. Since the S-  $\beta$  hcg levels were increasing, she was referred to our tertiary centre. She belonged to the high risk group with a score of 8( WHO scoring).

There was an adequate log fall after each cycle of chemotherapy. From a pre multiagent chemotherapy S  $\beta$  hcg value of 14,523.14 mIU/ml it was 548 mIU/ml after first cycle, 44.9 mIU/ml after the second cycle and 10.29 mIU/ml after the third cycle. At the end of 3<sup>rd</sup> cycle of EMA-CO, chest x-ray was normal, ultrasound revealed

a normal uterine size, but the endometrial differentiation was lost and an ill defined complex anechoic lesion was noted in the anterior wall measuring 3.7x1.9 cms (reduced in size). S  $\beta$  hcg was 10.29 mIU/ml. It was then decided to give two more cycles of EMA-CO. Chen RJ et al [4] have reported the need for hysterectomy in two cases for achieving remission. Decision for uterine conservation was taken as the couple was childless. Eventually the uterine mass disappeared by the end of 5<sup>th</sup> cycle of chemotherapy and her S- $\beta$  hcg levels were 5.02 mIU/ml and 3.67 mIU/ml after the fourth and fifth cycles respectively. In the present case the interval from starting treatment to remission was 73 days, similar findings are reported by Chen et. al.1994. She is on follow up and there is no clinical, radiological or biochemical evidence of disease.

Recurrent partial molar pregnancies may progress to invasive partial moles leading to catastrophic events such as intraperitoneal bleed. Prompt recognition and immediate treatment with multi agent chemotherapy can be life saving! Deterrence of uterine surgery to preserve fertility has paramount importance in the clinical management for future reproductive performance. Therefore, a close follow up with serial S- $\beta$  hcg estimation is essential, following a partial molar pregnancy.

#### ACKNOWLEDGEMENT

We thank Dr. Pallavi.R, Dr.Praveen.S.R, Dr.Shobha.K, Dr. Abhilasha.N., Dr. Anil.M, for their inputs in patient care. We appreciate the dedication and empathy shown by senior staff Mrs. Padma and her team for nursing care, which helped the patient and her family tide over psychological issues.

#### REFERENCES

1. Koc S, Ozdegirmenci O, Tulunay G, Ozgul N, Kose M.F. & Bulbul D. Recurrent partial hydatidiform mole. A

- report of a patient with three consecutive molar pregnancies. *Int J Gynecol Cancer* 2006;16: 884–943
2. Bagshawe KD, Lawler SD, Paradinas FJ, Dent J, Brown P, Boxer GM. Gestational trophoblastic tumours following initial diagnosis of partial hydatidiform mole. *Lancet*. 1990 May 5;335(8697):1074-6.
  3. Goto. S, Yamada. A, Ishizuka.T, Tomoda. Y. Development of Postmolar Trophoblastic Disease after Partial Molar Pregnancy. *Gynecologic Oncology*, Volume 48, Issue 2, Feb 1993, 165–170.
  4. Chen RJ, Huang SC, Chow SN, Hsieh CY, Hsu HC. Persistent gestational trophoblastic tumour with partial hydatidiform mole as the antecedent pregnancy. *Br J Obstet Gynaecol*. 1994 Apr;101(4):330-4.
  5. Paradinas. F.J, Browne P, Fisher R.A, Foskett M, Bagshawe K.D, Newlands E. A clinical, histopathological and flow cytometric study of 149 complete moles, 146 partial moles and 107 non-molar hydropic abortions, *Histopathology*. Vol 28, ( 2,) Feb.1996\_101–109
  6. Wilesma. S, Kerkmeijer. L, Bekkers. R , Pyman. J, Tan. J, Quinn. M · Persistent trophoblast disease following partial molar pregnancy. *Australian and New Zealand Journal of Obstetrics and Gynaecology*. Volume 46, Issue 2, pages 119–123, April 2006
  7. Hancock BW, Nazir K, Everard JE. Persistent gestational trophoblastic neoplasia after partial hydatidiform mole incidence and outcome. *J Reprod Med*. 2006 Oct;51(10):764-6.
  8. Sebire NJ, Fisher RA, Foskett M, Rees H, Seckl MJ, Newlands ES. Risk of recurrent hydatidiform mole and subsequent pregnancy outcome following complete or partial hydatidiform molar pregnancy. *BJOG* 2003;110:22–6
  9. Growdon WB, Wolfberg AJ, Feltmate CM, Goldstein DP, Genest DR, Chinchilla ME, Berkowitz RS, Lieberman ES. Postevacuation hCG levels and risk of gestational trophoblastic neoplasia among women with partial molar pregnancies. *J Reprod Med*. 2006 Nov;51(11):871-4.
  10. Kim BW, Cho H, Kim H, Nam EJ, Kim SW, Kim S, Kim YT, Kim JH. Human chorionic gonadotrophin regression rate as a predictive factor of postmolar gestational trophoblastic neoplasm in high-risk hydatidiform mole: a case-control study. *Eur J Obstet Gynecol Reprod Biol*. 2012 Jan;160 (1):100-5. Epub 2011 Nov 3.

How to cite this article: Shakuntala PN, Bafna UD, Anbukhani S et. al. High risk gestational trophoblastic neoplasia following recurrent partial molar pregnancy: a case report and review of literature. *Int J Health Sci Res*. 2013;3(1):50-54.

\*\*\*\*\*