



Original Research Article

Morphological Study of Branches of Femoral Artery in the Femoral Triangle- A Human Cadaveric Study

Shaik Ahammad Peera^{1*}, Raju Sugavasi²

¹Assistant Professor, ²Tutor,

Dept. of Anatomy, RIMS Medical College, Rajiv Gandhi Institute of Medical Sciences, Kadapa, 516002. A.P. India.

*Correspondence Email: peersanatomy2013@yahoo.com.

Received: 26/09/2013

Revised: 30/10/2013

Accepted: 31/10/2013

ABSTRACT

OBJECTIVES: To study the origin and course of various branching pattern of femoral artery and to measure the distance from the point of origin to mid inguinal point and also the side of origin of all branches of femoral artery. **MATERIALS & METHODS:** A total of 40 femoral triangles were dissected from 40 adult human cadavers for present study. **RESULTS:** Superficial epigastric, superficial circumflex iliac and superficial external pudendal arteries arising from femoral artery as separate branches in 68.3% within femoral sheath. The mean distance from the point of origin of all superficial arteries was found within 3.5cm and profunda femoris artery was 3.28cm from femoral artery. Medial circumflex femoral artery arises frequently from femoral artery by 20% and lateral circumflex femoral artery was by 15%. The mean distance from the mid inguinal point to the origin of Medial circumflex femoral artery was 2.68cm when it arises from femoral artery and 4.5cm when it arises from profunda femoral artery. The mean distance from the mid inguinal point to the origin of lateral circumflex femoral artery was 4.5cm when it arises from femoral artery and 5.46cm when it arises from profunda femoral artery. **CONCLUSION:** Anatomical knowledge of branching pattern of femoral and profunda femoral artery and their distance of origin is very important to surgeons to avoid the complications in vascular reconstructive surgeries. Detailed conclusions were discussed in the following text.

KEY WORDS: Femoral artery, lateral circumflex femoral artery, Medial circumflex femoral artery

INTRODUCTION

The normal anatomy and variations in origins of the superficial femoral, profunda femoral, medial circumflex femoral and lateral circumflex femoral arteries are very important for clinicians for interventional procedures like arterial catheterization and coronary angioplasty and surgical procedures like vascular reconstructive surgeries. Femoral artery

enters the thigh point midway between anterior superior iliac spine and the pubic symphysis and it produces pulsations at this point. This place is useful for the femoral catheterization. ^[1]

The femoral artery gives off numerous branches in the proximal part of thigh includes, superficial epigastric artery arises anteriorly from the femoral artery approximately 1 cm distal to the inguinal

ligament. The superficial circumflex iliac artery arises near or along with the superficial epigastric artery. The superficial external pudendal artery arises medially from the femoral artery, close to the preceding branches. The profunda femoris artery is a larger branch of the femoral artery which arises laterally about 3.5 cm distal to the inguinal ligament. The lateral circumflex femoral artery is a laterally running branch given off near the root of the profunda femoris artery. The medial circumflex femoral artery arises from the posteromedial aspect of the profunda femoris artery. [2]

MATERIALS & METHODS

A total number of 40 lower limbs were selected for this study. This study was conducted in Department of Anatomy, Narayana medical college, Nellore, Andhra Pradesh, India. Cadavers were preserved by procedure of embalming by injecting the 5% formalin and observed the branches of femoral artery by dissecting the femoral

triangles. The origin and course of major branches of femoral artery was studied. The origin of the profunda femoris artery was measured by scale from the mid inguinal point. The origin and distance of the medial and lateral circumflex femoral arteries was measured from the site of their origin from the profunda femoris artery.

RESULTS

In the present study out of 40 specimens, 29 (72.25%) cases superficial external pudendal artery arise from femoral artery as a separate branch and 11 (27.75%) cases arise as a common trunk with other arteries from femoral artery (FIG.01). It arose 0.5 to 6.0 cm from the midpoint of inguinal ligament. It arose within 3.0 cm in 18 specimens and between 3.1 and 6.0 in 22 specimens (45% and 55%). It arises from medial side of femoral artery in 27 (67.5%) specimens, anterior side in 6 (15%) and anteriomedial side in 4 (10%), from lateral side in 1 (2.5%) specimen.

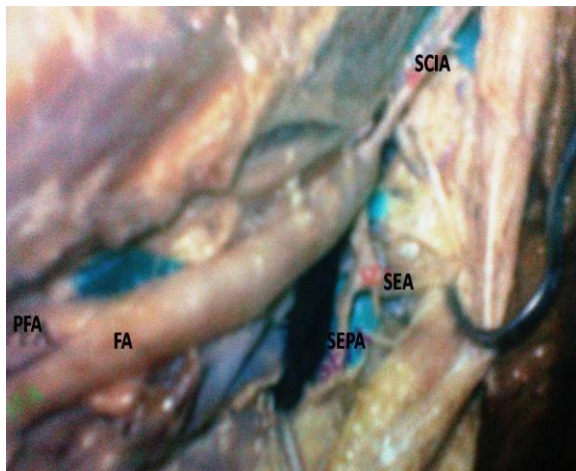


FIG.01: Superficial external pudendal artery and superficial epigastric artery arising from femoral artery as a common trunk. FA: Femoral artery, PFA: Profunda Femoral Artery, SCIA: superficial circumflex iliac Artery, SEA: superficial epigastric Artery, SEPA: superficial external pudendal Artery.



FIG.02: Deep External Pudendal Artery arising from femoral artery. SFA: Superficial Femoral Artery, PFA: Profunda Femoral artery, LCFA: Lateral circumflex Femoral Artery, DEPA: Deep External Pudendal Artery.

Out of 40 specimens, 28 (70%) cases superficial epigastric artery arise from femoral artery as a separate branch and 12 (30%) cases arise as a common trunk with

other arteries from femoral artery. It arose 0.5 to 5.0 cm from the midpoint of inguinal ligament. It arose within 3.0 cm in 35 (87.5%) specimens and between 3.1 and 5.0

in 5 (12.5%) specimens. It arises from anterior side in 15 (37.5%) specimens, anterolateral side in 10 (25.0%), lateral side in 7 (17.5%) medial side in 5 (12.5%), anteromedial in 2 (5%), posterolateral in 1 (2.5%) from femoral artery.

Out of 40 specimens, 25 (62.5%) cases superficial circumflex iliac artery arise from femoral artery as a separate branch and 13 (32.5%) cases arise as a common trunk with other arteries from femoral artery and 2

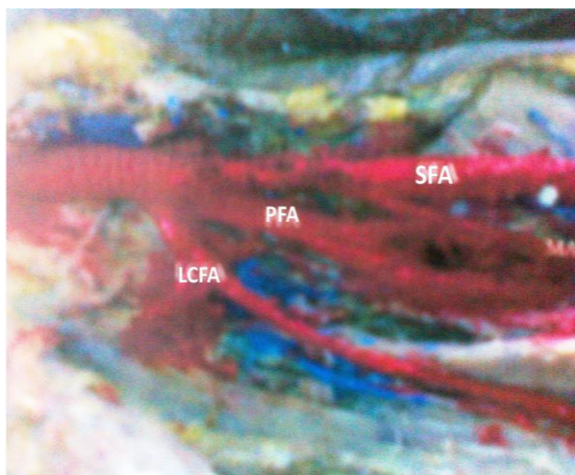


FIG.03: Profunda femoral Artery arising from femoral artery. SFA: Superficial Femoral Artery, PFA: Profunda Femoral artery, LCFA: Lateral circumflex Femoral Artery.

Out of 40 specimens, 29 (72.5%) cases deep external pudendal artery arise from femoral artery as a separate branch (FIG.02) and 10 (25%) cases arise as a common trunk with superficial external pudendal artery and with profunda femoral artery in 1 (2.5%). The distance from point of origin to midpoint of inguinal ligament ranges from 2.6 to 7.5 cm. In 36 (90%) of cases it arises between 3.1 to 7.5 cm and only in 4 cases it arises within 3 cm (10%). It arises from medial side in 37 (92.5%), anterior, posterior, posterior medial one in each case (2.5%) from femoral artery.

Out of 40 specimens, 38 (95%) cases profunda femoris artery arise from femoral artery as a separate branch (FIG.03) and 2 (5%) cases arise as a common trunk with

(5.0%) from profunda femoral artery. It arose 0.4 to 4.5 cm from the midpoint of inguinal ligament. It arose within 3 cm in 37 (92.5%) specimens and between 3.1 and 4.5 cm in 3 (7.5%) specimens. It arises from anterior side in 7 (17.5%) specimens, anterolateral side in 9 (22.5%), lateral side in 20 (50.0%) medial side in 1 (2.5%), anteromedial in 1 (2.5%), posterolateral in 2 (5%) from femoral artery.

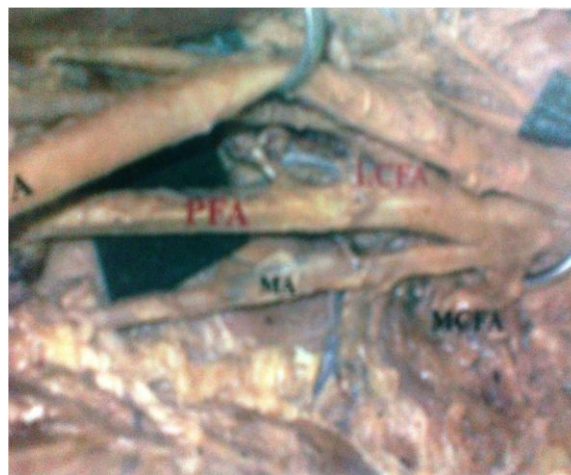

FIG.04: Medial circumflex Femoral Artery arising from femoral Artery. SFA: Superficial Femoral Artery, PFA: Profunda Femoral artery, MCFA: Medial circumflex Femoral Artery, MA: Muscular Artery.

medial circumflex femoral artery. The distance from point of origin to midpoint of inguinal ligament ranges from 0.5 to 5.5 cm. It arises within 3 cm in 15 specimens (38.46%) and between 3.1 to 5.5 cm in 24 (61.53%) cases. The mean distance from the mid inguinal point was 3.28 cm. It arises from posterior lateral side in 25 (64.10%), posterior side in 10 and lateral side in 4 (10.25%).

Out of 40 specimens, 30 (75%) cases medial circumflex artery arise from profunda femoris artery, from femoral artery in 8 (20%) (FIG.04) and 2 (5%) cases arise as a common trunk with profunda femoris artery. The distance from point of origin of medial circumflex artery to midpoint of inguinal ligament ranges from 1 to 8 cm.

The origin was within 3 cm in 17 specimens (42.5%) and between 3.1 to 8 cm in 23 (57.5%) cases. The mean distance from the mid inguinal point was 3.68 cm when it arises from profunda femoris artery and 2.68 when it arises from femoral artery. The mean distance from medial circumflex artery to the origin of profunda femoris artery was 1.4 cm. It arises from medial side in 27 (67.5%), posterior medial side in 8 (20.0%) and posterior side in 5 (12.5%).

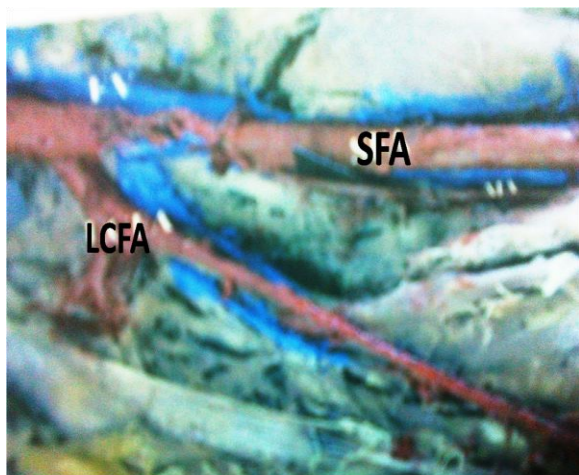


FIG.05: Lateral circumflex Femoral Artery arising from femoral Artery. SFA: Superficial Femoral Artery, LCFA: Lateral circumflex Femoral Artery.

Out of 40 specimens, 32 (80%) cases lateral circumflex artery arise from profunda femoris artery, from femoral artery in 6 (15%) (FIG.05) and 2 (5%) cases arise as a common trunk with profunda femoris artery. The distance from point of origin of lateral circumflex artery to midpoint of inguinal ligament ranges from 2 to 7 cm. The origin was within 3 cm in 2 specimens (5%) and between 3 to 7 cm in 38 (95%) cases. The mean distance from the mid inguinal point was 5.46 cm when it arises from profunda femoris artery and 4.5 when it arises from femoral artery. The mean distance from origin of lateral circumflex artery to the origin of profunda femoris artery was 2.2 cm. It arises from lateral side in 35 (87.5%),

posterior lateral side in 4 (10%) and anterolateral side in 1 (2.5%).

DISCUSSION

Hollinshed WH (1966) [3] mentioned that the superficial epigastric, superficial circumflex iliac, and superficial external pudendal arteries arise close together, sometimes by a common stem to two or all three of them, from upper few centimeters of femoral artery. Siddharth P (1985) [4] studied 100 femoral triangle, the profunda femoral artery originates at a mean distance of 4.4 cm from inguinal ligament and when the lateral circumflex femoral artery branched from this at mean distance of 1.5 cm. The medial circumflex femoral artery originated from profunda in 63% and aroused from common femoral about 2.15cm above the profunda femoral artery. Perera J (1995) [5] studied 124 femoral triangles and classified origin of circumflex femoral arteries as, in group A medial and lateral circumflex femoral arteries arose from common femoral, in group B both one or both arose from common femoral artery. There is a distal migration of level of origin of the profunda femoral artery when one or both circumflex arteries arose from common femoral artery. Dixit DP (2001) [6] dissected 48 femoral triangles and observed that, the site of origin of profund femoral was most commonly located between inguinal ligament and apex of the femoral triangle and very few origins were above and below mid points.

According to Samarawickrama MB (2009) [7] 26 femoral triangles, the distance of origin of profunda femoris was right side between 51 and 70mm, whereas on the left side it was between 21 and 50mm from midpoint of inguinal ligament. The origin of the lateral circumflex femoral artery from the profunda femoris artery, on the right side was 12 out of 13 cases (92%) and distance was between 01 and 40 mm from profunda

artery. Medial circumflex femoral arises from profunda artery at distance of between 01 and 30mm on the right side and between 11 and 40mm on the left side. According to Suthar K (2013) [8] 50 femoral triangles, The average distance of the superficial circumflex iliac artery was 12.6 mm on right side and 14.4 mm on left side and it arises from lateral side in all cases. The average distance of the superficial epigastric artery was 23.08 mm on right side and 22.28 mm on left side but, superficial external pudendal artery 26.4mm on right side and 26.5mm on left side from the mid inguinal point. The origin of profunda femoris artery was posteriorly in 4 cases out of 50 in right side and 3 out of 50 on left side, posterolaterally in 26 cases out of 50 in right side and 28 out of 50 on left side and laterally in 20 out of 50 on right side and 19 out of 50 on left side of the common femoral artery. The distance of origin of profunda femoris artery was 40 and 60mm on the both sides commonly from the mid inguinal point but average was 47.9 mm on right side and 44.5 mm on left side. In 10 cases (20%), Lateral circumflex femoral artery directly arises from the femoral artery out of which 6 cases are bilateral. The average distance of the lateral circumflex femoral artery origin from the mid inguinal point was 65.93mm on right side and 63.95 mm on left side. In 18 cases (36%), Medial circumflex femoral artery arises directly from the femoral artery out of which 9 cases are bilateral. Average distance from the origin of the mid inguinal point was 67.45mm on right side and 69.08 mm on the left side.

Marina Baptist (2007) [9] dissected 40 femoral triangles and observed that, out of 40, 12 to 14 cases profunda femoris artery was taken origin 20-40 mm from midpoint of the inguinal ligament and in 6-8 cases lower than the common location. Medial circumflex artery arises from the femoral artery in only in one case and it was seen at

the level of origin of profunda femoris artery. Lateral circumflex artery also originated directly from the femoral artery in only one case unilaterally. Shetty AS (2012) [10] showed the awareness of the vascular variation of lower limb is significant in catheterization procedures, vascular reconstructive surgeries, surgical interventions for embolism.

CONCLUSION

Morphological study of branching pattern of femoral artery and its anatomical variation is significant for the interventional radiological procedures like angiography, color Doppler and vascular reconstructive surgeries.

ACKNOWLEDGEMENTS

I am grateful to the almighty LORD JESUS CHRIST for his grace & love to do this work. My sincere thanks to Dr. Gajendra, Professor, Department of Anatomy for his guidance and support to complete this study. I am thankful to all previous authors and publishers from where I have gathered the data for this study.

REFERENCES

1. Chummy S S. Lasts Anatomy Regional and Applied. 10th Edn. Churchill Livingstone, UK, 1999; pp 114 –115.
2. Standring S. Gray's anatomy. The anatomical basis of the Clinical Practice. 39th edition. Edinburg. Churchill Livingstone Elsevier, 2005; 1451.
3. Hollinshed WH. Anatomy of surgeons. Vol 1, Philadelphia, Hoeber Harper International; 1966: 705.
4. Siddharth P, Smith NL, Mason RA, Giron F, Variational anatomy of deep femoral artery. Anat Rec. 1985; 212 (2): 206-209.

5. Perera J, Anatomy of origin of deep femoral artery. Ceylon med J. 1995; 40 (4): 139-41.
6. Dixit DP, Mehata LA, Kothari ML. Variations in the origin and course of profunda femoris. J Anat Soc India. 2001; 50(1): 6-7.
7. MB Samarawickrama, BG Nanayakkara, KWRW Imalagunarithna, DGN Ishantha, UB Walawage. Branching pattern of the femoral artery at the femoral triangle: a cadaver study. Galle Medical Journal, 2009; 14(1): 31-34.
8. Suthar K, Patil D, Mehta C, Patel V, Prajapati B, Bhatt C. Morphological study of branches of femoral artery in front of thigh: cadaveric study. Journal of Surgery, 2013; 2 (2): 16-22.
9. Marina Baptist, Tassaduq hussain, Ferdose Sultana. The origin of profunda femoris artery, its branches and diameter of the femoral artery. Professional med J. 2004; 14 (5); 523-527.j
10. Shetty AS, Santosh S, Pamidi M, Jetti R. An atypical oversized lateral circumflex femoral artery and its clinical implications. Journal of Clinical and Diagnostic Research. 2012; 6(7): 1284-1285.

How to cite this article: Peera SA, Sugavasi R. Morphological study of branches of femoral artery in the femoral triangle- a human cadaveric study. Int J Health Sci Res. 2013;3(12):14-19.

International Journal of Health Sciences & Research (IJHSR)

Publish your work in this journal

The International Journal of Health Sciences & Research is a multidisciplinary indexed open access double-blind peer-reviewed international journal that publishes original research articles from all areas of health sciences and allied branches. This monthly journal is characterised by rapid publication of reviews, original research and case reports across all the fields of health sciences. The details of journal are available on its official website (www.ijhsr.org).

Submit your manuscript by email: editor.ijhsr@gmail.com OR editor.ijhsr@yahoo.com