



Case Report

## **Pneumococcal Cellulitis: An Unusual Manifestation of Streptococcus Pneumoniae**

Banashankari GS<sup>1\*</sup>, Rudresh HK<sup>2</sup>, Shikha Ranjan<sup>1</sup>

<sup>1</sup>Department of Microbiology, <sup>2</sup>Department of Surgery  
M S Ramaiah Medical College, Bangalore-560054, Karnataka, India

\*Correspondence Email: banashankarigs@gmail.com

Received: 27/08/2013

Revised: 24/09/2013

Accepted: 26/09/2013

### **ABSTRACT**

*Streptococcus pneumoniae* (Strep. pneumoniae/pneumococci) is the most common cause of Community acquired pneumonia, however it rarely manifests as cellulitis. Typically the patients with cellulitis due to Strep. pneumoniae (pneumococcal cellulitis) present with chronic underlying diseases like diabetes mellitus, alcoholism, systemic lupus erythematosus (SLE), nephrotic syndrome and haematological disorders. Early recognition, surgical intervention with appropriate antibiotic therapy plays a vital role in decreasing the rate of morbidity & mortality of the patients.

Here we present a case of primary pneumococcal cellulitis of dorsum of the hand in a known diabetic patient without blood stream invasion.

**Key- Words:** Streptococcus pneumoniae, pneumococcal cellulitis, diabetes mellitus

### **INTRODUCTION**

*Streptococcus pneumoniae* (strep. pneumoniae/pneumococci) are Gram positive lanceolate shaped capsulated diplococci which are normal inhabitants of human upper respiratory tract. It is the most prevalent cause of pneumonia, otitis media, sinusitis, bronchitis, bacteremia and other infections.<sup>[1-3]</sup>

Although Strep. pneumoniae remains the most common cause of Community acquired bacterial pneumonia, its involvement in skin and subcutaneous infection is notably infrequent.<sup>[4]</sup> Strep. pneumoniae is a rarely diagnosed etiology of cellulitis in adults though frequently associated with blood stream invasion.

Cellulitis due to strep.pneumoniae (Pneumococcal cellulitis) can present itself as two distinctive clinical syndromes. First, is involvement of extremities in patients with diabetes mellitus. Secondly, involving head and neck in patients with systemic lupus erythematosus (SLE), nephrotic syndrome and haematological disorders.<sup>[5]</sup>

Skin and soft tissue infections due to pneumococci is rare and is more prone to occur in people with chronic illness like diabetes mellitus or alcohol abuse.<sup>[6]</sup>

### **CASE HISTORY**

A 76 year old male patient, known diabetic on treatment from past 40 years presented with complaints of fever,

generalised weakness and swelling on the dorsum of the left hand since four days. The swelling was insidious in onset, gradually increasing in size and associated with pain.

On Local examination there was a diffuse swelling on the dorsum of the left hand. The skin over the swelling was

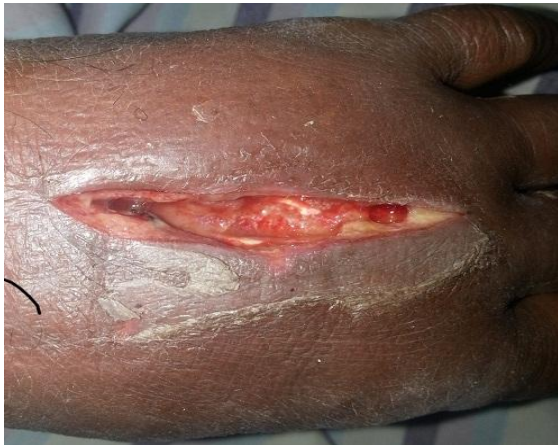

Figure 1: Cellulitis of the dorsum of the left hand.

erythematous with local rise in temperature. Peripheral pulses were palpable.

It was diagnosed as cellulitis with abscess by the surgeon. Incision and Drainage and fasciotomy was performed. Pus was sent to microbiology laboratory, where it was processed according to standard procedures. [Figure 1]

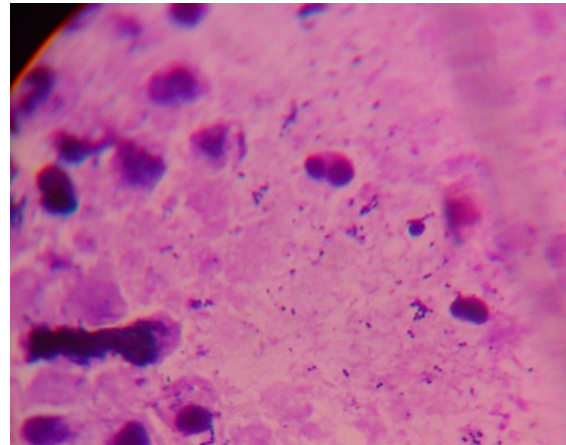


Figure 2: Gram's stain showing numerous WBCs and numerous Gram Positive lanceolate shaped diplococci.

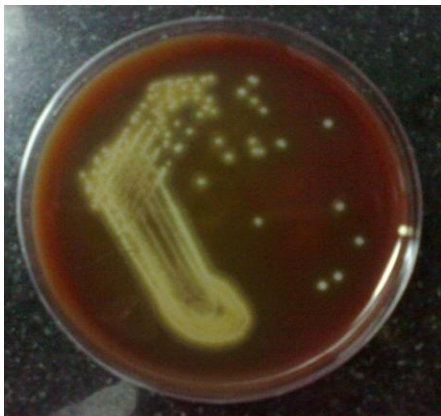

Figure 3: Blood agar plate showing  $\alpha$ -hemolytic colonies.

Gram's stain showed numerous WBCs and numerous Gram positive lanceolate shaped diplococci morphologically resembling *Strep. pneumoniae*. [Figure 2]

Sample was inoculated on to 5% sheep blood agar and chocolate agar. After 18-24hours of incubation in CO<sub>2</sub> jar, blood agar showed  $\alpha$ -hemolytic colonies with

central umbonation and chocolate agar showed small colonies with greenish discoloration around the colonies. [Figure 3]

Gram stain was performed from these colonies which revealed the presence of Gram positive lanceolate shaped capsulated diplococci.

The colonies were catalase negative, bile soluble and susceptible to Optochin and Bacitracin. Antibiotic sensitivity testing was performed on blood agar by Kirby Bauer disc diffusion method. The isolate was susceptible to Penicillin, Linezolid, Chloramphenicol, Co-trimoxazole, Amoxicillin-clavulanic acid, Cefuroxime, Ceftriaxone, Clindamycin, Erythromycin and Vancomycin.

A repeat sample was requested as *Strep.pneumoniae* is rarest of the causative agents of cellulitis which also showed the same result as that of the 1<sup>st</sup> sample. The blood culture of the patient did not yield any

growth neither the patient had any underlying respiratory infections.

Patient was treated with Linezolid-600mg bid intravenously for initial two days followed by oral administration for 8 days. Patient responded dramatically to the treatment and recovered within a week.

## DISCUSSION

Although *Strep.pneumoniae* is a part of normal upper respiratory flora, it is a leading etiology of pneumonia and meningitis with or without bacteremia.<sup>[1]</sup> It is the commonest etiological agent of Community acquired pneumonia and may also be associated with suppurative complications like arthritis, meningitis, empyema and endocarditis.

*Strep.pneumoniae* may be a skin coloniser or a soft tissue pathogen which may cause clinical diseases that may widely vary in their severity and prognosis.

Cellulitis of extremities due to *Strep.pneumoniae* either as a primary infection or as a consequence of bacteremia is an unusual manifestation of pneumococcal infection.<sup>[3,4,6]</sup>

Majority of the patients with pneumococcal cellulitis are usually associated with severe underlying diseases like diabetes mellitus, alcoholism, connective tissue disorders.<sup>[6,7]</sup>

There are many virulence factors expressed by *Strep.pneumoniae*, but the most important being the polysaccharide capsule as it interferes with phagocytosis and inhibits the complement C3b opsonisation of bacterial cells. Pili of the bacteria may contribute to its colonisation in respiratory tract.<sup>[2,6]</sup>

The pathogenesis of pneumococcal cellulitis is unknown however Capdevila et al have hypothesised few possible mechanisms which are as follows<sup>[7]</sup>:

- a. Organisms may spread from underlying respiratory tract infection

(e.g. sinusitis) through the subcutaneous tissue on to overlying skin.

- b. Organisms may penetrate through the damaged site of the skin (e.g. scratches), either coughed over or exhaled on to the skin with contaminated saliva or sputum.
- c. Organisms may spread hematogenously directly on to the skin without involving deeper tissues or with involvement of skeletomuscular structures (e.g. arthritis) causing cellulitis of the involved structures.

A literature review by Parada and Maslow et al have suggested two different clinical syndromes of pneumococcal cellulitis, first is where the patient's head and neck is involved who has background of SLE, nephrotic syndrome and haematological disorders.<sup>[5]</sup> This could be because of close proximity of colonisation in pharynx that might have initiated the event.<sup>[6]</sup> Secondly, it includes patients with history of diabetes mellitus, alcoholism & drug abuse who presents with cellulitis of limbs.<sup>[8-10]</sup>

Pneumococcal cellulitis is frequently associated with blood stream infection and presents with localised erythema and oedema.<sup>[6]</sup>

Our case also had favourable features as above, i.e. the patient was known diabetic on treatment and lesion was involving the dorsum of hand (i.e. extremity) with erythema and oedema.

*Strep.pneumoniae* is delicate organism that is easily destroyed by heat and antiseptics. They are highly sensitive to most of the antibiotics, beta-lactams being the drug of choice.<sup>[2]</sup> Patients with pneumococcal cellulitis usually require surgical intervention with adequate antibiotic therapy.<sup>[6]</sup>

In our case also Incision and Drainage with fasciotomy was performed followed by antibiotic therapy with Linezolid which gave a dramatic relief to the patient.

The mortality due to pneumococcal cellulitis varies between 10-23%.<sup>[6]</sup> Therefore, high degree of suspicion, early diagnosis and prompt treatment will bring down the morbidity and mortality of pneumococcal cellulitis.

Our case assumes its significance as pneumococcal cellulitis is a rare manifestation of pneumococcal infection and there was no blood stream invasion by the bacteria.

### CONCLUSION

To conclude, Pneumococcal cellulitis is a very rare manifestation of pneumococcal infections. Most of the times, pneumococcal cellulitis is usually associated with chronic underlying diseases and involves the extremities. Surgical intervention with appropriate antibiotic therapy will help in faster recovery of the patient. Therefore, a high degree of suspicion and early aggressive treatment will bring down the rates of mortality and morbidity of pneumococcal cellulitis.

### REFERENCES

1. Forbes BA, Sahm DF, Weissfeld AS. Streptococcus, Enterococcus and similar organism. Bailey & Scott's Diagnostic Microbiology, 10th ed. Chicago: Mosby publications; 1998.p. 619-35.
2. Ananthanarayan R, Paniker CK. Pneumococcus. Ananthanarayan and

- Paniker's Textbook of Microbiology, 7th ed. Chennai: Oriental Longman; 2005.p. 216-21.
3. Kumar S, Umadevi S, Easow JM et al. Anterior abdominal wall abscess caused by Streptococcus pneumoniae in a patient with self-inflicted stab injury: An unusual presentation. J Infect DevCtries 2011; 5(4):307-09.
4. Lawlor MT, Crowe HM, Quintiliani R. Cellulitis due to Streptococcus pneumoniae: case report and review. Clin Infect Dis 1992; 14(1):247-50.
5. Parada JP, Maslow JN. Clinical syndromes associated with adult pneumococcal cellulitis. Scand J Infect Dis 2000; 32(2):133-6.
6. Hakeem LM, Urolagin M, Bhattacharyya DN et al. Haemorrhagic bullous Streptococcus pneumoniae cellulitis in type 2 diabetes mellitus. Br J Diabetes Vasc Dis 2008; 8:75-9.
7. Capdevila O, Grau I, Vadillo M et al. Bacteremic pneumococcal cellulitis compared with bacteremic cellulitis caused by Staphylococcus aureus and Streptococcus pyogenes. Eur J ClinMicrobiol Infect Dis 2003; 22(6):337-41.
8. Dhaene M, Thys JP, Askenasi R et al. Pneumococcal cellulitis. Am J Emerg Med 1986; 4:225-6.
9. Plotkin GR, Patel BR, Shah VN. Diabetic foot complicated by pneumococcal cellulitis. South Med J 1986; 79:390.
10. Verheist JA, Delvigine C. Pneumococcal osteomyelitis and cellulitis in a patient with diabetes mellitus. Diabetic Med 1988; 5:393-5.

How to cite this article: Banashankari GS, Rudresh HK, Ranjan S. Pneumococcal cellulitis: an unusual manifestation of Streptococcus pneumoniae. Int J Health Sci Res. 2013;3(11):135-138.

\*\*\*\*\*