



Review Article

A Clinical Insight of Deep-Bite and Its Management

Pavithra.A.S.^{1*}, Roopa. S.²

¹Senior Lecturer, Department of Orthodontics & Dentofacial Orthopaedics, Sri Hasanamba Dental College & Hospital, Hassan. Karnataka, India.

²Research Scholar, Department of Orthodontics & Dentofacial Orthopaedics, Vokkaligara Sangha Dental College & Hospital, Bangalore, Karnataka, India.

*Correspondence Email: dr.pavithra_3@yahoo.co.in

Received: 23/08/2013

Revised: 17/09/2013

Accepted: 23/09/2013

ABSTRACT

A deep bite is one of the most common malocclusions seen in children and adults that can occur along with other associated malocclusions. The etiology may be present at different levels of structures; it can be dental, skeletal or combination. The correction of deep bite is one of the primary objectives of orthodontic treatment and one of the most difficult to treat successfully. The treatment plan depends upon the severity and age of the patient. Each approach has its own advantages and disadvantages and optimal correction of deep overbite requires accurate diagnosis, individualized treatment planning and efficient execution of treatment mechanics. A review of deep bite in general with due reference to some treated cases is done in this article. This clinical review article is an attempt to enlist various modalities of deep bite correction presently available to the clinician and also gives a brief insight into the diagnostic and selection criteria to be applied for successful and stable deep bite correction.

Key words: Deep bite, Dental, Skeletal, Treatment.

INTRODUCTION

Graber ^[1] has defined 'Deep bite' as a condition of excessive overbite, where the vertical measurement between the maxillary and mandibular incisal margins is excessive when the mandible is brought into habitual or centric occlusion'. Chaconas ^[2] considers it in percentage and mentions that a normal overbite exists when close to 20% of the labial surface of the lower incisors is covered by the upper incisors.

Excessive overbite is most prevalent in the mixed dentition and is a self correcting transient malocclusion. It is said

to be one of the most deleterious malocclusion when considered from the viewpoint of the future health of the masticatory apparatus and the dental units. It may jeopardize the periodontal support, occlusion itself or TMJ. ^[3]

Classification

1. According to its origin:

- a) Dental deep bite (Simple).
- b) Skeletal deep bite (Complex).

2. According to functional classification:

- a) True deep bite.
- b) Pseudo deep bite.

3. Depending on the extent of deep bite:

- a) Incomplete over bite
- b) Complete over bite

4. According to dentition:

- a) Primary dentition deep bite.
- b) Mixed dentition deep bite.
- c) Permanent dentition deep bite.

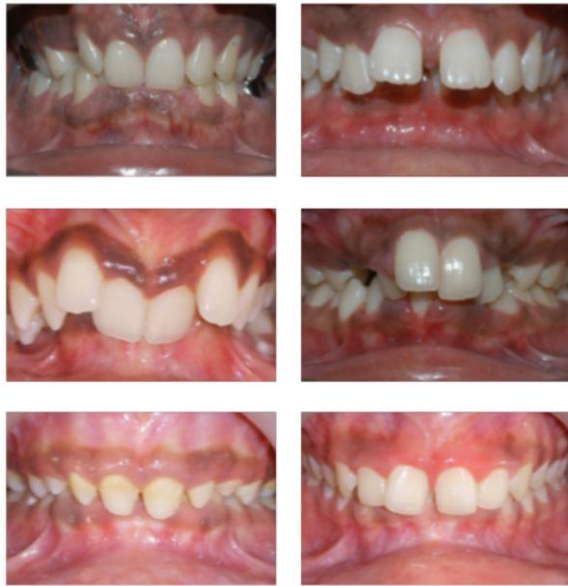

Figure 1: Photographs showing the different intraoral features of deepbite cases.

1. Dental and skeletal deep bite: Figure 1

a. Simple deep bite:

This occurs due to over-eruption of anteriors or infraocclusion of molars. There may be labial version of the upper incisors and impingement of the lower incisors into the palatal mucosa with lingual collapse of maxillary or mandibular anterior teeth.

b. Complex deep bite:

Mal-relationship of alveolar bones and underlying mandibular or maxillary bones may occur. The diminished anterior vertical height of the face is also an important criteria for diagnosis of skeletal deepbite.

2. True and pseudo-deep overbite

This is caused by infra-occlusion of the posterior segment teeth seen in class II div II and class II div I malocclusions. It is often the result of a lateral tongue thrust. The

interposition of tongue prevents the eruption of the posterior teeth.

3. Incomplete and complete deep bite

The lower incisors fail to occlude with the upper incisors. In Complete over bite, the lower incisors contact the palatal surface of the upper incisors or the palatal tissue when the teeth are in centric occlusion.

ETIOLOGY OF DEEP BITE

The etiology of deep overbite is a complex problem and may include one or more of the following;

- 1. Hereditary
- 2. Skeletal
- 3. Dental
- 4. Muscular
- 5. Habits

DIAGNOSTIC CONSIDERATIONS IN MANAGEMENT OF DEEP BITE

Before treating a deep bite, many factors should be considered which includes esthetics, occlusal plane, lip competence, the vertical skeletal dimension, convexity of the face, growth potential, and stability of occlusion.

1) Soft tissue considerations:

- a) Interlabial gap: 2 to 3 mm is normal. If it is excessive, molar extrusion should be avoided.
- b) Smile line: In case of gummy smile, intrusion of maxillary incisors should be done.
- c) Lip length: In cases of short upper lip, intrusion should be carried out.

2) Dental considerations:

Incisor intrusion is ideal to treat deep bite in cases of supraeruption and gummy smile. It maintains the vertical dimension. Upto 4 mm of incisor intrusion can be achieved.

3) Skeletal considerations:

In case of decreased lower anterior face height, extrusion of molars is acceptable but it should be attempted only in growing children. If the same is attempted in adults,

the stability of the result will be questionable. In patients with increased face height, intrusion of anteriors should be considered.

The greater the skeletal difference the more likely it is that the patient will need a combination of orthodontics and orthognathic surgery to correct the occlusion and the underlying skeletal discrepancy.

Orthodontic implications of deep-bite

Due to the excessive depth of the bite, functional problems that affect the temporal, masseter and lateral pterygoid muscles occur, and by consequence, the condyle goes backwards and upwards in the articular fossa due to the lingual eruption of the central incisors, which forces the mandible and the condyles to go backwards far away from centric relation. Therefore these patients are susceptible to TMJ pathology. [4]

CLINICAL MANAGEMENT:

Intrusion of anteriors:

Deep bite with large interlabial gap, if incisor-stomion distance is large which is often associated with a high smile line or "gummy smile", the best method of treating a deep overbite may be by intrusion of the upper incisors.

Relative intrusion:

The wire materials used for intrusion in these techniques are diverse, but all recognize the need for a light, continuous force.

A) *Reverse curve of Spee:* It mainly causes extrusion of the posterior teeth. However there may be undesirable changes in the axial inclinations of the buccal teeth and flaring of the incisors. [5]

B) *Anchor bend:* This is an intrinsic part of the Begg technique (1954). 0.016 Inch archwire with cuspid circle mesial to canine brackets, Anchor bend 30-40 degrees, 3mm mesial to molar tube generates 10-12grams of force per tooth total intrusive force of

70grams per six anterior teeth. Class11 elastics help in bite opening. [6,7] Figure 2

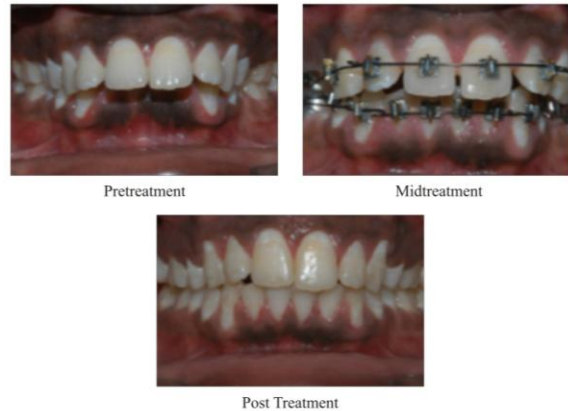


Figure 2: Deepbite case treated with Begg appliance therapy

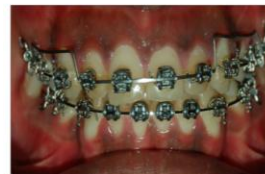

Figure 3: Utility arch Wire

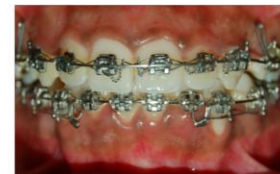

Figure 4 KSir Arch Wire

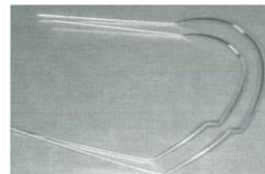


Figure 5: Maxillary and mandibular Connecticut Intrusion Arches

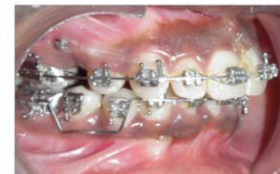

Figure 6: Micro Implants for Intrusion and Retraction

C) *Utility arches:* It was introduced in 1976. It is a continuous wire that extends across both buccal segments but engages only the first permanent molars and four incisors and is most commonly made of rectangular 0.016×0.016 inch stainless steel or 0.016×0.022 inch Elgiloy. It generates approximately 25grams of force per anterior tooth. Wire is activated by placing occlusally directed gable bend in the vestibular segment. A tip back bend also helps in intrusion of anterior teeth. It causes intrusion and possible torquing of the incisors as well as tipping back, of the molars. [8] Figure3

D) *Three Piece Intrusion Arch*.^[9] It was introduced by Burstone in 1977. It consists of a heavy stainless steel 0.019x0.025 inch or larger archwire in the anterior brackets the distal extensions of which end 2 to 3 mm distal to the centre of resistance of anterior teeth. The intrusive force is applied with 0.017x0.025inch TMA tip back springs. Distal force delivered by Class I elastic to the anterior segment is used to alter the direction of the intrusive force on the anterior segment

E) *K-SIR arch* ^[10] It was introduced by Dr. Varun Kalra and is a modification of the segmented loop mechanics of Burstone and Nanda. It is a continuous 0.019x0.025”TMA archwire with closed 7mmx2mm loops at the extraction site. Simultaneous intrusion and retraction can be achieved with this. Figure 4

F) *The Connecticut Intrusion Arch (CIA)* ^[11] is more commonly used for intrusion of the anterior teeth, but it has other uses, including molar tip back for Class II correction, for anchorage preparation of the posterior segment, correction of minor anterior open bites, occlusal plane leveling and detailing. Figure 5

Absolute Intrusion:

A) *Implants*: Implants can be used for true intrusion of anteriors or a combination of intrusion and retraction depending upon the site of implant placement and direction of force delivery. For effective intrusion the retraction hooks are soldered facing occlusally. ^[12] Figure 6

B) *J-Hook headgear*: J-Hook headgear can also be used for intrusion of the anterior segment and it produces absolute intrusion.

C) *Surgical correction*: Anterior segmental osteotomies and mandibular advancement can also correct skeletal deep bite. ^[13] Figure 7

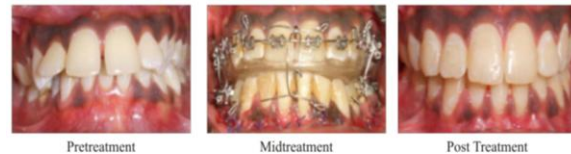

Figure 7: Surgical correction of deepbite

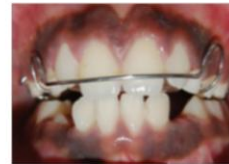

Figure 8: Anterior bite plane

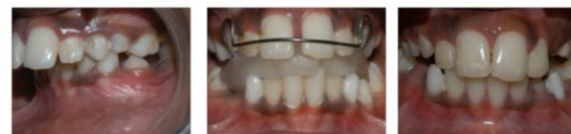

Figure 9: Case of class II division I deepbite treated with Activator.

Extrusion of Molars:

In deep bite with redundant upper or lower lips, or no interlabial gap, posterior extrusive mechanics may be desirable.

If a patient with deep overbite exhibits normal incision-stomion distance, In patients having excessive overbite with Class II, division 2 type of skeletal malocclusion and if there is adequate interocclusal space, Extrusion of posteriors is the treatment option.

Anterior biteplane: This disoccludes the posterior teeth and hence causes extrusion of posterior teeth. It can be used in growing patients. Stability of bite opening by extrusion will be questionable in adults especially those who have brachycephalic and horizontal growth pattern. Figure 8

3. Planning Treatment in different age groups:

1) *Treatment planning in primary dentition*: Anterior deep bite in the primary dentition are fairly common but are rarely treated. When an excessive overbite is seen in the primary dentition, it is likely to have a skeletal basis with the presence of developing Class II malocclusions. Activator type appliance may be used to

direct differential alveolar growth, reduce the interocclusal distance, and improve skeletal morphology. Figure 9

2) Treatment planning for mixed dentition:

The overbite is greater just after eruption of the permanent incisors and decreases with eruption of the posterior teeth. If the skeletal bases are class I with normal incisor angulation, it is better to wait and watch till the eruption of the posterior teeth which results in resolution of deep bite. In non skeletal deep bites a utility arch that incorporates molar and incisor teeth can be used during the mixed dentition to intrude, tip, or reposition both molars and incisors.

Deepbites with anterior vertical maxillary excess showing gummy smiles can be intercepted by high pull headgears. Class I skeletal deepbites with horizontal growth pattern can also be intercepted with the myofunctional appliances.

3) Treatment planning for early permanent dentition

In simple dental deep bites and when there is a normal interocclusal distance in the mandibular postural position, treatment by arch leveling mechanics alone may be possible.

In class II div I growing patients intrusion or prevention of excessive eruption of the lower incisors is achieved by leveling out an excessive curve of Spee with the continuous arch wire mechanics from molar to incisors. In the absence of growth, absolute intrusion is required and segmented arch mechanics must be used to achieve this. Eruption of the first molars can be aided by maxillary bite plane and the incisors intruded with utility archwire.

4) Treatment planning in adults

In adult patient showing excessive deep overbite of 100 per cent or more, with accompanying;

1. High smile line.
2. Decreased Vertical facial height.

3. Alveolar problems, the length of treatment may be very long. In this instance, the patient should be given a choice for an Orthognathic correction of the problem. In these patients, the treatment plan to correct the excessive overbite should be done in conjunction with an oromaxillofacial surgeon.

Maxillary surgery: The maxilla can be moved up quite successfully with Lefort I. Surgically repositioning of maxilla in superior direction can be done by complete maxillary osteotomy in case of vertical maxillary excess.

Mandibular surgery: Patients with a short face (skeletal deep bite) problem are characterized by a long mandibular ramus, square gonial angle and short nose-chin distance. They are treated most predictably and successfully by mandibular ramus surgery that allows the mandible to move downward only at the chin, increasing the mandibular plane angle. They are treated best by sagittal split mandibular ramus surgery to rotate the mandible slightly forward and down and the gonial angle open up. The deep bite in the anterior mandibular alveolar region can be corrected by subapical osteotomy.

PREVENTION

According to Wragg ^[14] recommendations to minimize periodontal trauma are:

1. Identify those cases with the potential for trauma at an early age.
Ensure careful orthodontic diagnosis and treatment.
Establish and maintain periodontal health.
Ensure all restorations have stable centric stops to maintain posterior support.
Removable prosthesis should be reviewed routinely and maintained.
Patient should be made aware of the need for regular dental checkup.

TREATMENT STABILITY:

Deep bite corrections achieved during periods of active growth have been found to be more stable than those in adult patients. The stability of deep bite correction has been a challenge to the orthodontist. In most of the cases it requires a prolonged retention protocol, which usually constitutes use of a removable appliance with a potential bite plane incorporated on to it.

CONCLUSION

The successful treatment of deep bite correction depends on, an elaborate clinical examination, thorough cephalometric analysis, and judicious treatment planning among the various available options and by using appropriate mechanotherapy followed by a proper retention protocol.

REFERENCES

1. Graber T.M. Orthodontics: Principles and Practice. 3rd Ed., W.B. Saunders, Philadelphia.
2. Mathews D, Kokich V. Managing treatment for orthodontic patient with periodontal problems. Semin Orthod 1997; 3: 21-38.
3. Parker C., Nanda R.S., Currier G.F. Skeletal and dental changes associated with the treatment of deep bite malocclusion Am. J. Orthod. 1995; 107:382-393.
4. Kokich V, Spear F. Guidelines for managing the orthodontic-restorative patient. Semin Orthod 1997; 3:3-20.
5. Nanda R., Differential Diagnosis and treatment of excessive overbite. DCNA 1981;25:61-83.
6. Nanda R. Correction of deep overbite in adults. DCNA 1997;41:67-87.
7. Begg P.R., Kesling P.C. Begg orthodontic therapy and technique, 3rd Ed.
8. Bench R.W., Gugino C.F., Hilgers J.J. The utility arches and sectional arches in Bioprogressive therapy mechanics. J Clin Orthod 1978;12(3): 192-207.
9. Shroff B., Yoon W.M., Lindauer S.J., Burstone C.J. Simultaneous intrusion and retraction using a three piece base arch. Angle Orthod 1997;67:455-461.
10. Proffit W.R., Field H.W., Ackerman J. L., Bailey L.T., Tulloch J.F.C. Contemporary Orthodontics 4th, C.V. Mosby Co; 2000
11. Kalra V., Simultaneous intrusion and retraction of the Anterior teeth. J. Clin. Orthod 1998;35(9),535-540
12. Carano A., Velo S., Incorvatic, Poggio P. Mini Screw Anchorage System in the maxillary alveolar bone. J. Ind. Orthod Soc 2004; 37:74-85
13. Bell W.H., Proffit W.R., White R.P. Surgical correction of dentofacial deformities, W.B. Saunders Co.
14. Wragg PF, Jenkins WM, Watson IB, Stirrups DR. The deep overbite: Prevention of trauma. Br Dent J 1990; 168: 364-7.

How to cite this article: Pavithra.A.S., Roopa. S. A clinical insight of deep-bite and its management. Int J Health Sci Res. 2013;3(10):121-126.
