



Case Report

Neuromuscular Hamartoma in an Adult Male Patient: A Case Report

Sushama Rajaram Desai^{***}, Deepti Vijay Mankar^{**@}, Nanda Jaywant Patil^{*}, Sunil Vitthalrao Jagtap^{*}

^{***}Professor and Head, ^{**}Post Graduate Resident, ^{*}Associate Professor
Department of Pathology, Krishna Institute of Medical Sciences, Karad, Maharashtra.

@Correspondence Email: deeptivmankar@gmail.com

Received: 24/10/2012

Revised: 28/11/2012

Accepted: 15/12/2012

ABSTRACT

Background: The neuromuscular hamartoma (syn. neuromuscular choristoma, benign triton tumour) is a rare developmental lesion composed of mature elements of striated muscle and nerve. Most earlier reports either do not list adipose tissue as a component or do not comment on its presence or absence in the lesion. To the best of our knowledge, till date, only thirty-nine cases of neuromuscular hamartoma have been reported in English literature. Some of these have involved large nerves; others report cutaneous lesions or cranial nerve involvement. A majority have been described in infants and young children and nearly all patients had associated neurological dysfunction.

Case Report: We present a rare case of a neuromuscular hamartoma with an additional adipose tissue component arising from a branch of the sciatic nerve, in a thirty-four year old male patient with no neurological deficit.

Conclusion: Although neuromuscular hamartomas in adults are very rare, they should be considered in the differential diagnosis of soft tissue tumours of the lower leg, irrespective of the presence or absence of neurological symptoms.

Keywords: Neuromuscular hamartoma, benign Triton tumour, peripheral nerve tumour

INTRODUCTION

The neuromuscular hamartoma (also referred to as the neuromuscular choristoma or benign triton tumour) is a rare developmental lesion composed of mature elements of striated muscle and nerve. [1,2] A review of literature shows that almost all earlier reports either do not list adipose tissue as a component or do not comment on the presence or absence of adipose tissue in this lesion. [3] To the best of our knowledge, till date, only thirty-nine cases of neuromuscular hamartoma have been

reported in English literature. [4] Some of these have involved large nerves, others report cutaneous lesions or cranial nerve involvement. [4] A majority of the cases have been described in infants and young children, [1,2,5,9] and nearly all patients had some neurological dysfunction. [5-10] We present a rare case of a neuromuscular hamartoma with an additional adipose tissue component arising from a branch of the sciatic nerve, in a thirty-four year old male patient with no neurological deficit.

CASE REPORT

A thirty-four year old male patient presented with a swelling over the lateral aspect of the left lower leg above the lateral malleolus. A vague history of fall from a tree, fourteen years previously was given, after which, according to the patient, the swelling developed. There was no complaint of pain, restriction of movement, paraesthesia or any other symptom associated with the swelling. The patient had

no significant past/ medical/ family/ personal history.

On local examination, a 10 x 8 x 5 cm, single, non-tender, soft to firm, mobile swelling, unattached to overlying skin was noted.

Ultrasonography (USG) with colour Doppler study of the swelling revealed an iso to mixed echoic, deeply situated, moderately vascular mass suggestive of a haemangioma.

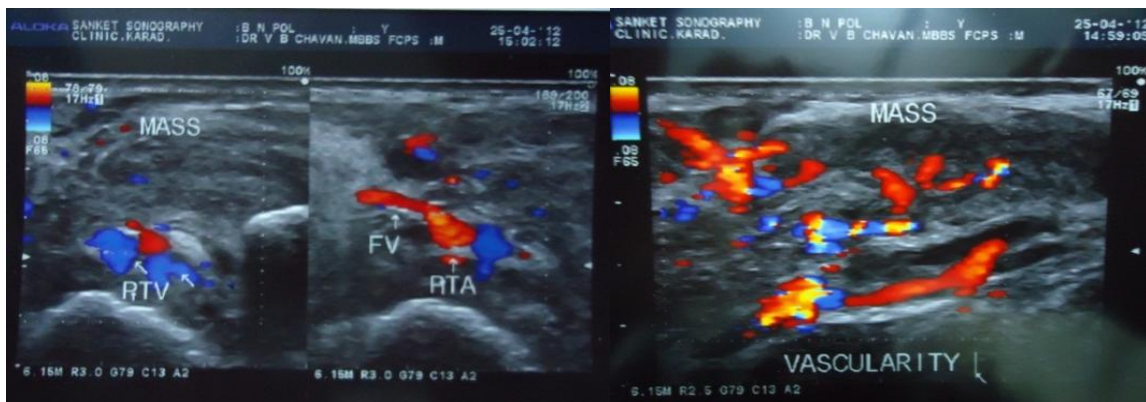


Fig. 1: USG with colour Doppler study of lesion over left ankle

A magnetic resonance imaging (MRI) study of the left ankle revealed an ill-defined lobulated lesion with sharp, irregular margins and mixed signal intensity with a few contrast enhancing areas, extending from the junction of the lower 1/3rd and upper 2/3rd of the tibia to the level of the ankle. The lateral margins of the lesion were pushing below the subcutaneous plane, medially extending into the inter-muscular plane and between the tibia and fibula. No cortical irregularity, marrow oedema, obvious infiltration, muscle or vessel abnormality was visualised. A provisional diagnosis of a liposarcoma (fibromyxoid type) was given.

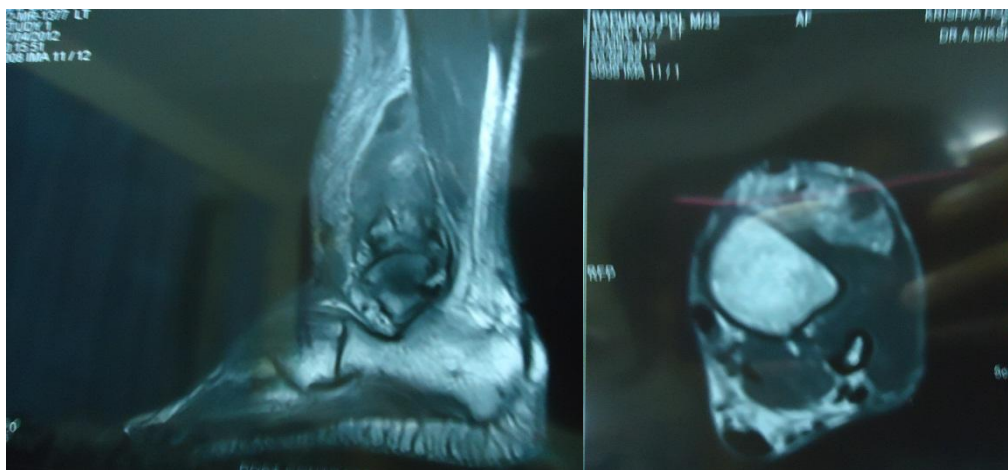

Fig. 2: MRI – Left ankle joint - Lateral and Sagittal views

Other routine investigations of the patient were unremarkable. The tumour was excised and sent for histopathological examination.

On gross examination, the tumour was composed of multiple, firm, grey-white, nodular masses, the largest of which measured 3.8 x 3 x 2 cm. On cut section, individual nodules were grey-white and subdivided by collagenous connective tissue into smaller nodules.

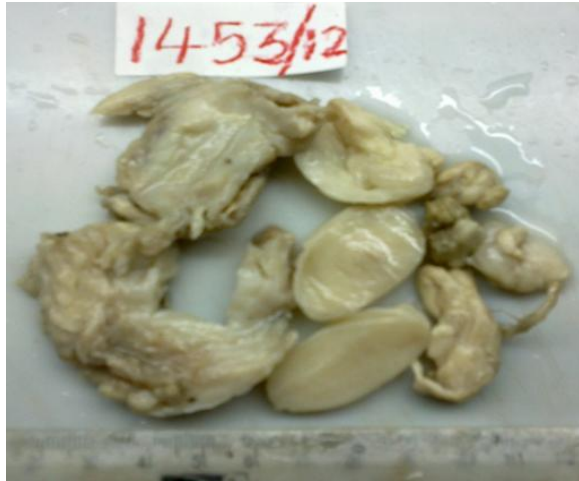

Fig. 3: Gross Specimen

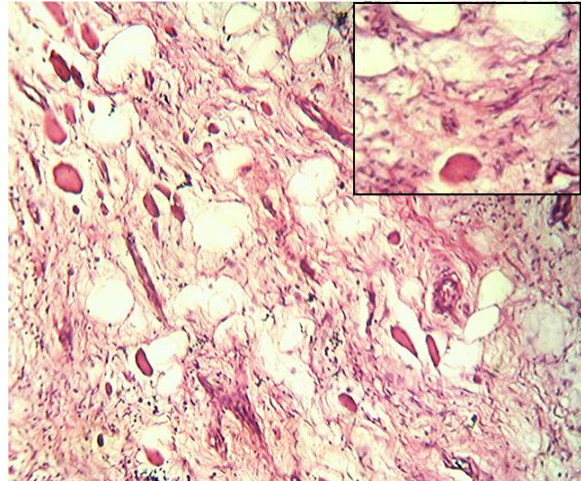


Fig.4: Photomicrograph showing mature skeletal muscle fibres admixed with nervous and adipose tissue elements (100x, H&E stain). [Inset - A single skeletal muscle fibre in the midst of nervous and adipose tissue. (400x, H&E stain)].

Microscopy revealed a tumour composed of short bundles of mature nerve fibres admixed with adipose tissue along with well-developed striated muscle fibres. No cytologic atypia or mitoses were present. Dense fibrous investment of the nodules and fascicles was seen and the vascular pattern was unremarkable. These microscopic findings were diagnostic of neuromuscular hamartoma.

On immunohistochemical staining, the skeletal muscle fibres and nerve tissue were strongly positive for myoglobin and S-100 respectively. Adipose tissue was also stained positively by S-100, to a lesser intensity than the nerves.

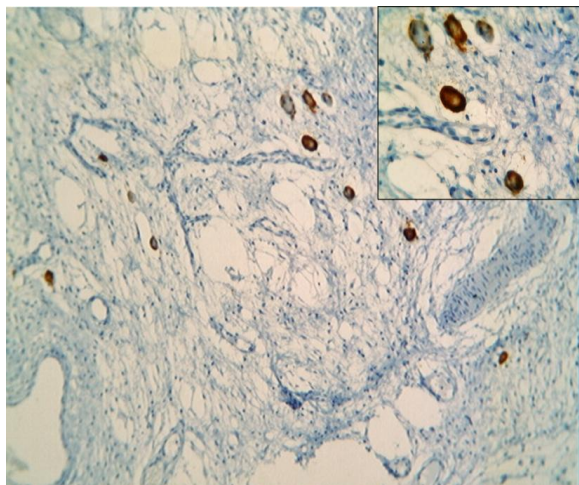


Fig. 5: Photomicrograph showing skeletal muscle fibres staining strongly positive for myoglobin (100x). [Inset - (400x)].

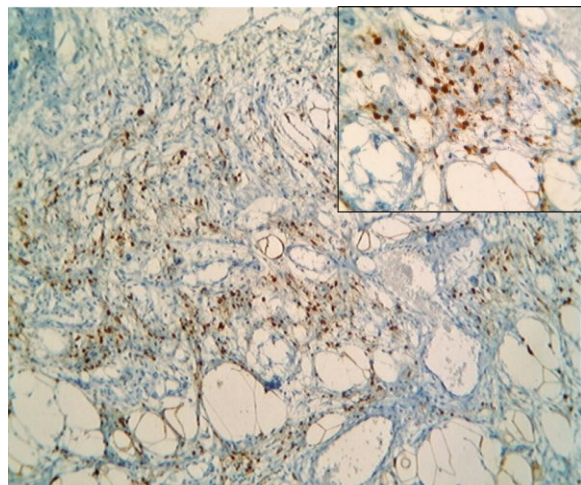


Fig. 6: Photomicrograph showing nervous and adipose tissue staining positive for S-100 protein (100x). [Inset - (400x)].

DISCUSSION

Hamartomas are defined as benign tumour-like nodules composed of an overgrowth of disorganised mature cells and tissues, often with one element predominating.

The neuromuscular hamartoma is a rare peripheral nerve lesion in which mature skeletal muscle fibres lie within the nerve and its fascicles. [2] It is synonymous with benign "triton" tumour and neuromuscular choristoma. [1,2] It usually occurs in infants and young children. [1,2]

The first reported case of neuromuscular hamartoma, published in 1895, involved the sciatic nerve. [4] In earlier case reports, neuromuscular hamartomas were generally associated with a large peripheral nerve, such as the brachial plexus (25%) [6,7] or sciatic nerve (15%). [8,9] Cranial nerve involvement, including that of the trigeminal, [10] facial, oculomotor, cochlear, occipital and optic nerves, was subsequently reported in 18 cases (45%). [4] Cutaneous lesions have been reported in four cases. [4,11]

This case is unique in that the patient was an adult when he reportedly developed the tumour in association with a branch of the sciatic nerve.

Histologically, the tumour consists of mature skeletal muscle fibres sharing the same perimyoseal sheath with both small myelinated and non-myelinated nerve fibres. [2]

A review of literature shows that almost all earlier reports either do not list adipose tissue as a component of the neuromuscular hamartoma or do not comment on the presence or absence of adipose tissue in this lesion. [3]

A variety of lesions including neuromesenchymal hamartoma, ectomesenchymal hamartoma and rhabdomyomatous hamartoma can be

included in the differential diagnosis of this tumour. [12,13,14]

Salaz et al in 1990, described a stricturous lesion in the small bowel composed of smooth muscle bundles, peripheral nerve tracts, vessels, ganglia and adipose tissue, and proposed that neuromuscular hamartomas with an additional mesenchymal (eg. adipose) tissue component be called as neuromesenchymal hamartomas. [12]

Later, Apostolides et al reported a previously undescribed hamartoma of the VIIIth nerve, consisting of adipose tissue, myelinated nerve, well-differentiated smooth and skeletal muscle, and rare ganglion cells, which they labelled "ectomesenchymal" hamartoma. [13] Also described is the rhabdomyomatous mesenchymal hamartoma, a rare congenital lesion of the dermis and soft tissues consisting of a disordered collection of adipose tissue, skeletal muscle, adnexal elements and nerve bundles. [14]

The tumour we report has a unique histological combination of skeletal muscle fibres in close association with neural tissue and abundant adipose tissue. Its site of origin and lack of smooth muscle fibres and prominent vasculature serve to differentiate it from the neuromesenchymal hamartoma. [12] The lack of smooth muscle and ganglion cells also separates it histologically from the ectomesenchymal hamartoma, [13] while the late presentation along with absence of adnexal structures distinguishes it from the rhabdomyomatous mesenchymal hamartoma. [14]

We have, therefore, classified this tumour under the broad category of neuromuscular hamartomas. Histogenesis of these tumours is unclear. It is theorised that they may be derived from neuroectodermal or limb mesenchymal tissue proliferation in a peripheral nerve or incorporation of

mesenchymal tissue into nerve sheaths during embryogenesis. [5,10]

In literature, affected patients typically presented with a long-standing sensorimotor nerve deficit, including numbness and paralysis of the involved extremity. [5-10] Cutaneous lesions are not associated with neurological deficit. [4,11]

This case is also unique in that the patient had no associated neurological symptoms at presentation. Often, total excision of neuromuscular hamartoma is not possible because of its close association with a major nerve. Therefore, only partial excision or biopsy can be performed in many cases. [2] Even an incomplete excision has resulted in symptomatic relief and tumour regression. Treatment should be conservative and aimed at preserving nerve integrity. [2]

CONCLUSION

We present this case of the rare entity of a neuromuscular hamartoma with an additional adipose tissue component, arising in association with a branch of the sciatic nerve in an adult patient with no neurodeficit.

Although neuromuscular hamartomas in adults are very rare they should be considered in the differential diagnosis of soft tissue tumours of the lower leg, irrespective of the presence or absence of neurological symptoms.

REFERENCES

1. Prayson RA. Muscle and peripheral nerve pathology. In: Silverberg SG, DeLellis RA, LiVolsi VA, Frable WJ Wick MA, editors: 'Silverberg's principles and practice of surgical pathology and cytopathology', Vol.2. 5th ed. New York: Churchill Livingstone-Elsevier. 2006; p. 224
2. Weiss SW, Goldblum JB. Benign tumours of peripheral nerves. In:

- 'Enzinger and Weiss's Soft tissue tumours', 4th ed. St. Louis: Mosby. 2001; p. 1122-3.
3. Burger PC, Scheithauer BW. Tumours of the central nervous system. In: Silverberg SG, Sobin LH, editors. 'AFIP Atlas of Tumour Pathology', Fourth Series, Fascicle 7. Washington DC: ARI, Armed Forces Institute of Pathology. 2007; p. 446-7.
4. Shih IH, Wang JR, Chang CH, Yang CH. Cutaneous neuromuscular choristoma: Case report and review of the literature. *Dermatologica Sinica* 2012; 30: 29-32.
5. Louhimo I, Rapola J. Intraneural muscular hamartoma: report of two cases in small children. *J Pediatr Surg* 1972; 7: 696-9.
6. Awasthi D, Kline DG, Beckman EN. Neuromuscular hamartoma (benign "Triton" tumour) of the brachial plexus. *J Neurosurg* 1991; 75: 795-7.
7. Lai PH, Ho JT, Lin SL, et al. Neuromuscular hamartoma arising in the brachial plexus. *Neuroradiology* 2004; 46: 216-8.
8. Maher CO, Spinner RJ, Giannini C, et al. Neuromuscular choristoma of the sciatic nerve. Case report. *J Neurosurg* 2002; 96: 1123-6.
9. Markel SF, Enzinger FM. Neuromuscular hamartoma - benign "Triton tumour" composed of mature neural and striated muscle elements. *Cancer* 1982; 49: 140-4.
10. Vajramani G, Devi I, Santosh V, Hegde T, Das BS, Das S, Shankar SK. Benign triton tumor of the trigeminal nerve. *Childs Nerv Syst.* 1999 Mar; 15(2-3): 140-4.
11. O'Connell JX, Rosenberg AE. Multiple cutaneous neuromuscular choristomas. Report of a case and a

- review of the literature. Am J Surg Pathol 1990; 14: 93-6.
12. Salas A, Casellas F, Sanz J, Garcia F, Margarit C, Malagelada JR. Neuromesenchymal hamartoma of the small bowel. J Clin Gastroenterol. 1990 Dec; 12(6): 705-9.
13. Apostolides PJ, Spetzler RF, Johnson PC. Ectomesenchymal hamartoma (benign "ectomesenchymoma") of the VIIIth nerve: case report. Neurosurgery. 1995 Dec; 37(6): 1204-7.
14. Rosenberg AS, Kirk J, Morgan MB. Rhabdomyomatous mesenchymal hamartoma: an unusual dermal entity with a report of two cases and a review of the literature. J Cutan Pathol. 2002 Apr; 29(4): 238-43.

How to cite this article: Desai SR, Mankar DV, Patil NJ et. al. Neuromuscular hamartoma in an adult male patient: a case report. Int J Health Sci Res. 2012;2(9):87-92.
