



Case Report

Cadaveric Case Report on Variant Heads of Plantaris Muscle

Sharadkumar Pralhad Sawant ^{**@}, Shaguphta T. Shaikh ^{*}, Rakhi M. More ^{*}

^{**} Associate Professor, ^{*} Assistant Professor

Department of Anatomy, K. J. Somaiya Medical College, Somaiya Ayurvihar, Sion, Mumbai-400 022

[@]Correspondence Email: dr.sharadsawant@yahoo.com

Received: 03/10/2012

Revised: 15/11/2012

Accepted: 16/11/2012

ABSTRACT

During routine dissection for undergraduate medical students, we observed two separate heads of plantaris muscle on left lower limbs of a 80 years old donated embalmed male cadaver in the Department of Anatomy, K. J. Somaiya Medical College, Sion, Mumbai, India. Both the heads of the plantaris muscle were composed of a thick muscle belly and a long thin tendon. One head of the plantaris muscle originated from the lower part of the lateral supracondylar line of the femur superior to the origin of the lateral head of gastrocnemius while the other head of the plantaris muscle originated from the oblique popliteal ligament. The tendons of both the heads of the plantaris muscle ran downwards inferomedially posterior to the knee joint. Both the tendons united to form common tendon and ran along the medial side of the tendo calcaneus. The common tendon of both the heads of the plantaris muscle got inserted separately into the medial side of the calcaneus bone. The photographs of the variations were taken for proper documentation and for ready reference. The variations of plantaris muscle are very rare and not found in literature. The plantaris muscle is vestigial in human beings and has much clinical importance. The plantaris muscle is absent in 7–10% of the human population. Injury of the plantaris muscle causes the painful calf. It may occur at the myotendinous junction with or without an associated hematoma and partial tear of the soleus or the medial head of the gastrocnemius muscle. Injuries of the plantaris muscle and tendon is called as ‘tennis leg’. The long, thin tendon of the plantaris is humorously called ‘the freshman's nerve’, as it is often mistaken for a nerve by first-year medical students. Knowledge of anatomical variations of the plantaris muscle is important for physiotherapists, plastic surgeons performing tendon transfer operations, clinicians diagnosing muscle tears and radiologists interpreting MRI scans.

Key words: Plantaris Muscle, Tendo Calcaneus, Vestigial, Tennis Leg, Freshman's Nerve, Radiologists, Plastic Surgeons, Tendon Transfer.

INTRODUCTION

The plantaris become vestigial as the foot is evolved for long-distance walking and running. The muscle was useful to other primates for grasping with their feet. The plantaris muscle is considered to be a

flexor group muscle of the leg. The muscle originates from the lower part of the lateral supracondylar line of the femur and the oblique popliteal ligament. ⁽¹⁾ The muscle belly is fusiform in shape passes inferomedially posterior to the knee joint

and ends as a long slender tendon. It gets inserted into the tendo calcaneus or occasionally separately inserting into the medial side of the calcaneus bone. It is innervated by the tibial nerve (S1, S2). Plantaris acts as a weak plantarflexor the ankle joint and flexor of the knee joint. Plantaris may also provide proprioceptive feedback information to the central nervous system regarding the position of the foot. ⁽²⁾ The muscle is also reported to merge with the flexor retinaculum or with the superficial fascia of the leg. Standard text books mentions the fact that the muscle may be absent in 10 % cases. ⁽¹⁾ The tendon of plantaris muscle serves as an excellent graft. The anatomical knowledge of plantaris muscle is also important for clinical diagnosis of the muscle rupture and interpreting MRI scans. Plantaris is one of the vestigial muscle and often mistaken for a nerve by new medical students and thus called the "freshman nerve". Its motor function is so minimal that its long tendon can readily be harvested for reconstruction elsewhere with little functional deficit. The plantaris is mainly used by surgeons for tendon grafts needed in other areas of the body. Although the plantaris does have little importance, there are injuries that can occur. It can be damaged in an Achilles tendon rupture. Tennis leg is a commonly known injury. It is a result of eccentric loading placed on the ankle while the knee is extended, and occurs while running or jumping. It may cause a direct trauma to the calf area. Pain and swelling are common in the injury. It is sometimes removed to treat its inflammation. ^(3,4) The plantaris is located deep to the lateral head of the gastrocnemius muscle and superficial to the popliteus muscle in the popliteal fossa. ⁽²⁾ Palpation of the muscle belly is possible in the popliteal fossa as well as along the medial aspect of the common tendon of the triceps surae group. With the patient prone and the leg

flexed to approximately 90 degrees, the distal hand of the practitioner covers the heel while the forearm is applied against the plantar aspect of the foot, allowing a simultaneous resistance to plantarflexion of the foot and flexion of the knee. The muscle is palpated in the popliteal fossa, medial and superior to the lateral head of the gastrocnemius muscle. Its tendinous portion can be palpated along the medial aspect of the Achilles tendon into its calcaneal insertion. ⁽⁵⁾

CASE REPORT

During routine dissection for undergraduate medical students, we observed two separate heads of plantaris muscle on left lower limbs of a 80 years old donated embalmed male cadaver in the Department of Anatomy, K. J. Somaiya Medical College, Sion, Mumbai, India. Both the heads of the plantaris muscle were composed of a thick muscle belly and a long thin tendon. One head of the plantaris muscle originated from the lower part of the lateral supracondylar line of the femur superior to the origin of the lateral head of gastrocnemius while the other head of the plantaris muscle originated from the oblique popliteal ligament. The tendons of both the heads of the plantaris muscle ran downwards inferomedially posterior to the knee joint. Both the tendons united to form common tendon and ran along the medial side of the tendo calcaneus. The common tendon of both the heads of the plantaris muscle got inserted separately into the medial side of the calcaneus bone. Both the heads of the plantaris muscle crossed the tibial nerve as it descended between the gastrocnemius and the soleus muscles. The popliteal artery was found to lie medial to both the heads. The nerve supply to the inner belly was from a separate branch from nerve to lateral head of the gastrocnemius muscle. The nerve supply to the outer belly was in common with the

nerve to the lateral head of gastrocnemius muscle. The photographs of the variations were taken for proper documentation and for ready reference. No other neuro-vascular variation was observed in the same lower limb. The right lower limb of the same cadaver was also normal.

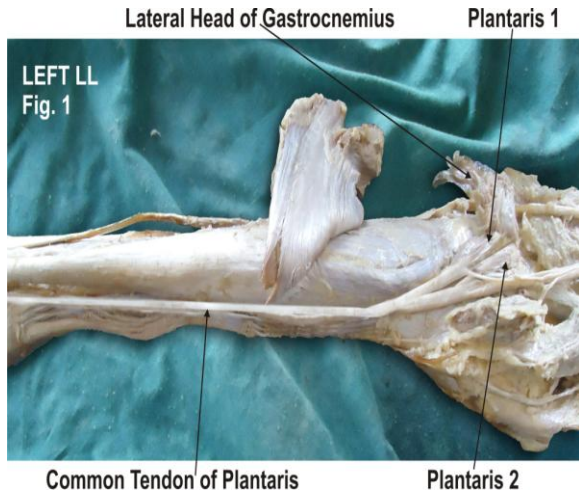


Figure - 1: Photographic presentation of both the heads of the plantaris muscle. One head of the plantaris muscle originated from the lower part of the lateral supracondylar line of the femur while the other head originated from the oblique popliteal ligament. The common tendon of both the heads of the plantaris muscle got inserted separately into the medial side of the calcaneus bone.

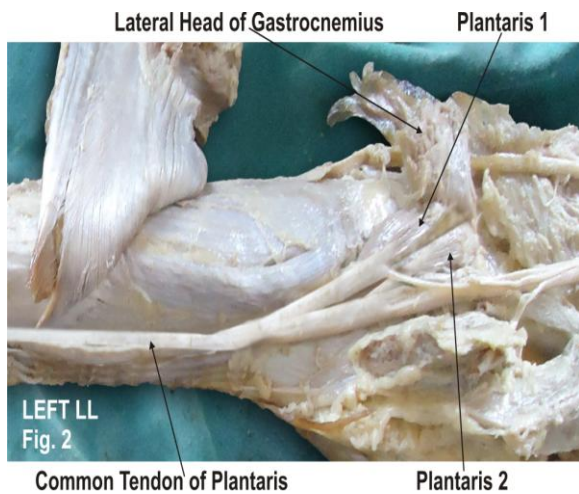


Figure - 2: Photographic presentation of the nerve supply to both the heads of the plantaris muscle by the tibial nerve.

DISCUSSION

In 1893, Robert Wiedersheim published a book on human anatomy and its relevance to man's evolutionary history. This book contained a list of 86 human organs that he considered vestigial, or as Wiedersheim himself explained that the organs having become wholly or in part functionless, some appearing in the embryo alone, others present during life constantly or inconstantly. For the greater part organs which may be rightly termed Vestigial. ⁽⁶⁾ A number of muscles in the human body are thought to be vestigial, either by virtue of being greatly reduced in size compared to homologous muscles in other species, by having become principally tendonous, or by being highly variable in their frequency within or between populations. The plantaris muscle is known to exhibit variations. Standard textbook of anatomy has reported the fact, that the muscle may be sometimes absent or it may be double. ⁽¹⁾ It has been considered that the plantaris muscle was earlier attached to the plantar aponeurosis of the foot but with normal evolutionary process of erect posture, the insertion of the muscle got shifted to a higher position. ⁽⁷⁾ In some animals like the American bear, the plantaris muscle can be found to be attached to the plantar aponeurosis. ⁽⁷⁾ The fusiform belly of the muscle has a long slender tendon which may be mistaken as a nerve. Often, the tendon of the plantaris muscle fuses superficially with the fascia of the leg, thereby making it vulnerable to injury. Topographical anatomy of the plantaris muscle is important for any surgery. Prior knowledge of superficial position of the tendon and its resemblance to a nerve should be borne in mind by any surgeon operating on the back of leg. Despite its small size, injuries of the plantaris muscle and tendon, which have been termed "tennis leg," have been a source of controversy in the literature. ⁽⁸⁻¹²⁾ Tennis leg is a relatively

common clinical condition. ⁽¹³⁾ In the past it has been described as being caused by various etiologies including plantaris tears, medial head of gastrocnemius tears, soleus tears, or a combination thereof. The injury occurs most frequently during running or jumping and usually results from an eccentric load placed across the ankle with the knee in an extended position. Even though the injury is the result of an indirect mechanism, subjectively the patient may describe direct trauma to the calf region – often the athlete feels as though they were struck on the calf by an object such as a ball or piece of equipment. ⁽³⁾ Depending on the severity, calf soreness may be experienced that may cause the athlete to stop play, or may simply be experienced throughout the remainder of the activity. This pain usually becomes more severe after resting or the next day. ⁽¹⁴⁾ Accompanying the pain may be swelling that may extend down to the ankle and foot. Any attempt at active or passive dorsiflexion, and resisted plantarflexion with elicit severe pain. ^(3,14) The plantaris muscle may be injured during any tear and proper diagnosis may be made only after obtaining a magnetic resonance imaging scan or ultrasonography. The tendinous injury of the plantaris muscle is important since it is associated with hemorrhage and edema. ⁽¹⁵⁾ The rupture of the tendon of the plantaris muscle is often difficult to diagnose and an important finding is the presence of a tense mass between the gastrocnemius and the soleus muscle. ⁽¹⁶⁾ The plantaris muscle has been used as an excellent graft. ⁽¹⁷⁾ Studies have described anatomical procedure of using a free plantaris tendon graft for reconstruction of the anterior talofibular and calcaneofibular ligaments. ⁽¹⁸⁾ In the presence of other flexors like gastrocnemius and soleus muscles, the removal of plantaris muscle may not have an effect on the normal limb function. The tendon of the plantaris muscle is considered as an extremely tensile

structure and has been used successfully for flexor tendon replacement in hand and even for atrioventricular valve repair. ⁽¹⁹⁾ Considering the above facts, the existence and importance of the plantaris muscle cannot be undermined. It has now been established through the use of magnetic resonance imaging, sonography, and surgical exploration, that injuries to this muscle may in fact occur in isolation, ^(13,20,21,22) as well as in association with tears of the gastrocnemius, soleus, and Anterior Cruciate Ligament. ⁽²⁰⁾ Magnetic resonance imaging and ultrasonography have been used as the primary imaging techniques for evaluation of patients with the clinical diagnosis of non-specific posterior lower leg pain. The importance of imaging patients with this condition is to rule out more serious conditions such as deep venous thrombosis. ^(3,13) In addition, imaging can be used to evaluate the location and extent of the muscle injury; however, treatment of this injury does not depend on these findings. ⁽³⁾ The appearance of plantaris muscle injury on magnetic resonance images depends on the severity of the muscle strain. The treatment routine included pain relief through the use of cryotherapy and passive stretching, followed by a 5-min period of ultrasound therapy. Treatment then progressed to strengthening exercises for the antagonists and later the agonists, and quadriceps exercises. Treatment of muscle injury in the acute phase should include preventing further damage, controlling the inflammatory cascade, limiting pain in order to promote early mobilization. Later, proper repair and regeneration of both muscle tissue, and its connective tissue components become the focus of treatment, as excessive fibrosis scar-tissue formation is one of the major factors that can slow muscle healing. ⁽²³⁾ The immediate treatment of muscle injury involves the RICE (rest, ice, compression, elevation) protocol. The

position of immobilization is also an important factor that can influence healing.⁽⁴⁾

Clinical Significance:

Injury of the plantaris muscle causes the painful calf. It may occur at the myotendinous junction with or without an associated hematoma and partial tear of the soleus or the medial head of the gastrocnemius muscle. Injuries of the plantaris muscle and tendon is called as 'tennis leg'. The long, thin tendon of the plantaris is humorously called 'the freshman's nerve', as it is often mistaken for a nerve by first-year medical students.

CONCLUSION

The presence of double plantaris muscle as seen in the present case may be of academic interest as the standard text book of anatomy mentions less about this fact. It may also be of surgical interest to surgeons and clinical interest to clinicians diagnosing muscle tears in the leg. The existence double plantaris muscle is an interesting finding, which could be important for anatomists, anthropologists, physiotherapists, surgeons and orthopedic surgeons.

Competing Interests:

The authors declare that they have no competing interest.

Authors' contributions:

SPS wrote the case report, performed the literature review & obtained the photograph for the study. RMM performed the literature search and assisted with writing the paper. STS conceived the study and helped to draft the manuscript. All authors have read and approved the final version manuscript.

ACKNOWLEDGEMENT

All the authors wish to convey our sincere thanks to Dr. Arif A. Faruqi for his

valuable help, support and inspiration. Authors also acknowledge the immense help received from the scholars whose articles are cited and included in references of this manuscript. The authors are also grateful to authors / editors / publishers of all those articles, journals and books from where the literature for this article has been reviewed and discussed.

REFERENCES

1. Standring Susan. Gray's Anatomy. The Anatomical Basis of Clinical Practice. 39th ed. Elsevier Churchill Livingstone, Philadelphia, 2005. pp. 1499-500.
2. Moore, Keith L; & Dalley Arthur R (2008). Clinically Oriented Anatomy (6th ed.). Lippincott Williams and Wilkins. ISBN 978-1-60547-652-660.
3. Toulipoulos S, Hershmann EB. Lower Leg Pain: Diagnosis and Treatment of Compartment Syndrome and other Pain Syndromes of the Leg. Sports Med. 1999;27(3):193–204. [PubMed]
4. Best TM, Hunter KD. Muscle Injury and Repair. Phys Med and Rehab Clin of N Am. 2000;11(2):251–265.
5. Tixa S. Atlas of Palpatory Anatomy of Limbs and Trunk. Teterboro, NJ: Icon Learning System Inc.; 2003. p. 333.
6. Wiedersheim, Robert (1893). The Structure of Man: an index to his past history. London: Macmillan and Co
7. Daseler, E. H. & Anson, B. J. The plantaris muscle. J. Bone. Joint. Surg., 25:822-7, 1943.
8. Platt H. Observations on some tendon ruptures. Br Med J. 1931;1:611–615. [PMC free article] [PubMed]

9. Arner O, Lindholm A. What is tennis leg? *Acta Chir Scand.* 1958;116:73–77. [PubMed]
10. Miller WA. Rupture of the musculotendinous juncture of the medial head of the gastrocnemius muscle. *Am J Sport Med.* 1977;5(5):191–193.
11. Severance HJ, Basset FH. Rupture of the plantaris: does it exist? *J Bone Joint Surg [Am]* 1983;65:1387–1388.
12. Mennen U. Rupture of the plantaris: does it exist? (letter) *J Bone Joint Surg [Am]* 1983;65:1030.
13. Delgado GJ, Chung CB, Lektrakul N, Azocar P, Botte MJ, Coria D, Bosch E, Resnick D. Tennis Leg: Clinical US Study of 141 Patients and Anatomic Investigation of Four Cadavers with MR Imaging and US. *Radiology.* 2002;224:112–119. [PubMed]
14. Gecha SR, Torg E. Knee Injuries in Tennis. *Clin in Sports Med.* 1988;7(2):435–437. [PubMed]
15. Deutsch, A. L. & Mink, J. H. Magnetic resonance imaging of musculoskeletal injuries. *Radiol. Clin. North. Am.,* 27:983-1002, 1989.
16. Allard, J.C: Bancroft, J & Porter, G. Imaging of plantaris muscle rupture. *Clin. Imag.,* 16: 55-8, 1992.
17. Simpson, S. L. ; Hertzog, M. S. & Barja, R. H. The plantaris tendon graft: an ultrasound study. *J. Hand Surg. [Am].* 1991, 16:708-711.
18. Pagenstert, G. I. ; Valderrabano, V. & Hintermann, B. Lateral ankle ligament reconstruction with free plantaris tendon graft. *Techniques in Foot & Ankle Surgery.* 4:104- 12, 2005.
19. Shuhaiber, J. H. & Shuhaiber, H. H. Plantaris tendon graft for atrioventricular valve repair. A novel hypothetical technique. *Tex. Heart. Inst. J.,* 30:42-4, 2003.
20. Helms CA, Fritz RC, Garvin GJ. Plantaris Muscle injury: Evaluation with MR Imaging. *Radiology.* 1995;195:201–203. [PubMed]
21. Allard JC, Bancroft J, Porter G. Imaging of plantaris muscle rupture. *Clin Imaging.* 1992;16:55–58. [PubMed]
22. Hamilton W, Klostermeier T, Lim EV, Moulton JS. Surgically Documented Rupture of the Plantaris Muscle: A Case Report and Literature Review. *Foot & Ankle International.* 1997;18(8):522–523. [PubMed]
23. Li Y, Fu FH, Huard J. Cutting-Edge Muscle Recovery: Using Antifibrosis Agents to Improve Healing. *Phys and Sports Med.* 2005;33(5):44–50.

How to cite this article: Sawant SP, Shaikh ST, More RM. Cadaveric case report on variant heads of plantaris muscle. *Int J Health Sci Res.* 2012;2(8):117-122.
