



Case Report

Lymphangioma Circumsriptum - A Case Report

Rajendra A. Chaudhari^{*@}, Suresh V. Mahajan^{**}, Harshal A. Patil^{***}, Naresh R. Mundhada^{*}

^{*}Assistant Professor, ^{**}Professor and Head, ^{***}Senior Resident
Department of Pathology, Dr. Vasant Rao Pawar Medical College, Adgaon, Nashik

[@]Correspondence Email: drrajchaudhari@yahoo.co.in

Received: 25/07/2012

Revised: 22/08/2012

Accepted: 30/08/2012

ABSTRACT

Lymphangioma Circumsriptum (LC) is a predominantly developmental malformation of infancy. A typical lesion consists of collections of numerous vesicles containing clear fluid & less commonly blood. Histopathology shows dilated lymphatics in the superficial and papillary dermis. We report a case of 3 years old female having a large lesion of lymphangioma circumsriptum, present since birth.

Key Words: Lymphangioma Circumsriptum, Dilated lymphatics, Benign disorder.

INTRODUCTION

Lymphangioma Circumsriptum is a developmental malformation of infancy with an equal gender incidence, but it may arise at any age. Proximal portions of limbs and limb girdle are most frequently affected. ⁽¹⁾ It is characterised by clusters of thin walled vesicles on the surface of skin like frog spawn. These vesicles are filled with either clear fluid or blood tinged fluid. ⁽²⁾ Lymphangioma Circumsriptum may resemble a number of disorders including herpes zoster, viral warts & molluscum

contagiosum. ⁽³⁾ Surgical excision is the mainstay of treatment, though recurrence is common. ⁽⁴⁾

CASE REPORT

A 3 years old girl came with a single, ill defined, hypertrophic, hyperpigmented lesion over left leg. The lesion was 4 × 3 cm in size and it was present since birth. It increased in size later on and was associated with bleeding. The clinical diagnosis was 1) ? Lymphangioma Circumsriptum and 2) ? Molluscum Contagiosum.

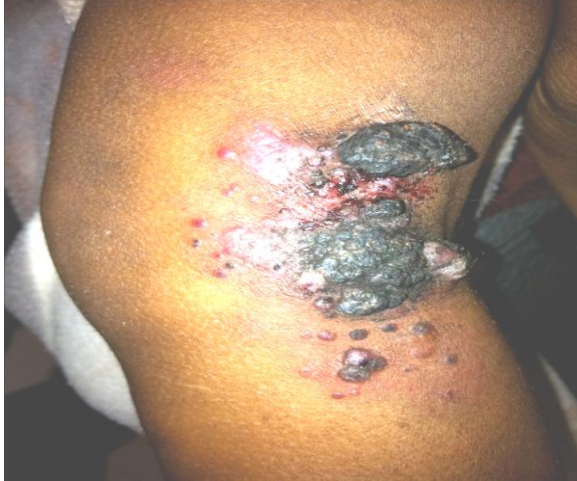

Figure 1: Hyperpigmented lesion over left leg

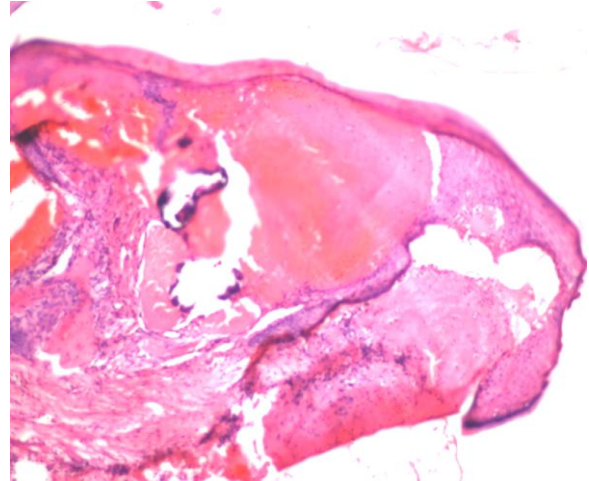


Figure 2: H & E section showing dilated lymphatic channels in the dermis

Histopathology examination showed mild acanthosis and hyperkeratosis of epidermis. Superficial dermis showed dilated lymphatics channels containing clear fluid in their lumina. The diagnosis given was “Lymphangioma Circumscriptum”.

DISCUSSION

The lymphangioma of skin and subcutaneous tissue is uncommon. In lymphangioma circumscriptum, there is dilated muscle coated lymphatic cistern in the subcutaneous plane, communicating with large dermal lymphatics upwards and finally erupting as superficial vesicles on the surface of skin as blow out phenomenon. ⁽⁵⁾

In 1970, Peachey et al ⁽⁶⁾ divided Lymphangioma Circumscriptum into two main groups; classic and localized. The classic form of LC is typically seen at or soon after birth, is often larger than 1 cm² and usually covers the proximal limbs. Conversely, the localized form is seen at any age is often less than 1 cm², and may appear anywhere on the body. ⁽⁶⁾

Surgical excision is the mainstay of treatment, despite chances of recurrence. ⁽⁷⁾

The prognosis is excellent as it is a non-neoplastic condition. However, squamous

cell carcinoma has been reported in an existing LC. ⁽⁸⁾

CONCLUSION

Lymphangioma of skin and subcutaneous tissue is uncommon. Our patient had a larger lesion of Lymphangioma Circumscriptum present since birth. Surgical excision was sufficient in this case.

REFERENCES

1. Elder DE, Elenitsas R, Johnson BL, Murphy GF. Lever's Histopathology of skin. 9th ed. Philadelphia: Lippincott Williams & Wilkins; 2005. Chapter 33, Vascular Tumors: Tumors and Tumor like conditions of the blood vessels & lymphatics; p.1015-1060.
2. Thomas PH. Vascular tumour and Malformation. In: A color guide to Diagnosis and therapy – Clinical Dermatology. 4th edition. Philadelphia. Mosby, 2004; 82-5.
3. Janniger C, Droano A, Zoster E – Medicine [Internet]. 2009 Sep 29 [cited 2009 Dec 9]. Available from : <http://emedicine.medscape.com/article/909908-overview>.

4. Bond J, Basheer MH, Gordon D. Lymphangioma circumscriptum: pitfalls and problems in definitive management. *Dermatol Surg.* 2008;34:271-5.
5. Anees A, Yaseen M, Sherwani R, Khan MA. Extensive Lymphangioma Circumscriptum. *JACM.* 2006;7(1):55-7
6. Peachey RD, Lim CC, Whimster IW. Lymphangioma of skin. A review of 65 cases. *Br J Dermatol.* 1970;83:519-27.
7. Whimster IW. The pathology of lymphangioma circumscriptum. *Br J Dermatol* 1976;94:473-86
8. Wilson GR, Cox NH, Mclean NR et al. Squamous cell carcinoma arising within congenital lymphangioma circumscriptum. *Br J Dermatol* 1993;129:337-9.

How to cite this article: Chaudhari RA, Mahajan SV, Patil HA et. al. Lymphangioma Circumscriptum - A Case Report. *Int J Health Sci Res.* 2012;2(7):102-104.
