

*Case Report***Indian Childhood Cirrhosis - A Case Report**

Suresh V Mahajan<sup>1\*\*\*</sup>, Rajendra A Chaudhari<sup>1\*\*@</sup>, Abhishek R Wadgaonkar<sup>1\*</sup>, Vijay B Chormunge<sup>2\*\*\*</sup>

\*\*\*Professor and Head, \*\* Assistant Professor, \* Senior Resident A  
<sup>1</sup>Dept of Pathology, <sup>2</sup>Dept of Forensic Medicine  
Dr. Vasant Rao Pawar Medical College, Adgaon, Nashik

@Correspondence Email: [drrajchaudhari@yahoo.co.in](mailto:drrajchaudhari@yahoo.co.in)

Received: 23/06/2012

Revised: 05/07/2012

Accepted: 09/07/2012

**ABSTRACT**

A 5 years old male child was admitted in Dr. VPMC and RC hospital, Nashik, with the complaints of abdominal pain and fever with chills. On clinical examination, there was hepatosplenomegaly, clubbing and pallor. Liver biopsy showed features of Indian Childhood Cirrhosis (ICC) with typical creeping in fibrosis. In the modern clinical practice, presentation of Indian Childhood Cirrhosis is an unusual and rare occurrence.

**Key Words:** Indian Childhood Cirrhosis, Hepatosplenomegaly, Copper, Ceruloplasmin

**INTRODUCTION**

Indian Childhood Cirrhosis is an unusual condition found only in India. [1] It was described as 'a disease which grows worse in spite of all treatment eventually terminating in the death of the patient'. [2] The disease is typical of young children (12 to 36 months of age) with hepatomegaly and even greater splenomegaly and death within 3 to 33 months. [3] A common killer disease in the past, Indian Childhood Cirrhosis (ICC) which became preventable and treatable in the early 1990s is now rare. [4]

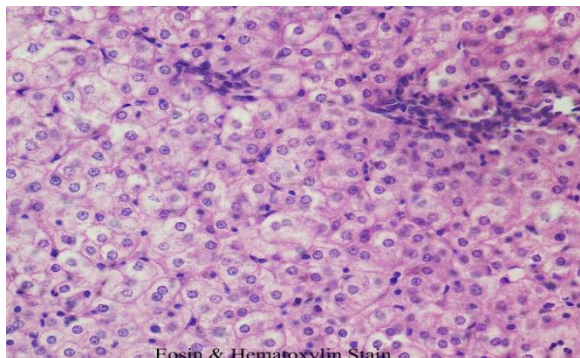
**CASE REPORT**

A 5 years old male child presented to OPD with fever and chills for last 7 – 8 days. The child also had complaints of pain in left hypochondriac region with decreased appetite. On examination, there was pallor, clubbing and the flag sign was positive. Spleen was 6 cm palpable.

Lab investigations showed pancytopenia. Ultrasonography revealed moderate splenomegaly. Doppler studies showed periportal fibrosis with portal cavernous malformation. 'Kayser –

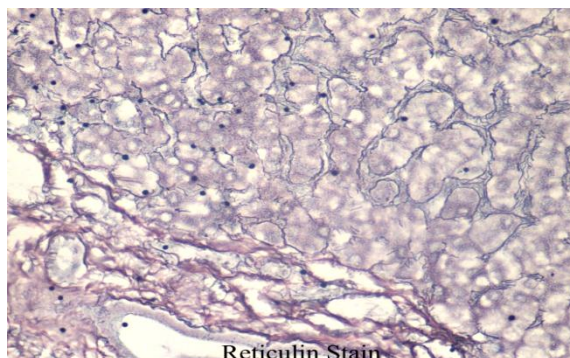
Fleischer' ring was not seen on ophthalmic examination. There were no neurological manifestations. Serum copper and serum ceruloplasmin levels were within normal limits.

Liver biopsy was done. Histopathology examination showed



**Figure 1 : H & E section showing Degenerating Hepatocytes and Pericellular fibrosis**

hepatitis with numerous lymphocytes and neutrophils. Hydropic degeneration of hepatocytes was noted. The most striking histological feature was presence of pericellular fibrosis around individual hepatocytes.



**Figure 2 : Reticulin Stain showing Pericellular fibrosis**

Reticulin stain on the paraffin section confirmed above findings.

## DISCUSSION

Indian Childhood Cirrhosis is restricted to Indian subcontinent, mostly found in rural areas. The onset is insidious with nonspecific complaints such as abdominal distention, irregular fever, excessive crying and altered appetite. The feel of the liver is firm to hard with sharp, 'leafy' edge. [4]

The increased copper in ICC may be secondary to liver damage and impaired biliary copper excretion, [5] may be the result of inherited disorder of copper metabolism akin to Wilson disease, [6] or may simply be the result of excessive copper intake. The change in traditional feeding vessels explains the virtual disappearance of ICC in India.

## CONCLUSION

A rare case of Indian Childhood Cirrhosis in the modern era highlights the

importance of clinical suspicion and relevant investigations in a clinical setting of hepatosplenomegaly and altered appetite in a child.

## REFERENCES

1. Ritchie AC. Boyd's textbook of Pathology. 9th ed. Philadelphia/London: Lea & Febiger Company; 1990.
2. Sen BC. Enlargement of liver in children. Indian Med Gazette 1887;22:338-43.
3. Kissane JM. Anderson's Pathology. 9th ed. New Delhi: Jaypee Brothers; 1990.
4. Anand Pandit and Sheila Bhawe. Present interpretation of the role of copper in Indian Childhood Cirrhosis. Am J Clin Nutr 1996;63:830S-5S.
5. Marwaha N, Nayak NC, Roy S, Kalra V, Ghai OP. The role of excess

copper in the evolution of Indian  
Childhood Cirrhosis. Indian J Med  
Res 1981;73:395-403.

6. Tanner MS. Wilson's disease. Curr  
pediatr 1991;1:202-5.

\*\*\*\*\*