



Review Article

Eruptive Abnormalities: An Interdisciplinary Approach

Aravind S Raju¹, Vinay P Reddy¹, Nikhilanand Hegde¹, Chandrashekar B.S¹, Vani .J¹, Mahendra S¹

¹Krishnadevaraya College Of Dental Sciences & Hospital , Bangalore , India

*Correspondence Email: aravindraju@rediffmail.com

Received: 20/11/2011

Revised: 1/12/2011

Accepted: 5/12/2011

ABSTRACT

This article overviews the eruptive abnormalities which involves interdisciplinary approach which includes impaction, transposition, ectopically erupting, congenitally missing, ankylosed teeth and supernumerary teeth. In the course of clinical practice, it is inevitable that one will encounter the above mentioned abnormalities. The treatment plans developed to address these anomalies must take into account the space needs of the patient and how one can best gain, maintain, or redistribute that space which helps to provide an adequate orthodontic treatment with an interdisciplinary approach.

Key Words: Eruptive abnormalities, impaction, transposition.

INTRODUCTION

Tooth eruption involves the migration of the teeth from a nonfunctional position within the bone to a functional position in the jaw. Eruptive abnormalities complicate the achievement of optimal orthodontic outcomes. In this article, the term eruptive abnormality is broadly defined to encompass a number of anomalies. These include impacted, ectopically erupting,

transposed, congenitally missing, ankylosed teeth and supernumerary teeth. The treatment of these anomalies has caught the imagination of many in dental profession. However, the orthodontic / surgical modality has achieved the most satisfactory result in long-term.

Impaction

Tooth impaction is the failure of a tooth to erupt. This failure to erupt can be

attributable to a physical impedance of the eruption path or to displacement of the tooth so that it cannot erupt. [1] The incidence of impaction, in descending order of occurrence, is as follows: maxillary and mandibular third molars, maxillary cuspids, second premolars, maxillary central incisors, mandibular cuspids, second molars, lateral incisors, and first premolars. [2-6] Treatment options with the different impacted teeth are essentially the same. They include extraction of the impacted tooth, making space for the tooth in the arch, with or without surgically

uncovering the tooth and placing a traction force to bring it into the arch. If there is adequate space in the dental arches, as determined by space analysis (with cephalometric correction), then the usual treatment of choice is to attempt to bring the tooth into the arch (except for third molars). If it is determined that there is a lack of space, then the practitioner must decide which teeth need to be extracted to achieve optimal alignment. The difference is in the decision-making process when choosing a treatment plan.

Third Molar Impaction:

Winter [7] has classified mandibular third molar impaction as follows: Mesioangular impaction, Distoangular impaction, Vertical impaction. (Fig 1). There is scientific evidence available regarding the role of mandibular third molars in the management of space in orthodontics. The presence of developing mandibular third molar with insufficient space can be one of the cause of late mandibular arch crowding. If Mandibular third molars are extracted, the space can be used for distal uprighting of the mandibular buccal segments, especially in nonextraction therapy during orthodontic treatment.

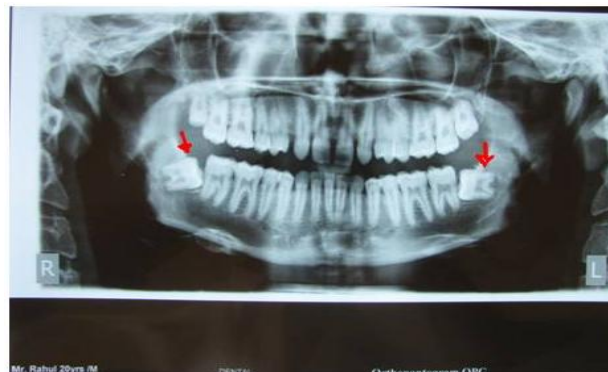

Fig 1. OPG showing impacted Mandibular third Molar

Incisor Impaction:

In a number of instances, the incisor is prevented from erupting into the arch because of the presence of a heavy band of tissue physically obstructing eruption. (fig 2,3)

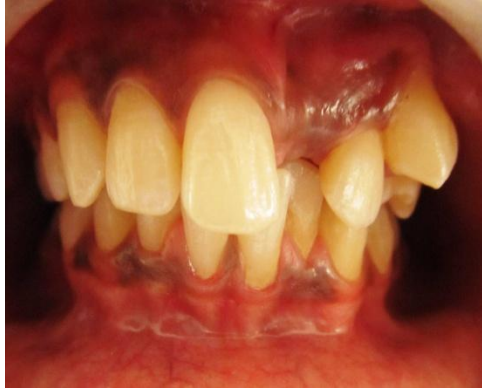

Fig 2.Impacted Central Incisor

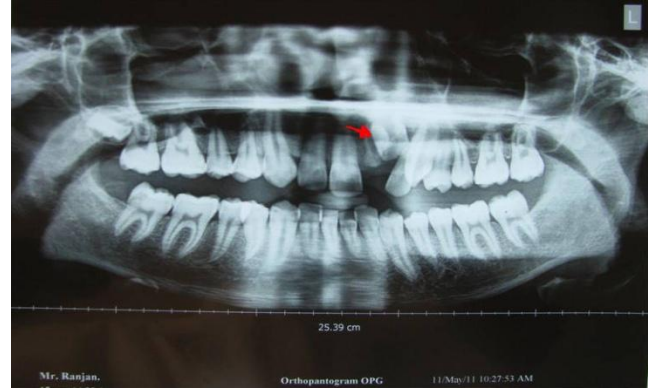

Fig 3. OPG showing Impacted Central incisor

This is usually the result of premature loss of the deciduous incisor tooth. Treatment of this type of soft tissue impaction consists of surgically making a "window" in the tissue at the incisal edge of the tooth and then the incisor tooth is allowed to erupt through the opening. It is sometimes necessary to bond an attachment to the incisor and use a traction force, applied either directly to the attachment or indirectly to the attachment via a chain or ligature wire.(Fig 4)

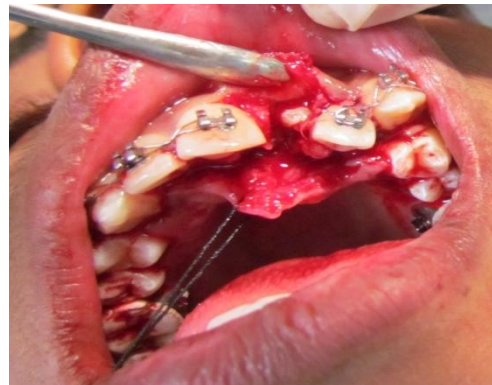

Fig 4.Surgical Exposure of Impacted Maxillary Central Incisor with orthodontic attachment for traction

When traction is to be applied, the tooth can be erupted through an "open window," as described, or the mucosa can be allowed to heal over the site. [8] Although incisor impactions are encountered less frequently than cuspid or premolar impactions, the clinical management of these patients is made more challenging because of the high aesthetic importance these teeth have to the patients. The practitioner must pay particular attention to the gingival heights and contours in the region of the incisors before, during, and after eruption have been completed. Periodontal consultation is often advisable.

Second Molar Impaction

Impacted mandibular second molars usually present with a unique set of problems. More often than not, the mesial marginal ridge of the second molar is "caught" below the distal contact of the first molar (Fig 5,6).

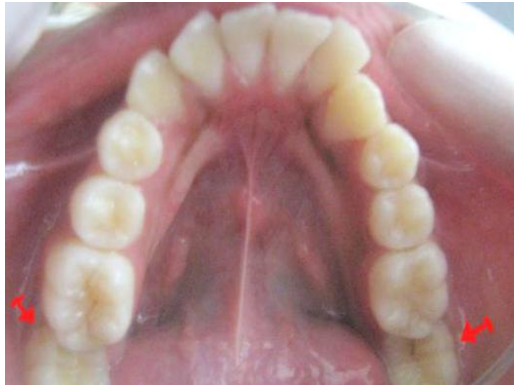

Fig 5. Impacted Second Mandibular Molar

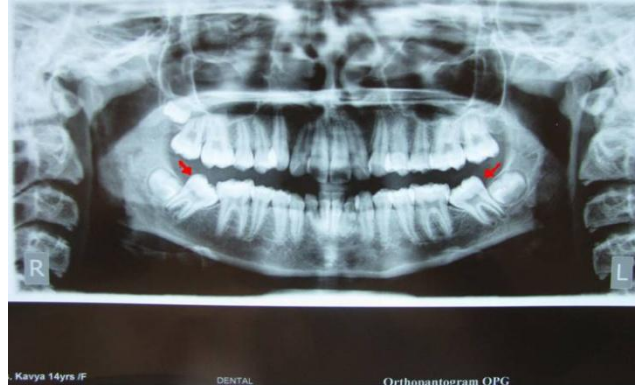

Fig 6. OPG showing Impacted second Mandibular Molar

The methods of uprighting these impacted teeth include surgical repositioning [9-10] and orthodontic repositioning. Various methods of uprighting of the impacted second mandibular have been shown in the literature. There is also the possibility of extracting the second molars and allowing the third molars to erupt in their place; however, it is difficult to predict whether the third molars will erupt optimally. Surgically uprighting the second molars is also a treatment possibility. There are several drawbacks to surgical intervention, however. These include loss of vitality, stunted root formation, ankylosis, and resorption of the second molar. [9]

Premolar Impaction

The treatment options for impacted premolars are influenced by the premolars' value to the dentition during orthodontic treatment. As in other treatment plans, a thorough space analysis should be

performed. If there is adequate space within the arch, then the premolar is brought into the arch in a similar manner as for an impacted cuspid tooth. Space for the impacted premolar is made to accommodate it. The tooth is then surgically uncovered and an attachment bonded onto it. A traction force is applied and the tooth erupted into the arch. [11-12] Another treatment option is to extract the impacted tooth and treat the patient as if the impacted premolar was congenitally missing.

Ectopic Eruption

Ectopic eruption can be broadly defined as the emergence/ eruption of a tooth in a site different from its normal location, including all three planes of space: vertical, horizontal, and anteroposterior.

Canine Ectopic Eruption

Ectopically erupting canines have been said to occur with an incidence of

approximately 0.9% to 2%. [13,14] Although the incidence of cuspid ectopic eruption is relatively low, the potential sequelae of this wayward process carry sufficient dental morbidity to warrant great care in the screening of patients. One of the sequelae of ectopic cuspid eruption is root resorption of the lateral or central incisor, or, rarely, the first premolar. [15] Resorption has been estimated to be present in 12.5% of ectopically erupting canines. Females are affected more often than are males [16] and

the resorption rates for those canines buccally located and those palatally located were approximately the same. The treatment of ectopically erupted canines depends on a variety of factors with interdisciplinary approach involving surgery and orthodontics. The clinician needs to decide whether the cuspid can be moved to its "normal" position without causing or exacerbating resorption of the adjacent teeth (Fig.7).

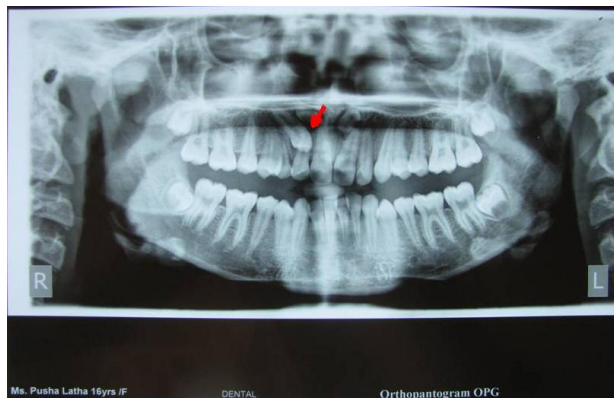


Fig 7. OPG showing Ectopic Erupting Maxillary Canine

If the latter is not possible, then canine extraction may be the best treatment. If the canine can be moved to its normal position without passing in close proximity to other tooth roots or is actually moved from the vicinity of a resorbing root, then orthodontically moving the tooth is likely to be the best option with surgical innervations.(Fig 8).

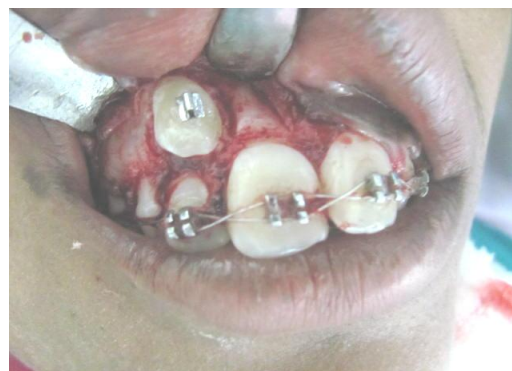

Fig 8.Surgical opening of Impacted Maxillary Canine
With orthodontic attachment for traction

Conversely, if the clinician determines that the amount of root structure resorbed by the ectopically erupting canine was such as to significantly reduce the lifespan of the resorbed tooth root, then it may be prudent to extract the resorbed tooth and allow the canine to erupt in the place of the extracted tooth. Various methods have been showed by different authors in the literature for the management of ectopically erupting canines.

Ectopic Eruption of First Permanent Molar Teeth

Ectopic eruption of the first permanent molar occurs in the maxilla with a much higher incidence (2% to 6%)^[17,18] than occurs in the mandible (~0.2%).^[17] There are two classes of ectopic eruption, reversible and irreversible.^[19,20] Reversible defines a situation in which the permanent molar can free itself from under the distal portion of the second deciduous molar. In the irreversible form, the permanent molar cannot free itself. If allowed to proceed, ectopic eruption of the first permanent molar will result in premature exfoliation of the second deciduous molar with a resultant loss of arch length. The objective of treatment is to maintain the arch length. If treatment is started early enough in the eruptive process, uprighting of the first permanent molar and maintaining the second deciduous molar will achieve the objective. This objective can be achieved employing something as simple as a brass wire separator at the deciduous molar/permanent molar contact. If the loss of arch length that has already occurred is

acceptable, the distal surface of the second deciduous molar can be reduced by discing.

Tooth Transposition

Tooth transposition is the eruption of a tooth in a space normally occupied by another tooth. As mentioned earlier, transposition can be characterized as a specific type of ectopic eruption. The term *transposition* is usually thought to apply to two teeth that have exchanged positions within the dental arch.^[21] Transpositions also can be termed *complete* and *incomplete*.^[22] In an incomplete transposition, the crowns of the teeth have been interchanged, but the roots remain in their same relative positions. The roots and the crowns of the teeth are exchanged in a complete transposition. Although the incidence of this particular eruptive anomaly is low (~0.4%),^[23] there is a relatively high rate of other dental anomalies in patients with transpositions.^[21] These points to the possibility of genetics being one of a number of causative factors in this condition.^[24] Several patterns of transposition have been identified. In decreasing order of occurrence, they are as follows: canine-first premolar; canine lateral incisor; lateral incisor-central incisor; and canine-central incisor.^[21] It should be noted that there was another transposition listed, canine-first molar; however, the authors of that study had to go back to 1966 to find a report of that anomaly.

Because of the difficulty of moving the roots past one another without causing other damage, these teeth are optimally

treated in their transposed positions. Careful consideration of alveolar width and the integrity of the supporting attached tissue are required. They can be orthodontically positioned as if they belong in the space in which they have erupted. They are then made aesthetically more pleasing, if desired, by prosthodontic methods.

Congenitally missing teeth

Hypodontia, or congenitally missing teeth, is the most commonly encountered

dental "eruptive" anomaly in humans. [25] Excluding congenitally absent third molar teeth, the prevalence of hypodontia is 3.5% to 8% of the population. [26] Approximately 20% to 23% of the population are missing one or more third molars. [27] After taking into account third molars, the most commonly missing teeth are the second premolars and maxillary lateral incisors (Fig.9)

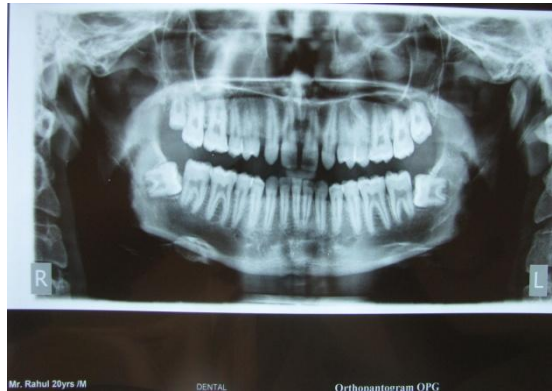

Fig 9. OPG showing congenitally Missing Bilateral Maxillary Lateral incisor.

It is important to note that different races have different predilections for congenitally missing teeth. For instance, the most commonly missing teeth in the Asian dentition are the mandibular incisors.(Fig.10,11)

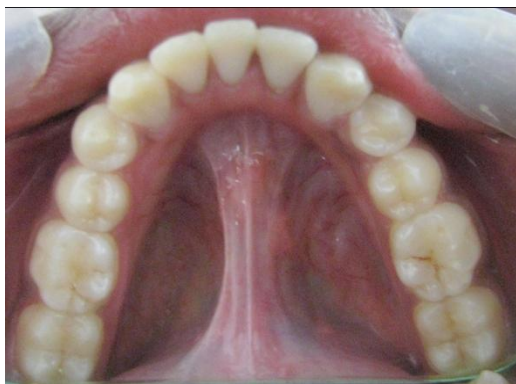

Fig 10. Congenitally Missing Mandibular Lateral Incisor

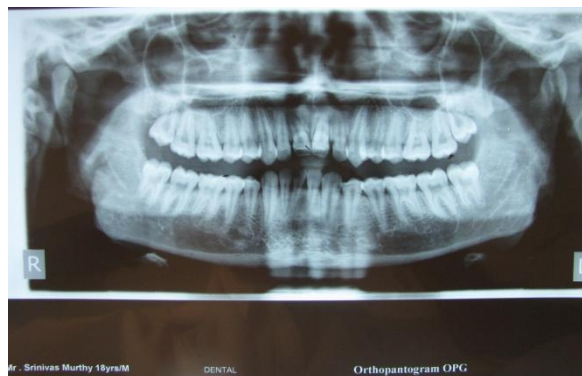

Fig 11. OPG showing Congenitally Missing Mandibular Lateral incisor

The treatment for congenitally missing teeth is dependent on the number and position of the missing teeth. If there is crowding anticipated in the arch, then the missing tooth may be used like an extraction space. Otherwise, the space can be restored by a variety of prosthetic appliances. These include fixed and removable partial dentures, resin-bonded partial denture or an osseointegrated implant anchoring a fixed restoration. In these instances, orthodontics may be used as an adjunct to the prosthetic treatment. The goal of the orthodontic treatment, if necessary, is to close or redistribute the space so as to optimize the occlusal and aesthetic effectiveness of the prosthetic restorations.

Supernumerary teeth

Supernumerary teeth can be defined as those teeth in excess of the normal dental formula. The incidence varies among different populations, but it has been reported to range from 0.1% to 3.6%. [28] Seventy-six percent to 80% of patients with supernumerary teeth have only one supernumerary tooth. A pair of supernumerary teeth is found in 12% to 23% of all cases, and fewer than 1% of the patients had three or more supernumerary teeth. [29]

The most common area in which supernumerary teeth are found is in the premaxilla, specifically, the mesiodens, which is located between the central incisor teeth. (Fig.12,13).

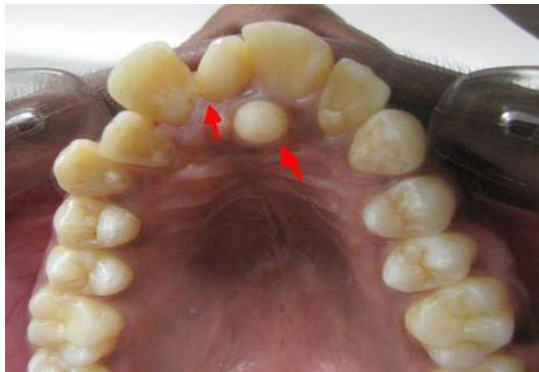


Fig 12. Mesiodens

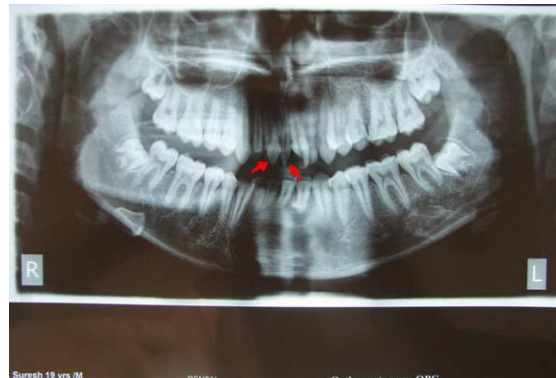

Fig 13 : OPG showing mesiodens

The other regions, in descending order of occurrence, in which these extra teeth are found are the maxillary third molar, the mandibular third molar, mandibular premolar, mandibular incisor, and maxillary premolar regions. [28,29] Supernumerary teeth can be classified either by their location or their shape. When classified by location, they are termed as mesiodens, between the

maxillary central incisors; paramolars, usually between the second and third molars; retromolar, distal to the third molars; and parapremolars, in the premolar region. The shapes are divided into supplemental and rudimentary.

Supplemental teeth have a normal size and shape and are difficult to distinguish from a "normal tooth."

Rudimentary teeth are further divided into conical, tubercular, and molariform.

Ankylosed teeth

A situation in which the cementum is directly fused to the bone, presenting as a difficult problem for the patient and for the orthodontist. Ankylosed primary teeth with permanent successors especially primary molars, constitute a potential alignment problem for the permanent. The best treatment according to Profit is the surgical luxation of the tooth followed by orthodontic traction.

In the case of a severely ankylosed and malpositioned tooth, one should the following are treatment options:

1. Exodontia followed by reimplantation. External resorption usually occurs.
2. Exodontia followed by placement of an osseointegrated implant.
3. The single-tooth dento-osseous osteotomy is a feasible procedure for upper ankylosed teeth because of the favorable vascularity of the maxilla. Ideally, the best time to perform this type of osteotomy would be after the facial growth has been completed.

Hence ankylosed teeth often require a combination of surgery and orthodontics if the condition has to be treated properly.

CONCLUSION

This article has attempted to provide a useful overview of some of the eruptive abnormalities that are encountered in clinical practise. It is hoped that this will provide a rationale for the different treatment modalities that are used in the correction of these anomalies with a multidisciplinary approach which helps in

proper diagnosis and facilitate adequate treatment.

REFERENCES

1. Shafer WG, Hine MK, Levy BM. Developmental disturbances in number of teeth. In: A textbook of oral pathology. Philadelphia: WB Saunders:2003 :66-7.
2. Aitasalo K, Lehtinen R, Oksala E. An orthopantomographic study of prevalence of impacted teeth. *IntJ Oral Surg* 1972;1:117-120.
3. Dachi SF, Howell FV. Survey of routine full mouth radiographs. *Oral Surg Oral Med Oral Pathol* 1961; 14:1165-1169.
4. Kramer RM, Williams AC. The incidence of impacted teeth. *Oral Surg* 1970;20:237-41.
5. Oikarinen VJ, Julku M. Impacted premolars: An analysis of 10,000 orthopantomograms. *Proc Finn Dent Soc* 1974;70:95-98.
6. Thilander B, Myrberg N. The prevalence of malocclusion in Swedish schoolchildren. *ScandJ Dent Res* 1973;81:12-20.
7. Winter BG. Principles of exodontia as applied to the impacted mandibular third molar. St. Louis, American Medical Book Company. 1926
8. Reiner TR. A technique for placing traction on impacted anterior teeth. *AmJ Orthod* 1996; 10:573-4.
9. Pogrel MA. The surgical uprighting of mandibular second molars. *AmJ Orthod* 1995;108:180-183.
10. Terry BC, Hegtvedt AK. Self-stabilizing approach to surgical uprighting of the mandibular second molar. *Oral Surg Oral Med Oral Pathol* 1993;75:674-80.

11. Siervo S, Pampalone A, Siervo P, et al. Rescue of a "hopeless" second premolar. *Oral Surg Oral Med Oral Pathol* 1993;76:276-8.
12. Shapiro Y, Borell G, Kuftinec MM. Bringing impacted mandibular second molars into occlusion. *J Am Dent Assoc* 1996;127:1075-1078.
13. Thilander B, Jacobsson S. Local factors in impaction of maxillary canines. *Acta Odont Scand* 1968;25:145-68.
14. Ericson S, Kurol J. Longitudinal study and analysis of clinical supervision of maxillary canine eruption. *Commun Dent Oral Epidemiol* 1986; 14:172-6.
15. Postlewhaite KM. Resorption of premolar roots by ectopic canines. *Br Dent J* 1989;167:397-8.
16. Sasakura H, Yoshida T, Murayama S. Root resorption of upper permanent incisor caused by impacted canine. *IntJ Oral Surg* 1984; 13:299-306.
17. Young DH. Ectopic eruption of the first permanent molar. *J Dent Child* 1957;24:153-62.
18. Cheyne VD, Wessis KE. Impaction of permanent first molar with resorption and space loss in region of deciduous second molar. *J Am Dent Assoc* 1947;35:774- 87.
19. Lin YTJ. Ectopically erupting mandibular first permanent molar: Treatment of a case. *J Glin Pediatr Dent* 1996,21:31-33.
20. Bjerklin K, Glerup A, Kurol J. Long-term treatment effects in children with ectopic eruption of the maxillary first permanent molars. *EurJ Orthod* 1995; 17:293-304.
21. Peck S, Peck L. Classification of maxillary tooth transpositions. *Am J Orthod* 1995;107:505-17.
22. Wasserstein A, Tzur B, Brezniak N. Incomplete canine transposition and maxillary central incisor impaction: A case report. *Am J Orthod* 1997;111:635-39.
23. Chattopadhyay A, Srinivas K. Transposition of teeth and genetic etiology. *Angle Orthod* 1996;66:147-52.
24. Peck L, Peck S, Attia Y. Maxillary canine-first premolar transposition, associated dental anomalies and genetic basis. *Angle Orthod* 1993;63:99-109.
25. Shapiro SD, Farrington FH. A potpourri of syndromes with anomalies of the dentition. *Birth Defects* 1983;19: 129-40.
26. Pilo R, Kaffe I, Amir E. Diagnosis of developmental dental anomalies using panoramic radiographs. *J Dent Child* 1987;54:267-72.
27. Zhu JF, Marcushamer M, King DL. Supernumerary and congenitally absent teeth: A literature review. *J Glin Pediatr Dent* 1996;20:87-95
28. Satokata I, Maas R. *Msx1* deficient mice exhibit cleft palate and abnormalities of craniofacial and tooth development. *Nature Genet* 1994;6:348-56.
29. Ysof WZ. Non-syndromal multiple supernumerary teeth: Literature review. *J Can Dent Assoc* 1990;56:147-9.
