



Original Research Article

The Macroscopic & Microscopic Study of Associated Variant Viscera in a Gastroschisis Foetus

Vinnakota Sunitha^{1*}

¹Associate professor, Department of Anatomy, Maharajah's Institute Of Medical Sciences, Nellimarla, Vizianagaram-535 217, Andhra Pradesh, India.

*Correspondence Email: laksaca@gmail.com

Received: 23/11/2011

Revised: 7/12/2011

Accepted: 10/12/2011

ABSTRACT

Gastroschisis, an abdominal wall defect typically occurs to the right of umbilicus. The viscera protrude into the amniotic cavity and are bathed by amniotic fluid. This disorder affects 1 in 20,000 live births. A stillborn male human foetus of 20 weeks gestation period was brought from one of the private nursing homes. In the present case the defect was on the left side of umbilicus. Associated anomalies except intestinal atresias (seen in 15%) and undescended testis are uncommon, but in the present case associated variant viscera like ectopic pancreas, bovine arch, transverse lobulation of both kidneys were noted.

Key words: Gastroschisis, ectopic pancreas.

INTRODUCTION:

The term gastroschisis means a “split or open stomach”, is a misnomer because the split is in the anterior abdominal wall, but not in the stomach.^[1] The defect usually occurs on the right side. The prevalence of gastroschisis is increasing and has been documented in several countries throughout the world.^[2] The frequency of gastroschisis is associated with young maternal age, low number of gestations, pre-eclampsia, reduced birth weight, smoking & drug abuse. Associated anomalies except

intestinal atresias (seen in 15%) and undescended testis are uncommon,^[3] but in the present case associated variant viscera like ectopic pancreas, bovine arch, transverse lobulation of both kidneys were noted.

MATERIALS&METHODS

A still born male foetus of 20weeks gestational age was brought to anatomy department of MIMS from one of the private nursing homes in Vizianagaram by post graduates for their project work.

The foetus was embalmed & allowed for fixation in 10% formalin.

Thorax & abdomen were opened and morphological features of various viscera were noted macroscopically & then viscera like lung, liver, kidney, pancreas, testis, spleen & ectopic tissue, which were located between two kidneys were subjected to histological examination.

OBSERVATIONS:

An abdominal wall defect of 3.5cmX3cm was found at 3cm away from umbilicus in the left lateral abdominal wall, through which large part of liver & few coils of

small intestine had herniated (fig:1). The contents were not covered by any membrane. No other anomalies were detected.

I: Macroscopic:

Right lung was found normal. Hilum of left lung faces anteriorly as the lung was rotated and pushed posteriorly. Heart was vertically placed in the middle mediastinum with apex pointing downwards instead of horizontal inferior border and left sided apex. A common trunk for both brachio cephalic and left common carotid artery called as “Bovine arch” was noticed (fig.2).

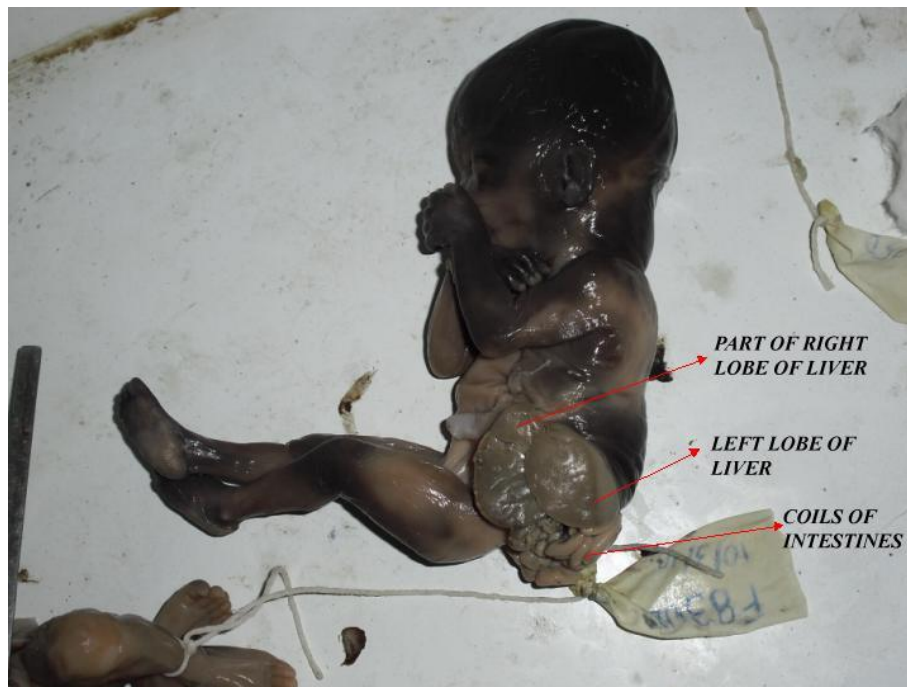

Fig 1: Showing site of GS, herniated portion of Liver & coils of Intestine

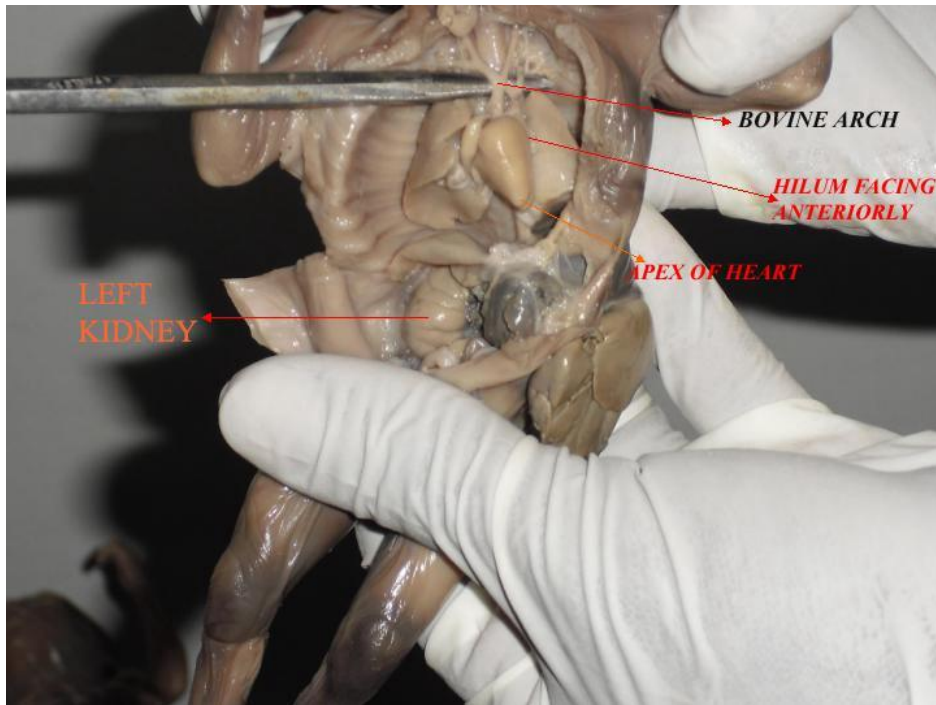


Fig 2: Showing Bovine arch, apex of heart& anteriorly placed hilum of left lung.

B: Abdomen:

Entire left upper abdomen was occupied by distorted and displaced liver. Liver appears trilobed. The part of right lobe, which was outside the abdominal cavity was pale in color and appears as a separate lobe. The part of right lobe, which was within the abdominal cavity was dark in the color and appears as a separate lobe. The whole left lobe was outside the abdominal cavity and twisted, thus giving trilobed appearance (fig.3). The stomach appeared compressed and folded (fig.4). The pancreas and spleen were normal to the age in the size and their location. Few coils of small intestine had herniated through the lateral abdominal wall defect (fig.1). Right kidney was immediately visible as liver and coils of intestine occupied left half of upper abdomen (fig.2). Both kidneys show transverse lobulation, but more on the right side. Both testis appear normal and were located at the abdominal end of inguinal canal, which corresponds to gestational age (fig.4)

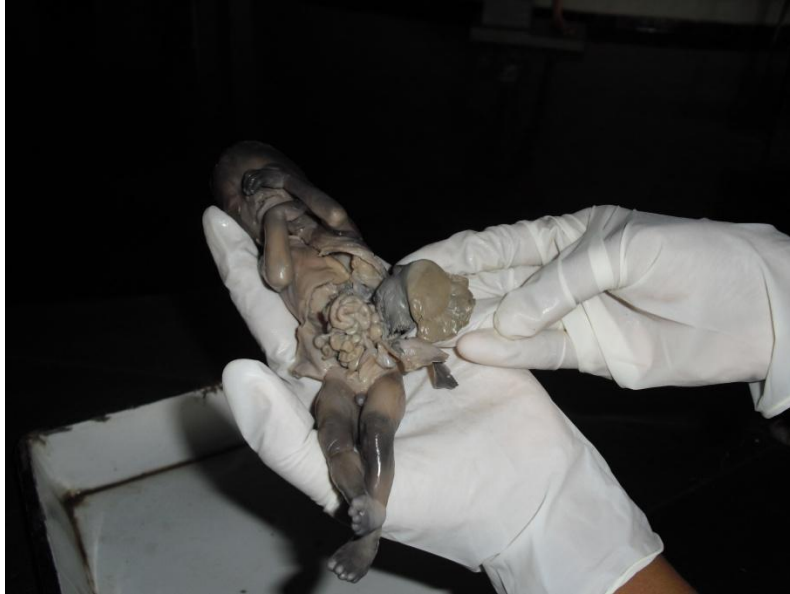

Fig 3: Showing displaced & distorted Liver & coils of Intestine

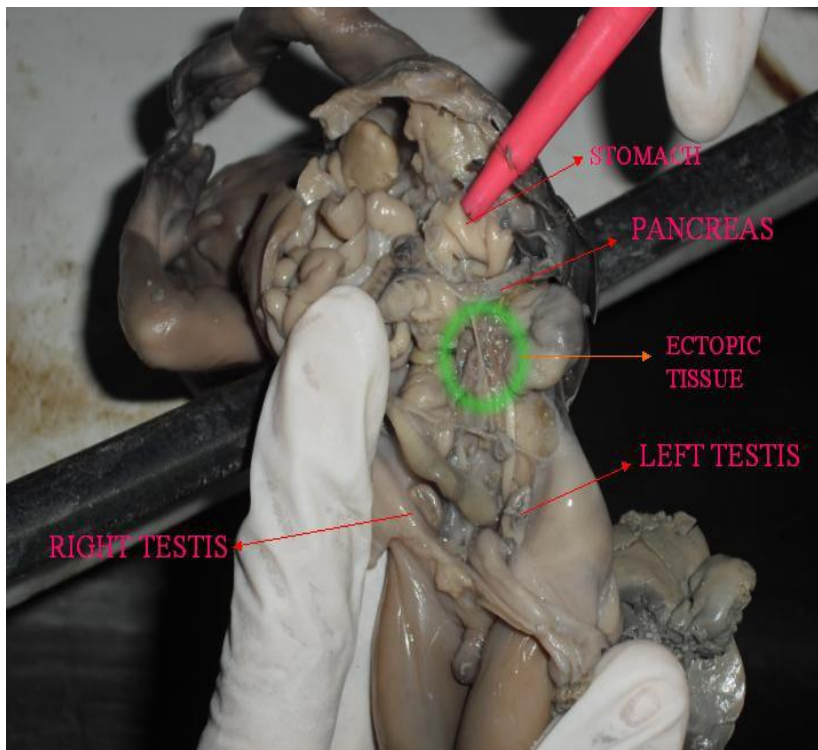


Fig4: Showing abdominal viscera after removal of coils of Intestine

Ectopic tissue:

An ectopic tissue in the form of rod around 1cm in length extends obliquely from hilum of right kidney to upper pole of left kidney crossing inferior venacava, abdominal aorta and renal vessels. Ectopic tissue appears lobulated and pink in color (fig.4).

Microscopy:

Microscopic structure of both lungs corresponds with the gestational age (fig.5). In liver central vein was prominent with radiating cords of hepatocytes. Angiogenesis was also noted. This corresponds with gestational age (fig.6). No variation was noted in the histological structure of kidney (fig 7). The microscopic structure of pancreas presented aggregation of acini into small lobules with small clusters of islets of langerhans getting entrapped. The acinar cells appear to be more matured with deposition of zymogen granules in the cells & have prominent nuclei (fig 8). The ectopic tissue shows secondary branching of endodermal ducts with cuboidal epithelium and abundant undifferentiated mesenchymatous tissue (fig9), as ectopic pancreatic tissue, but not corresponding with the gestational age. The section of ectopic tissue appears as pancreas at 10 weeks gestation.

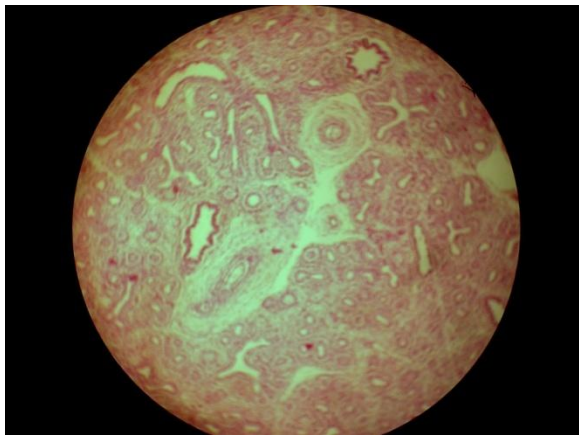


Fig5: Showing microscopic structure of lung, H&E, 10X10

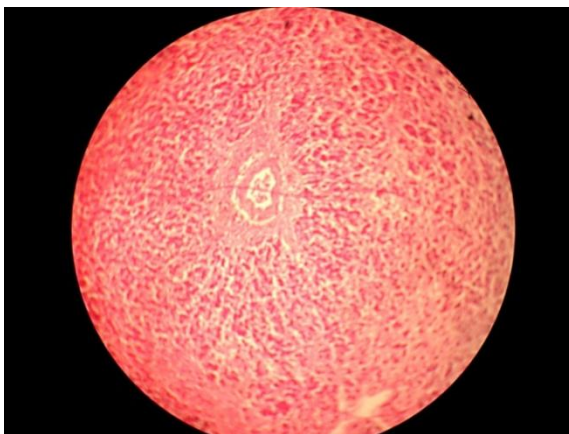


Fig 6: Showing microscopic structure of liver, H&E, 10X10.

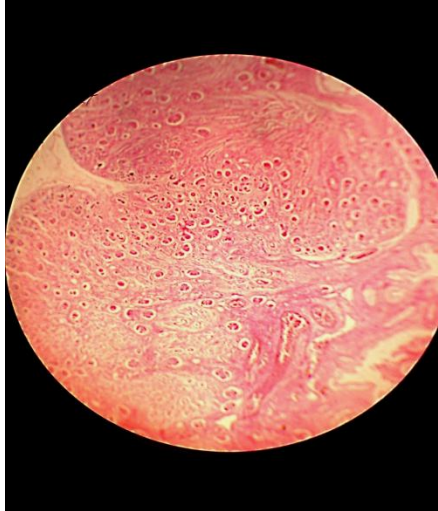


Fig 7: Showing microscopic structure of kidney, H&E, 10X10.

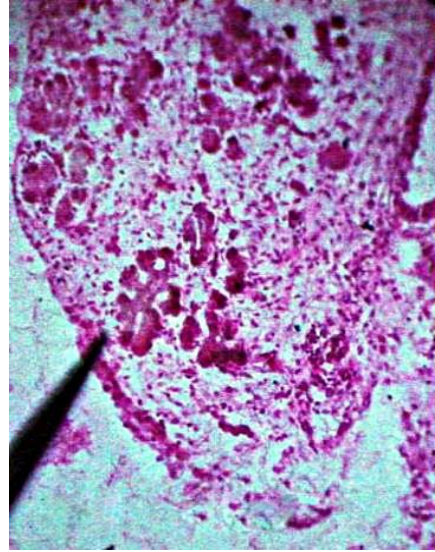


Fig 9: Showing microscopic structure of ectopic tissue in high power indicating as ectopic pancreas of 10 weeks G.A.

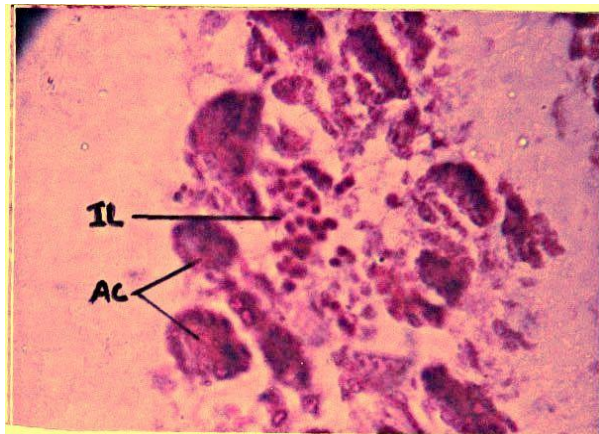


Fig 8: Showing entrapment of islets of pancreas, H&E, 10X40.

DISCUSSION

Gastroschisis is typically an abdominal wall defect immediately to the right side of normal umbilical cord, [4] typically only bowel is eviscerated, occasionally other organs but almost never the liver. [5] Left gastroschisis is rare, sixteen cases have been reported in literature. [6] All the macroscopic variations such as anterior

facing of hilum of left lung, vertical location of heart, trilobed liver, lower level of left kidney, malposition of vermiform appendix in left iliac fossa were due to distorted & displaced liver, resulted by the herniation of liver & loops of intestines through the defect in lateral wall of abdomen.

The presence of ectopic pancreatic tissue also may be due to herniation & displacement of liver. Ectopic pancreas has

no anatomic or vascular connection to the main pancreas and results from altered development of 2 primitive pancreatic buds that fuse to form the uncinata, head, body & tail of the normal gland. This results in an ectopic rest being dropped from the dorsal pancreatic rudiment. [7]

A change in paternity (child bearing with different fathers) has been implicated as a risk factor in a recent study, suggesting that the immune system of the mother may play a role in the development of gastroschisis. [2] There is 4 times risk of having gastroschisis if the mother had both STD & UTI just before or early pregnancy. [8]

A link between birth defect gastroschisis and chemical atrazine has been found in a study presented at the society for maternal foetal medicine's annual meeting in Chicago. [9]

Embryological basis:

The anomaly results from incomplete closure of the lateral folds during the fourth week of development. [1]

Homeobox genes such as HLXB9 with mutation causing developmental field defects in intra embryonic mesoderm may be responsible for abdominal wall defects. [10]

CONCLUSION

Left sided abdominal wall defects are rare. In the present case the defect is on the left side of umbilicus. Associated anomalies except intestinal atresias (seen in 15%) and undescended testis are uncommon [3] but in the present case there are associated various variant viscera like bovine arch, ectopic pancreas etc., Till date the exact cause of left sided abdominal wall defects is not known, further studies are required as the number of cases are increasing.

ACKNOWLEDGEMENTS

The authors are grateful to the management & Prof Dr T.A.V. Narayanaraju, dean of Maharajah's Institute of Medical Sciences for their encouragement. We would like to thank EDP staff, all the administrative and academic staff for their assistance.

REFERENCES

1. Moore Persaud - Before We Are Born. Essentials of Embryology and Birth defects 6th edn. Saunders, Philadelphia, Pennsylvania 19106-3399 Pp: 251.
2. Christiana D. Chambers, Brian H. Chen, Kristin Kalla, Laura Jernigan, Kenneth Lyons Jones (2007). "Novel risk factor in gastroschisis: Change of paternity". American Journal of medical genetics part A 143 A (7): 653-659.
3. M.S.Rmakrishnan; Paediatric surgery, 1st Edn. Jaypee Brothers, Medical publishers (p) LTD. New Delhi, Pp 278
4. Sadler, T.W. : Langman's medical Embryology In: Body cavities. 10th edn. Wolters Kluwer(India)Pvt. Ltd New Delhi . Pp 151-158 (2007).
5. David A, Nyberg, John P, Mc. Gahan Dolores H. pretorius: Diagnostic imaging of foetal anomalies, 2003 Pp 511-528
6. Suver D, Lee S, Shekherdimian S, Kim S (2008) Review left sided gastroschisis: higher incidence of extra intestinal congenital anomalies. The American Journal of Surgery 195: 663-666.
7. Sadler, T.W: Langman's medical Embryology In: Body cavities. 10th

Edn. Wolters Kluwer(India)Pvt. Ltd
New Delhi. Pp: 151-158(2007).

8. University of Utah Health Sciences (June 23,2008). "Sexually Transmitted Disease, Urinary Tract Infections May Be Bad Combination For Birth Defect". Science Daily. http://www.sciencedaily.com/releases/2008/06/080620195439.htm.
9. www.medindia.net.Research news.6 Feb 2010 Rajshri.
10. Keppler-Noreuil KM.(2002) OEIS complex (Omphalocele-Exstrophy-Imperforate anus-Spinal defects): A review of 14 cases. American

Journal of Medical Genetics.107: 72-76.

ABBREVIATIONS

1. GS: Gastroschisis.
2. H&E: Haematoxylin & eosin.
3. STD: Sexually transmitted disease.
4. UTI: Urinary tract infection.
5. CI: Coils of Intestine.
6. HLL: Hilum of left lung.
7. LK: Left kidney.
8. RK: Right kidney.
9. RT; Right testis.
10. LT: Left testis.
11. IL: Islets of pancreas.
12. AC: Acini of pancreas.
