

Non-Surgical Management of Extraoral Cutaneous Sinus Tract with Odontogenic Origin of Mandibular Incisors - A Case Series

Dr. Priyanka Rudrapada¹, Dr. Prashanth BR², Dr. Rupali Karale³,
Dr. Jaishri Khed⁴, Dr. Manjula SP⁵

¹Final Year Post Graduate Student, Dept of Conservative Dentistry and Endodontics, KLE Society's Institute of Dental Sciences, Bengaluru

²Professor, Dept of Conservative Dentistry and Endodontics, KLE Society's Institute of Dental Sciences, Bengaluru

³Professor and HOD, Dept of Conservative Dentistry and Endodontics, KLE Society's Institute of Dental Sciences, Bengaluru

⁴Reader, Dept of Conservative Dentistry and Endodontics, KLE Society's Institute of Dental Sciences, Bengaluru

⁵Reader, Dept of Conservative Dentistry and Endodontics, KLE Society's Institute of Dental Sciences, Bengaluru

Corresponding Author: Dr. Priyanka Rudrapada

DOI: <https://doi.org/10.52403/ijhsr.20240530>

ABSTRACT

An extraoral sinus is normally the consequence of long-standing odontogenic chronic infection due to caries, trauma, or more rarely periodontal infection or disease. In the extraoral form, the sinus tract may open anywhere on the face or the neck. It is commonly found on the cheeks, the chin, the angle of the mandible, and occasionally on the nasal floor. Extraoral odontogenic sinus tract can be treated either by conventional surgical methods and non-surgical methods. This case series reports conservative management of two cases of misdiagnosed extraoral sinus tracts of odontogenic origin in different parts of the face and the neck. These case reports provide evidence that nonsurgical management of periapical lesions shows a high success rate and nonsurgical approach should be adopted before resorting to surgery.

Keywords: Extraoral cutaneous sinus tract, extraoral sinus, odontogenic origin, mandibular incisors

INTRODUCTION

An extraoral sinus is the result of a persistent, long-lasting odontogenic infection brought on by trauma, dental caries, or, less frequently, a periodontal infection or illness. The resulting inflammatory or suppurative material drains from the tooth or periodontal tissues either intraorally or extraorally via an epithelial-lined tract or communication, depending on the location of the affected tooth. [1]

Once it leaves the root apex area and passes through bone and soft tissue, the infection will take the least resistance path. Following a breach in the cortical plate, the sinus tract's point of escape is dictated by the location of muscle attachments and fascial sheaths, the tooth's position within the dental arch, the bone's thickness, and the distance the tract travels before reaching the intra- or extraoral environment. [2]

The sinus tract may open anywhere on the face or neck in the extraoral type. It usually appears on the chin, cheeks, mandibular angle, and rarely on the nasal floor. With an 80–87% frequency, extraoral sinus tracts are frequently associated with mandibular teeth. Extraoral sinus tracts of dental origin may be wrongly diagnosed as several disorders in the differential diagnosis, such as congenital midline sinus of the upper lip, TB, osteomyelitis, neoplasms, ingrown hair or clogged sweat gland ducts, and local cutaneous infections. [3]

Despite reports in the literature, doctors tend to neglect cutaneous odontogenic sinus, one of the significant differential diagnoses of face sinus lesions, but dentists are not susceptible to this condition. [4] Due to incorrect identification or treatment of the basic dental aetiology, there have been many cases of several ineffective treatment regimens, including surgical excisions, biopsies, systemic antibiotic regimens, and radiation. [5] A cutaneous odontogenic sinus is typically a nodulocystic lesion, and 80% of such lesions are most frequently located on the chin or jaw. [4]

The extraoral odontogenic sinus tract can be treated with both traditional surgical and non-surgical techniques, including the Apexum procedure, conservative root canal therapy without adjunctive therapy, decompression technique, active nonsurgical decompression technique, aspiration and irrigation technique, lesion sterilization and repair therapy. [6]

Given the importance of the diagnosis and management of these lesions and avoiding unnecessary treatments, this case series reports conservative management of two cases of misdiagnosed extraoral sinus tracts of odontogenic origin in different parts of the face and the neck.

CASE REPORT 1

A 35-year-old female patient was referred to the Department of Conservative Dentistry and Endodontics, KLE Society's Institute of Dental Sciences, Bangalore with the chief complaint of pus discharge on the lower chin region since 1 year. Patient reported with discomfort due to pus discharge in the chin region. Patient gives an history of bike accident 10 years ago. No Dental history was revealed. The patient had consulted a dermatologist with a complaint of pus discharge 7 months ago. Gel (unknown) was prescribed by the dermatologist which was used by the patient for 15 days but there were no signs of healing. Patient revisited the dermatologist who further evaluated and referred to a dentist.

On extraoral inspection, there was a submentally located, 2.5×3 mm erythematous, exophytic papule with a crusted surface (Figure 1.1). Surrounding skin was tender to touch, and the lesion exuded pus on palpation. On intraoral examination, the mandibular anterior teeth were intact; however, there was a mild discoloration noticed in relation to teeth #41. On further diagnostic examination, tooth #41 showed a negative response to pulp sensitivity tests and was tender on percussion. There was no mobility or any deep periodontal pockets present. Roentgenographic examination revealed a radiolucency associated with the periapices of teeth #41 (Figure 1.3). Sinus tracing was done with gutta percha point was introduced into the extraoral opening of the tract. The radiograph revealed the GP cone pointing towards the tooth #41. A final diagnosis of an asymptomatic periapical abscess with an extraoral sinus opening was made in relation to teeth #41.

Differential Diagnosis- The differential diagnoses include conditions, such as skin infections, pustules, furuncles, ingrown hair or occluded sweat gland duct, osteomyelitis, neoplasms, tuberculosis, actinomycosis and carcinomas.

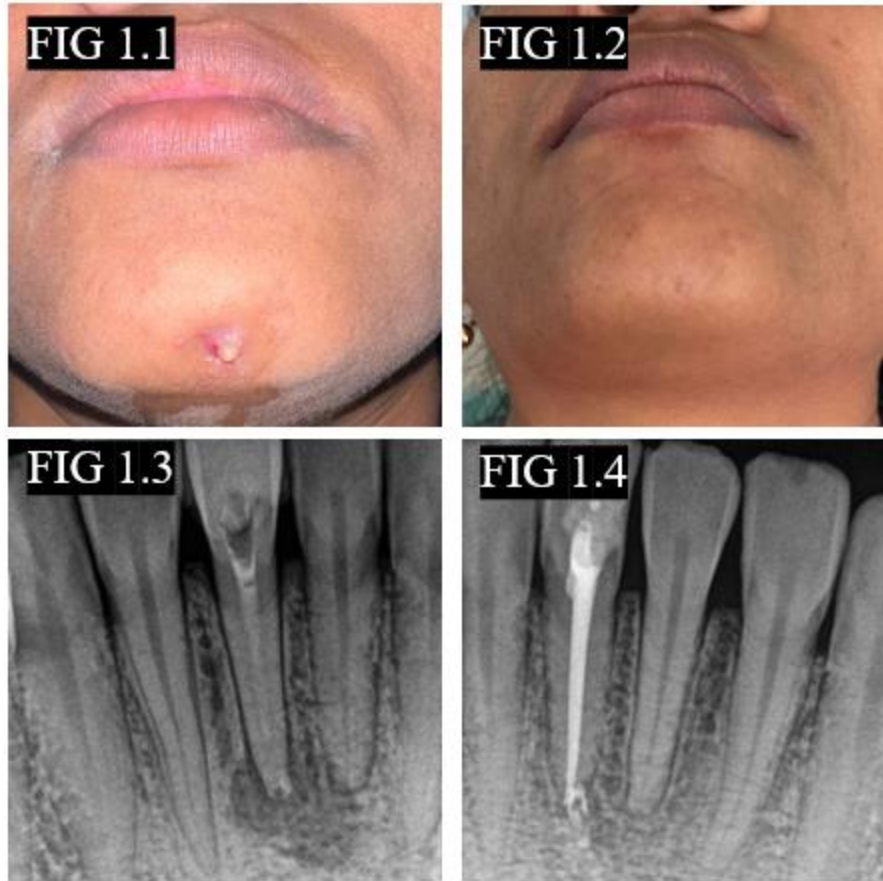


FIGURE 1:

1.1& 1.2: Clinical image of extraoral sinus tract on 1st day and healed sinus tract with 1-year follow-up & 1.4: Radiograph on 1st day and after conventional Root canal therapy with 1-year follow-up

TREATMENT

A conservative approach of non-surgical endodontic therapy was selected. Following isolation with a rubber dam, access cavity preparation was done on teeth #41. Single central canal was detected in #41. Cleaning and shaping which was done using stainless steel K files (Mani, Japan) up to a size 30 (ISO 0.02 taper) for #41. Thorough irrigation was done with 2.5% sodium hypochlorite and 2% chlorhexidine solution following which the canals were dried. Viscous-based Calcium hydroxide (Apexcal, Dentsply) was placed and condensed into the root canals with dry paper points and left inside the root canal system for 14 days. On the subsequent appointment after 2 weeks, the cutaneous nodule had condensed

in size and looked cleaner and less erythematous and infected. Then Oil-based Calcium hydroxide was placed in the canal and left for 1 month and subsequently changed for consecutive 2 months. The patient also reported reduced drainage from the lesion. After 4 months, there were signs of healing of the lesion. Then, rubber dam isolation the root canals were copiously irrigated, dried and obturated by cold lateral condensation technique using AH plus sealer. Access cavity was sealed with Cavit. Permanent restoration was done 1 week after obturation using GIC type 9 (GC Corporation)

OUTCOME AND FOLLOWUP-

At the 1month follow-up, there was complete closure of the extraoral opening with significant healing. The nodular growth had almost disappeared and the patient was comfortable as there were no symptoms. Patient had been recalled every month for follow up and RVG was taken on every follow up. Periapical healing was observed after 4th month in the radiograph and the radiograph of one-year follow up was documented (Figure 1.4). At 1year follow-up there was complete healing of the sinus tract with mild scar formation (Figure 1.2). The tooth was asymptomatic and the patient was quite comfortable and satisfied with the treatment outcome.

CASE REPORT 2

A 45-year old male patient was referred to the Department of Conservative Dentistry and Endodontics, KLE Society's Institute of Dental Sciences, Bangalore, with the chief problem of a pain and pus discharge on the left lower aspect of the chin since 1 month. Patient reported with discomfort and pus discharge extraorally from the left chin region since 1 month. Patient gives an history of bike accident 10 years back and pain was present in the lower front teeth since 10 years. Pain was moderate, intermittent, and throbbing and was aggravating while chewing food. During extraoral inspection, a red lobulated exophytic lesion could be seen at the left of his chin (Figure 2.1). The nodule bled easily upon palpation, it was compressible, and it had a sessile base.

Clinical intra-oral examination revealed poor dental hygiene. All teeth, except tooth 31, reacted positively to cold testing. None of the teeth were tender to percussion. Pocket depths of 4 mm were probed around tooth 31.

Intraoral periapical radiograph revealed a well-circumscribed periapical radiolucency in relation with #31 (Figure 2.3).

Diagnosis of pulpal necrosis with chronic periradicular periodontitis and extraoral cutaneous sinus tract related to 31 was made. Endodontic treatment to tooth #31 was planned.

During the first visit, following the application of a rubber dam, access openings were prepared under the dental operating microscope with an endo access bur (DentsplyMaillefer, USA) in relation to 31. Later, patency was confirmed in tooth #31 using a no. 10 K-file. The root canal was prepared using hand files (K-files). The root canal was abundantly irrigated with 5.2% sodium hypochlorite and 17% EDTA solution with a manual agitation during the entire procedure. Then, a final rinse was performed with 2% Chlorhexidine solution. The canal was dried and Viscous based Ca(OH)₂ (Apexcal, Dentsply) was applied and left for 2 weeks and the access cavity was sealed with Cavit.

At the 2-week follow-up, there was complete closure of the extraoral opening with significant healing. The root canal of tooth #31 was cleaned again with normal saline and it was rinsed with 2% chlorhexidine. Then Oil based Calcium hydroxide was placed in the canal and left for 1month and subsequently changed for consecutive 2 months. After 4months, there were signs of healing of the lesion. Periapical healing was observed after 4th month in the radiograph. Root canal obturation was performed using a master gutta-percha cone and a bio-ceramic endodontic sealer using lateral condensation technique (Figure 2.4) followed by permanent restoration using GIC type 9 (GC Corporation)

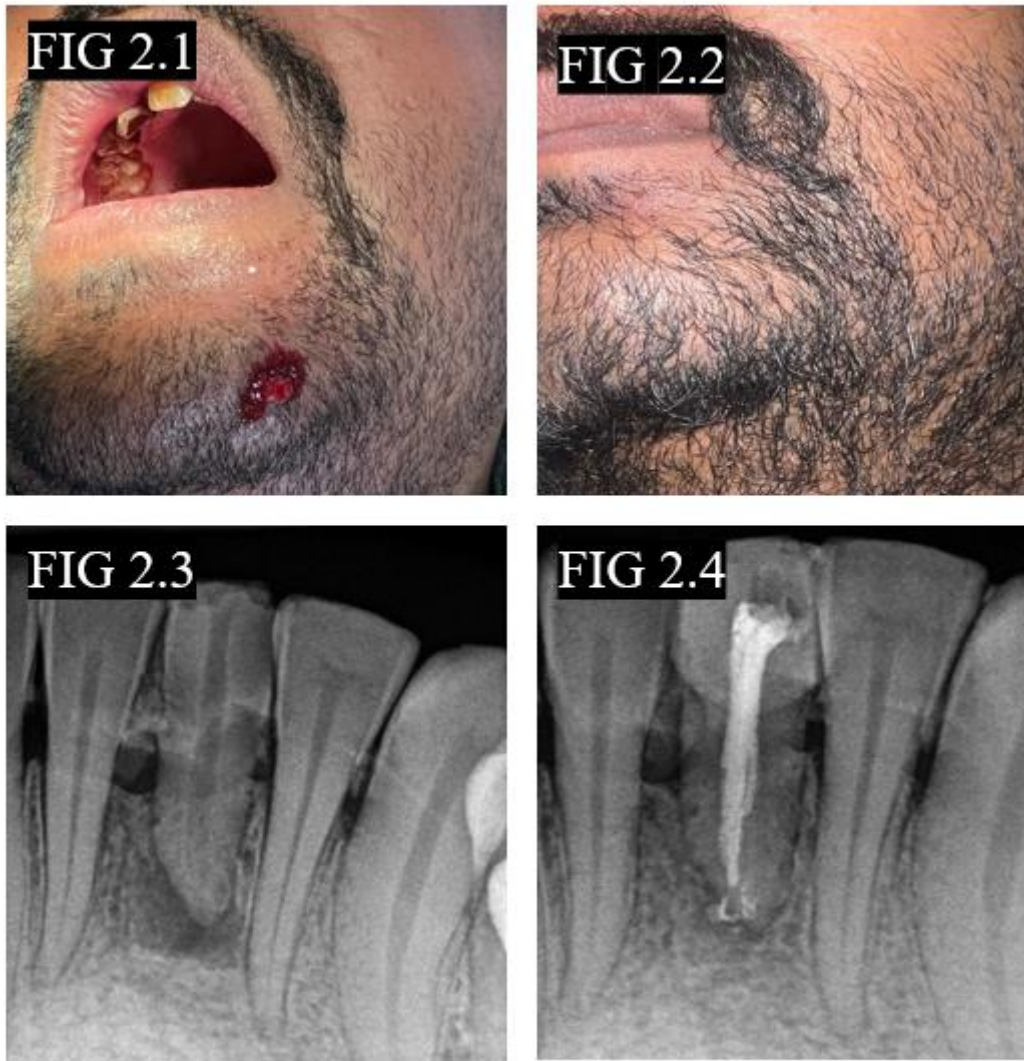

FIGURE 2:

2.1& 2.2: Clinical image of extraoral sinus tract on 1st day and healed sinus tract with 1-year follow-up & 2.4: Radiograph on 1st day and after conventional Root canal therapy with 1-year follow-up

OUTCOME AND FOLLOWUP-

At 1year follow-up there was complete healing of the sinus tract with mild scar formation (Figure 2.2). The tooth was asymptomatic and the patient was satisfied with the treatment outcome.

DISCUSSION

A pathologic channel that begins in the oral cavity and ends at the cutaneous surface of the face or neck is known as an odontogenic cutaneous sinus tract. It frequently has the

appearance of a sunken or retracted skin lesion, a furuncle, a cyst, or an ulcer. [2] Other causes of extraoral odontogenic sinus tracts have been reported in the literature. [5] These include implant failure, retained tooth fragments, impacted teeth, odontogenic cysts, vertical root fractures, and cracked crowns due to trauma. Inflammatory bone resorption is brought on by a protracted periapical infection. The infection erodes the alveolus and proceeds in a peripheral manner, taking the easiest route through the fascial spaces and muscle

attachments until eventually puncturing the cortical bone and coming out through the skin. The relative placements of the infected root apices and proximal muscle attachments, as well as the density of the investing bone, determine the creation of an extraoral sinus tract. The submental region has been reported to be the most often occurring site of extraoral sinus tract opening. The cheek, mandibular angle, canine gap, nasolabial fold, nasal mucosa, upper lip, and inner canthus of the eye are additional locations where extraoral drainage of odontogenic origin has been documented. [5]

Dental infections follow an osteoclastic process that steadily penetrates the alveolar bone, may penetrate nearby soft tissues, and ultimately breaks through the skin. An infection may spread extraorally if the teeth's apices are located above the maxillary and below the mandibular muscle attachments. [7]

There have been reports in the literature of a well-extended periapical lesion regression with just one root canal treatment. Due to the extended age of the sinus tract and the well-epithelialized cord-like tissue, which prevents perfect disinfection and keeps bacteria in the periapical lesion, healing cannot be achieved with merely traditional endodontic therapy. [7]

Because of the non-epithelialized cord-like tissue in both of our patients, standard root canal therapy was sufficient to accomplish complete healing of the cutaneous sinus tract.

The granulomatous tissues that border the extraoral cutaneous sinus tracts typically include a purulent discharge within their lumen. PMNL makes up the majority of the exudate. [8] During a microbiological culture of cutaneous sinus tracts, Caliskan et al. discovered a heterogeneous mixture of facultative and obligate anaerobic bacteria, which were recognized as agents of both skin infections and endodontic abscesses. [9]

Odontogenic cutaneous sinus tracts are difficult for clinicians to diagnose because there was no history of acute dental pain or

discomfort in either case. When the affected tooth was palpated, a cord-like sensation was felt, which appeared to be attached to the nearby underlying bone. By milking the sinus tract, exudation was seen. Research revealed that such pathways are typically lined with granulation tissue and that epithelial tissues are absent from them. It is therefore known that endodontic therapy alone of the tooth causing the problem can do away with the requirement for surgery. Water- and oil-based calcium hydroxide was therefore used as an intracanal medication in this case of non-surgical endodontic therapy.

Due to its antibacterial properties, calcium hydroxide is a substance that is frequently utilized in endodontic treatment. It is believed to promote the development of hard tissue and establish favorable circumstances for periapical healing. According to Souza et al., calcium hydroxide may have four different actions beyond the apex: (a) anti-inflammatory activity; (b) neutralization of acid products; (c) activation of alkaline phosphatase; and (d) antibacterial action. When calcium hydroxide is utilized for endodontic treatment of teeth with periapical lesions, success rates of 80.8 and 73.8% have been documented. [6]

It is important to note that severe tooth decay or an infected extraction socket in conjunction with osteomyelitic bone have been identified as the source of infection in a number of cases of odontogenic extraoral sinus tracts that have been treated surgically by excision. Treatment options other than endodontic therapy would not be appropriate in these circumstances. [11] Because the cutaneous sinus tracts provide a drainage mechanism that reduces swelling and pain, antibiotics were not recommended in either case. Consequently, any involvement of the systemic drainage sinus tract is avoided and the localized state is preserved.

The initial misdiagnosis and the dental origin of the skin lesions were confirmed by the closure of the extraoral sinus tract following nonsurgical root canal therapy. [12] Within 5

to 14 days following root canal therapy or tooth extraction, spontaneous closure of the fistula is predicted in sinus tracts with dental origins (Al-Kandari et al. 1993 [13], Johnson et al. 1999 [14]). In fact, after the first therapy session, the sinus tracts in these cases healed. Extraoral tracts have the ability to heal with granulation tissues, unlike intraoral tracts, which leave a cutaneous scar. For cosmetic reasons, the patients might need to have their scars revised. [7]

CONCLUSION

Periapical lesions can be successfully managed nonsurgically with a high success rate. It is always preferable to try nonsurgical methods before undergoing surgery. Cystic fluid can be drained from the canals using the decompression and aspiration-irrigation procedures. By lowering the hydrostatic pressure inside the periapical lesions, these techniques work. Calcium hydroxide or triple antibiotic paste can be helpful when there is no fluid drainage from the canals. Monitoring the healing of periapical lesions could be done with a variety of evaluation techniques and periodic follow-up tests. When nonsurgical treatment fails, when there are clogged or non-negotiable canals, or when it is not feasible to monitor periapical lesions over an extended period of time, surgery may be the best course of action.

Declaration by Authors

Acknowledgement: None

Source of Funding: None

Conflict of Interest: The authors declare no conflict of interest.

REFERENCES

1. Swales KL, Rudralingam M, Gandhi S. Extraoral cutaneous sinus tracts of dental origin in the paediatric patient. A report of three cases and a review of the literature. *International Journal of paediatric dentistry*. 2016 Sep;26(5):391-400.
2. Curvers F, De Haes P, Lambrechts P. Non-surgical endodontic therapy as treatment of choice for a misdiagnosed recurring extraoral sinus tract. *European Endodontic Journal*. 2017 Jan 1;2(1):13.
3. Azizlou E, Sobhani MA, Ghabraei S, Khoshkhounejad M, Ghorbanzadeh A, Tahan SS. Extraoral Sinus Tracts of Odontogenic Origin: A Case Series. *Frontiers in Dentistry*. 2020;17.
4. Chang LS. Common pitfall of plastic surgeon for diagnosing cutaneous odontogenic sinus. *Archives of Craniofacial Surgery*. 2018 Dec;19(4):291.
5. Varghese, L.L., Bhattacharya, A., Sharma, P. and Apratim, A., 2020. Non-surgical management of an extraoral cutaneous sinus tract of odontogenic origin. *BMJ Case Reports CP*, 13(7), p.e234699.
6. Fernandes M, de Ataíde I. Nonsurgical management of periapical lesions. *Journal of Conservative Dentistry and Endodontics*. 2010 Oct 1;13(4):240-5.
7. Kallel I, Moussaoui E, Kharret I, Saad A, Douki N. Management of cutaneous sinus tract of odontogenic origin: Eighteen months follow-up. *Journal of Conservative Dentistry and Endodontics*. 2021 Mar 1;24(2):223-7.
8. Witherow H, Washan P, Blenkinsopp P. Midline odontogenic infections: A continuing diagnostic problem. *Br J Plast Surg*. 2003;56:173-5. [PubMed: 12791368]
9. Caliřkan MK, Sen BH, Ozinel MA. Treatment of extraoral sinus tracts from traumatized teeth with apical periodontitis. *Endod Dent Traumatol*. 1995;11:115-20. [PubMed: 7641626]
10. Weiger R, Rosendahl R, Löst C. Influence of calcium hydroxide intracanal dressings on the prognosis of teeth with endodontically induced periapical lesions. *Int Endod J* 2000;33:219-26.
11. Gupta M, Das D, Kapur R, et al. A clinical predicament--diagnosis and differential diagnosis of cutaneous facial sinus tracts of dental origin: a series of case reports. *Oral Surg Oral Med Oral Pathol Oral Radiol Endod* 2011;112:e132-6.
12. Pasternak-Júnior B, Teixeira CS, Silva-Sousa YT, Sousa-Neto MD. Diagnosis and treatment

of odontogenic cutaneous sinus tracts of endodontic origin: three case studies. *International endodontic journal*. 2009 Mar;42(3):271-6.

13. Al-Kandari AM, Al-Quound OA, Ben-Naji A, Gnanasekhar JD (1993) Cutaneous sinus tracts of dental origin to the chin and cheek. *Quintessence International* 24, 729–33.
14. Johnson BR, Remeikis NA, Van Cura JE (1999) Diagnosis and treatment of cutaneous facial sinus tracts of dental origin. *Journal of the American Dental Association* 130, 832–6.

How to cite this article: Priyanka Rudrapada, Prashanth BR, Rupali Karale, Jaishri Khed, Manjula SP. Non-surgical management of extraoral cutaneous sinus tract with odontogenic origin of mandibular incisors - a case series. *Int J Health Sci Res*. 2024; 14(5):234-241. DOI: <https://doi.org/10.52403/ijhsr.20240530>
