

# Class II Anterior Open Bite Malocclusion Treated with Fixed Functional Appliance: A Case Report

Dr. Gaurav Sharma<sup>1</sup>, Dr. Vatsal Singhvi<sup>2</sup>, Dr. Harsh Shah<sup>3</sup>, Dr. Rashmi Puri<sup>4</sup>,  
Dr. Rushali Gwalani<sup>5</sup>

<sup>1</sup>Professor and Head, Department of Orthodontics and Dentofacial Orthopedics Vyas Dental College and Hospital, Jodhpur, Rajasthan, India.

<sup>2</sup>Senior Lecturer, Department of Orthodontics and Dentofacial Orthopedics, Vyas Dental College and Hospital, Jodhpur, Rajasthan, India.

<sup>3</sup>Post-Graduate Student, Department of Orthodontics and Dentofacial Orthopedics, Vyas Dental College and Hospital, Jodhpur, Rajasthan, India.

<sup>4</sup>Reader, Department of Orthodontics and Dentofacial Orthopedics, Vyas Dental College and Hospital, Jodhpur, Rajasthan, India.

<sup>5</sup>Post-Graduate Student, Department of Orthodontics and Dentofacial Orthopedics, Vyas Dental College and Hospital, Jodhpur, Rajasthan, India.

Corresponding Author: Dr. Gaurav Sharma

DOI: <https://doi.org/10.52403/ijhsr.20240445>

## ABSTRACT

Most common properties of Class II malocclusion are mandibular retrusion, rather than maxillary prognathism. Thus, among the numerous orthodontic appliances introduced to treat Class II malocclusion functional orthopedic appliances are widely used. Fixed functional appliances can be classified into rigid and flexible. The Forsus Fatigue Resistant Device (FRD) is an alternative appliance for treating Class II malocclusion. This case report describes 18 year old female patient with the class II skeletal and dental malocclusion with anterior open bite mainly due to the habit of prolong thumb sucking. Accordingly, the treatment plan comprises of orthodontic treatment employed with fixed function appliance (Forsus device), habit breaking tongue crib and box elastics and completion of case with fixed orthodontic treatment with MBT 0.022" slot prescription to obtain a normal occlusal relationship, overjet and overbite. The case finished with a normal and a stable occlusion between the maxillary and mandibular arches with adequate width of attached gingiva.

**Keywords:** Class II Malocclusion, Open Bite, Fixed Functional, Forsus.

## INTRODUCTION

Anterior open bite may be defined as the lack of incisal contact between anterior teeth when the mandible is brought into full closure. This anomaly has distinct characteristics that have complexity of multiple etiological factors, aesthetic and functional consequences. Within this etiological context, several types of mechanics are used in open bite treatment, such as palatal crib, orthopedic forces, occlusal adjustment, orthodontic intervention using mini-implants or mini-plates, orthodontic camouflage with or without extraction and even orthognathic surgery.

Class II malocclusion is one of the most frequently observed malocclusions in orthodontics, as it affects one third of patients seeking orthodontic treatment. The open-bite deformity required more extensive intervention to ensure a satisfactory result. Most common characteristic of Class II malocclusion is retrognathic mandible, rather than prognathic maxilla. Thus,

various orthodontic appliances introduced to treat the Class II malocclusion, functional orthopedic appliances are widely used in treatment.

The most commonly used rigid fixed functional appliances are the Herbst and MARA. Most popular flexible devices are the Jasper Jumper, Eureka Spring, and the Forsus device. The Forsus Fatigue Resistant Device (FRD) is an alternative appliance for treating Class II malocclusion. A mandibular push rod attaches to the lower archwire distal to the canines, and a telescoping spring attaches to the headgear tube with an L-pin or EZ module. Forsus are unloaded when the patient's jaw opens, resulting in intrusive rather than extrusive force vectors.

## CASE PRESENTATION

An 18-year-old female patient reported to the department of orthodontics and dentofacial orthopaedics with the chief complaint of gap between upper and lower front teeth.

On intraoral examination, patient had complete set of teeth, Class II molar relation on both sides, end-on canine relation on right side and Class II canine relation on left side, overjet of 1mm, overbite of -6 mm, retroclined upper incisors and normally inclined lower incisors, spacing with 32,33 and 42,43 rotation with 14,15,24,25,35 lower dental midline shifted towards right side by 2mm(fig1,2).

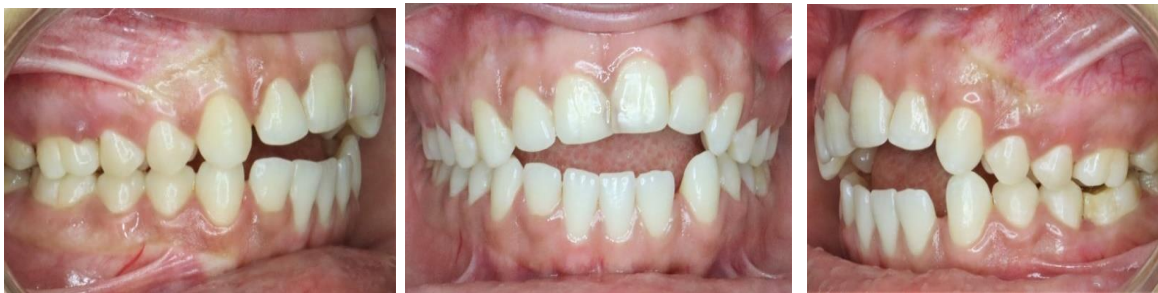

Figure 1: Pre-Treatment Intra Oral Photographs

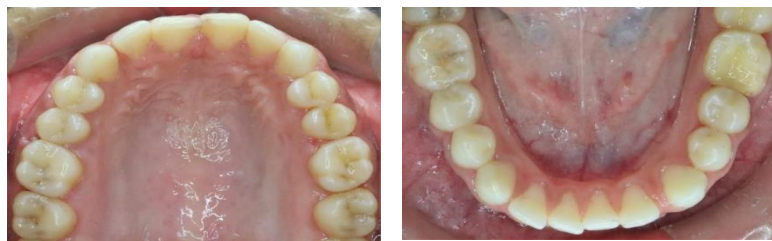

Figure 2: Pre-Treatment Occlusal Photographs

On extra-oral examination, profile examination revealed a convex profile, average nasolabial angle, average

mentolabial sulcus, and competent lips (fig 3).

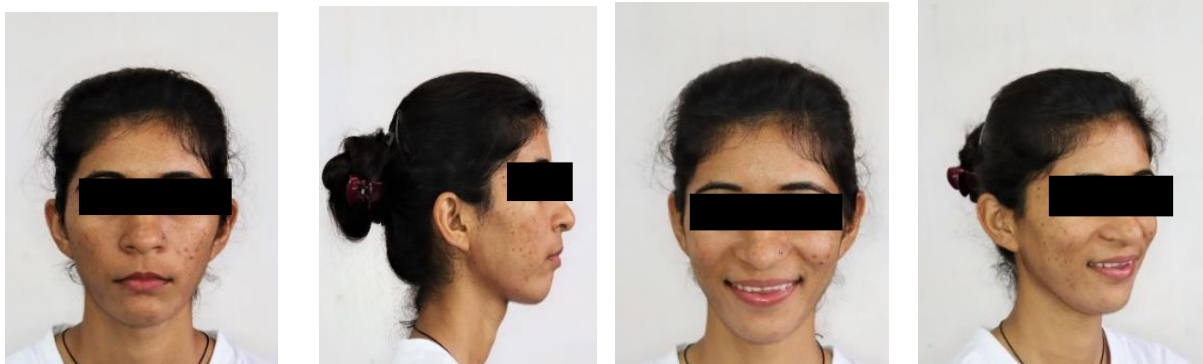

Figure 3: Pre-Treatment Extra Oral Photographs

Pre- treatment radiographs were taken and cephalometric tracing was done (fig 4). TMJ examination shows no history of pain or clicking while various jaw movements.

The right and left excursive movements were normal with a maximum mouth opening of 44 mm.

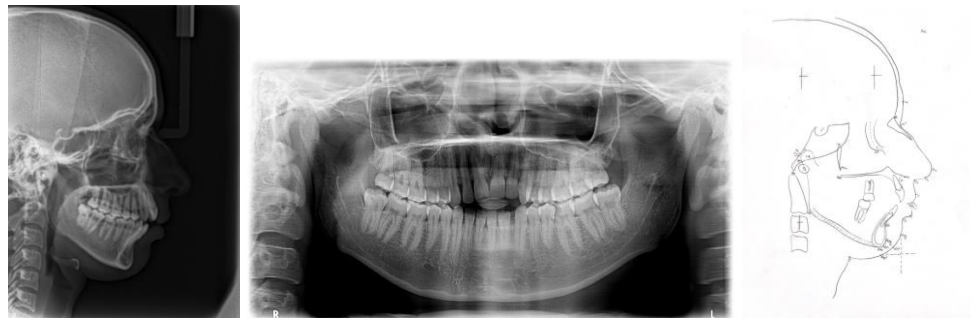

Figure 4: Pre Treatment Radiographs

### DIAGNOSIS

1. Skeletal: Class II skeletal jaw base (ANB = 10°) with anteriorly placed maxilla (SNA = 85°) and posteriorly placed mandible (SNB = 75°), and hyperdivergent growth pattern (FMA= 34°) (table 1).
2. Dental: Angle's Class II malocclusion with Class II molar relation on both sides, end-on canine relation on right side and Class II canine relation on left side, overjet of 1mm, overbite of -6 mm, retroclined upper incisors and normally inclined lower incisors, spacing with 32,33 and 42,43 rotation with 14,15,24,25,35 lower dental midline shifted towards right side by 2mm.
3. Soft tissue: Patient had convex profile, average nasolabial angle, average mentolabial sulcus, and competent lips.

### HISTORY

Patient does not give any relevant medical and dental history.

Patient gives history of thumb sucking habit.

### CEPHALOMETRY ANALYSIS

PARAMETERS	NORMAL	PRE-TREATMENT VALUE	POST-TREATMENT VALUE
SNA	(82±2°)	85°	84°
SNB	(80±2°)	75°	79°
ANB	(2±2°)	10°	5°
Wits Appraisal	(0 to 1mm)	5mm	3mm
Upper Incisor to SN	(102±2°)	94°	98°
Upper Incisor to NA	(22°, 4mm)	10°, 1mm	11°, 1mm
Lower Incisor to FH	(65°)	51°	54°
IMPA	(85-95°)	95°	99°

### PROBLEM LIST

1. Skeletal class II jaw bases with prognathic maxilla and retrognathic mandible.
2. Decreased overjet of 1mm.
3. Decreased overbite of -6mm.
4. Rotation with 14,15,24,25,35.
5. Spacing with 32,33 and 42,43.
6. Thumb sucking habit.
7. Lower dental midline shifted towards right side by 2mm.

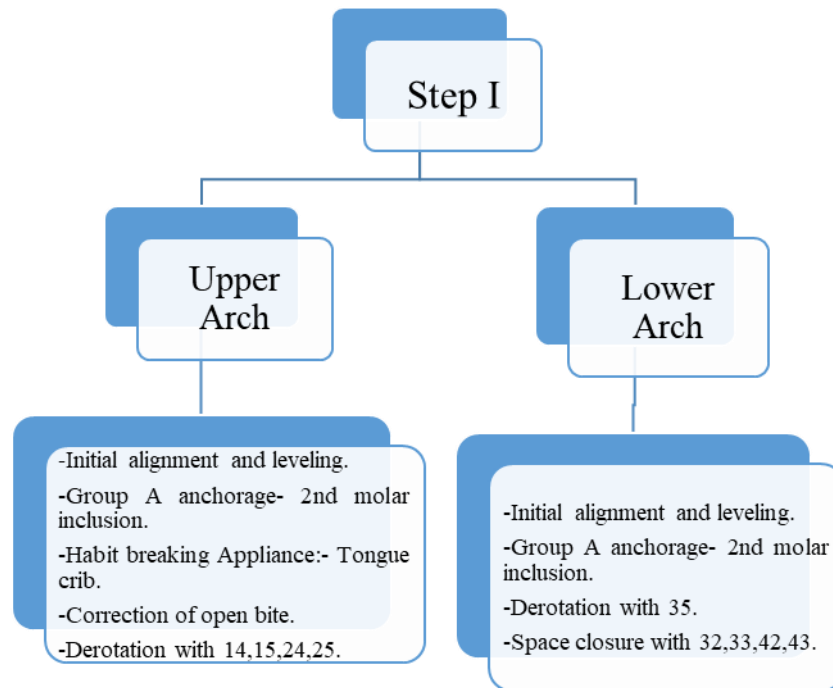
### TREATMENT OBJECTIVE

1. Correction of class II skeletal jaw bases.
2. Correction of rotation with 14,15,24,25,35.
3. Correction of spacing with 32,33 and 42,43.
4. Correction of thumb sucking habit.
5. Lower midline correction.
6. Establishment of proper occlusion.
7. To achieve aesthetic harmonious profile.
8. To maintain the stability of the result.

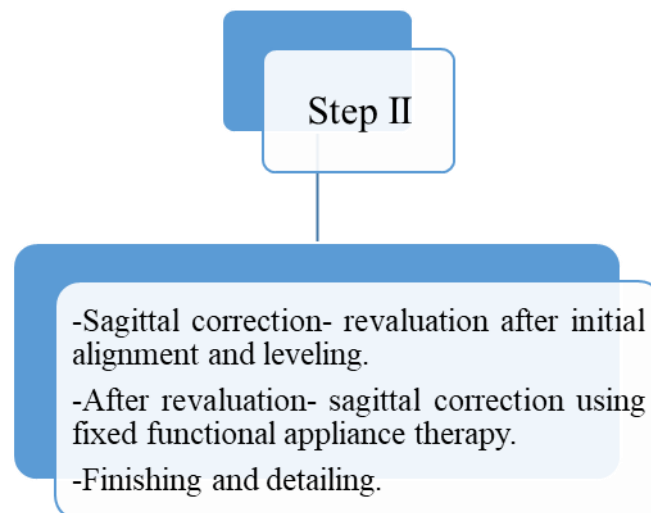
Lower Incisor to A-Pog line	(22°, 4mm)	23°, 3mm	24°, 4mm
Inter-Incisal Angle	(131°)	132°	129°
FMA	(22-28°)	34°	27°
Nasolabial Angle	(102±8°)	98°	105°
Mentolabial Angle	(122±10°)	116°	122°

Table: 1

## TREATMENT PLAN



Step 1. Pre-Fixed functional (Fixed Phase)



Step 2. Fixed functional Approach (Forsus Fatigue Appliance)

### PRE-FIXED FUNCTIONAL PHASE

A full fixed preadjusted appliance (MBT prescription with .022 slot by Ortho Organisers O2) was placed. Alignment & leveling of maxillary & mandible arches were done with: 0.014” Niti followed by 0.016” Niti, 0.016” RCS Niti with upper and

lower arch, 0.018” Niti, 0.018” S.S RCS with upper and lower arch, 0.017” × 0.025” Niti and 0.019” × 0.025” Niti. After which 0.019” × 0.025” stainless steel (SS) stabilizing wire was placed with upper and lower arch.



Upper and lower arches were coordinated and patient was asked to bring her mandible forward to look for any occlusal interference

and to recheck VTO and pre-fixed functional records were taken (fig 5).

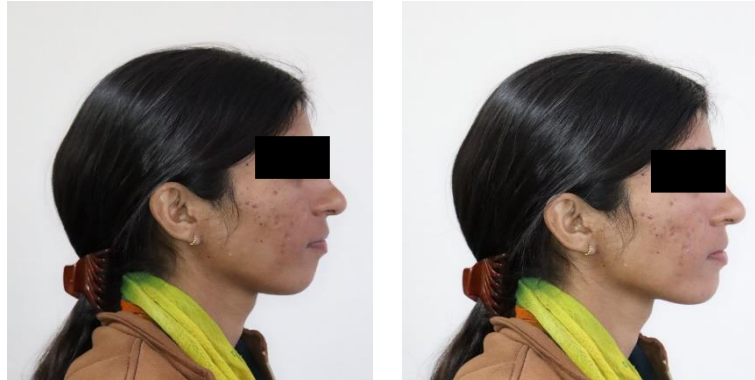

Figure 5: VTO-Visual Treatment Objectives

Before placement of forsus appliance the patient's molar relation was Class II and end on canine relation and there was increase in overjet because of the upper incisors

proclination and correction of the lower rotated teeth and space closure.(fig 6,7,8). Pre- fixed functional radiographs were taken and cephalometric tracing was done (fig 9).

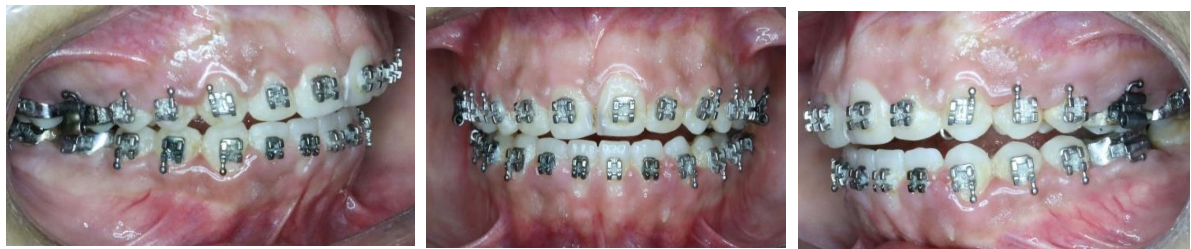

Figure 6: Pre- Fixed Functional Intra Oral Photographs

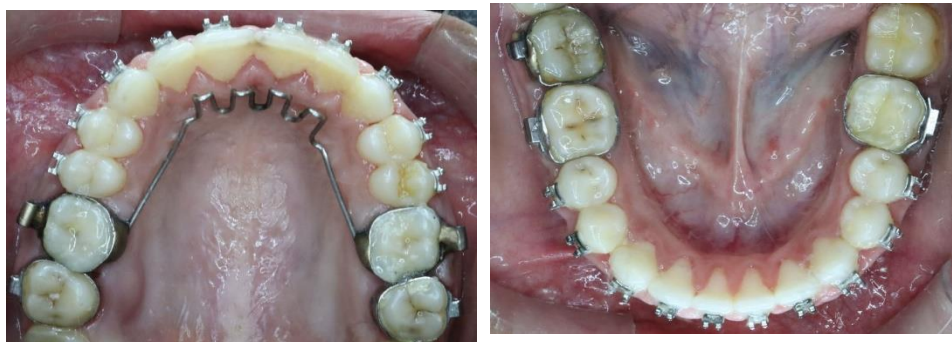
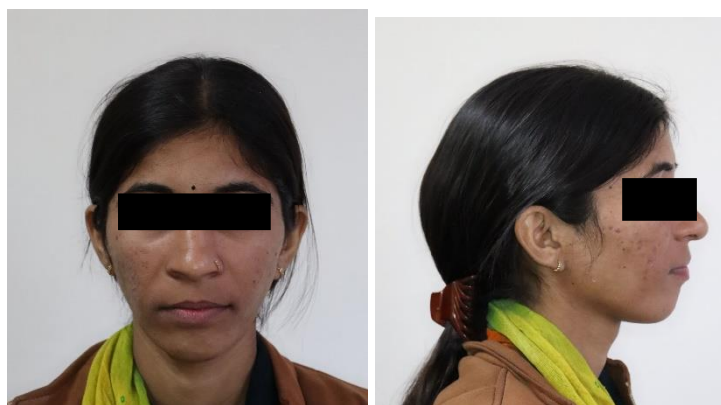
Figure 7: Pre- Fixed Functional Occlusal Photographs



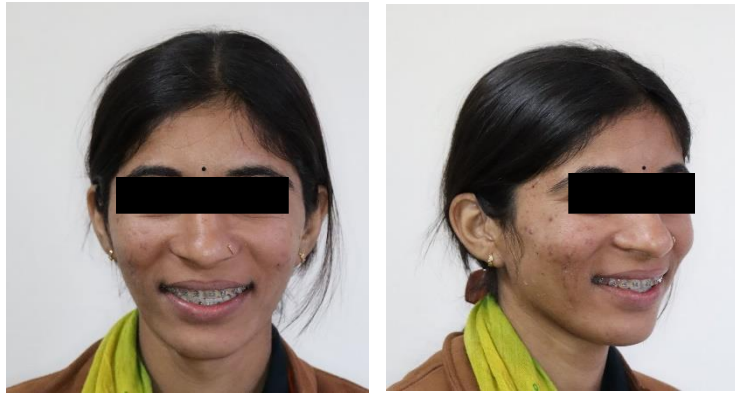

Figure 8: Pre- Fixed Functional Extra Oral Photographs

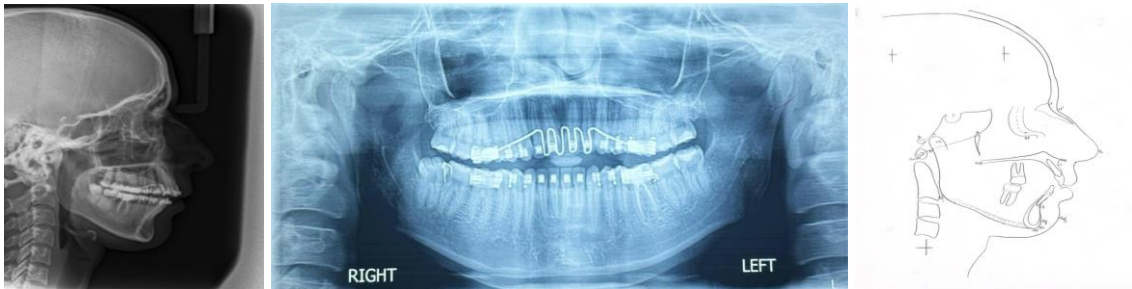

Figure 9: Pre- Fixed Functional Radiographs

#### FIXED FUNCTIONAL PHASE

In this photograph Patient is currently on stage of 0.019" x 0.025" SS in upper and lower arch. Initially the overjet was of 6 mm and with forcus (32 mm device) it reduced

to 2mm with 4mm advancement showing molar and canine in class I relation according to angles classification of malocclusion.(fig 10)

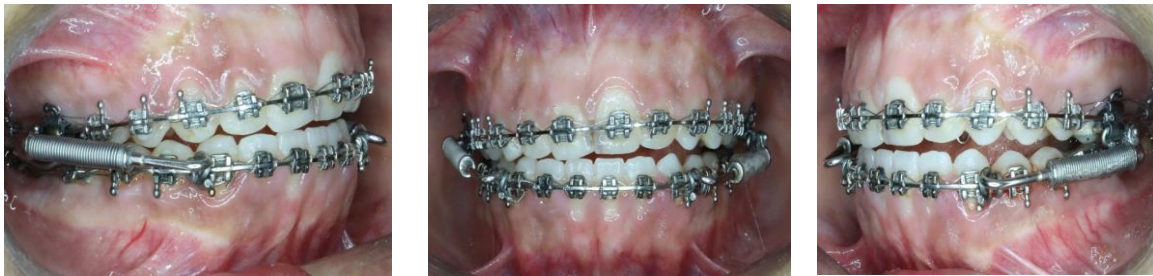
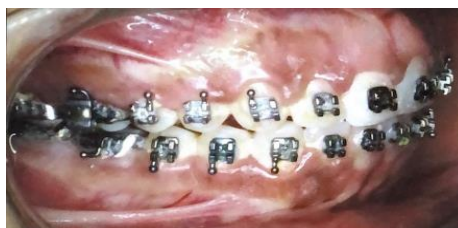
Figure 10: Forsus Insertion Intra Oral Photographs

#### POST-FIXED FUNCTIONAL PHASE

For passive intrusion of molars and extrusion of anteriors in upper and lower arch placement of 0.018 S.S AJ WILCOCK incorporated with reverse curve of spee

(RCS) respectively followed by settling box elastics in anterior region and "M" elastics in posterior region.(fig 11,12,13,14). Post-fixed functional radiographs were taken and cephalometric tracing was done (fig 15).





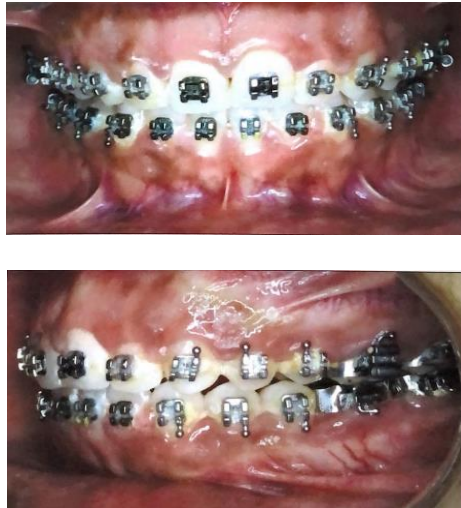

Figure 11: Post-Forsus Intra Oral Photographs

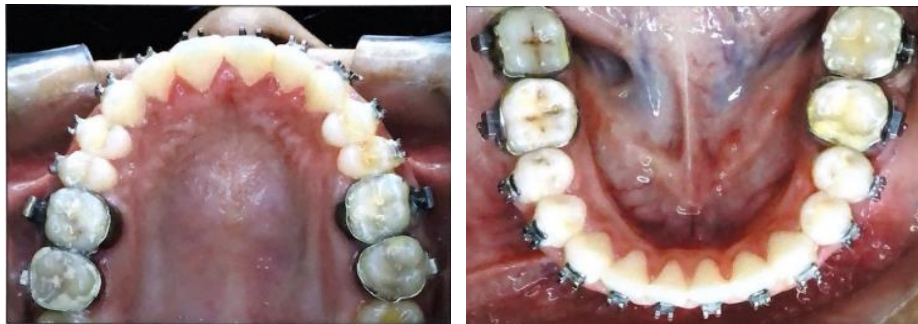

Figure 12: Post-Forsus Occlusal Photographs

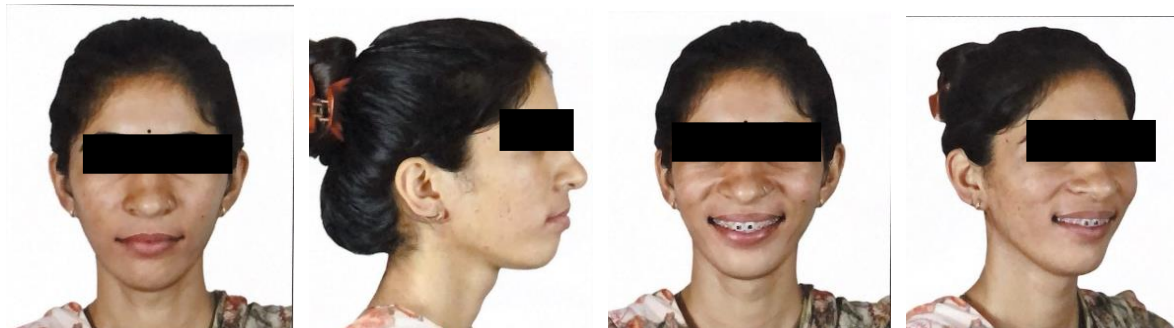

Figure 13: Post-Forsus Extra Oral Photographs

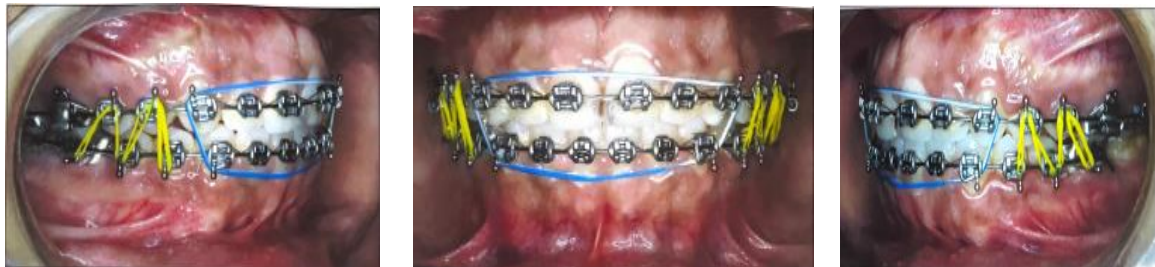

Figure 14: Settling Elastics Intra Oral Photographs

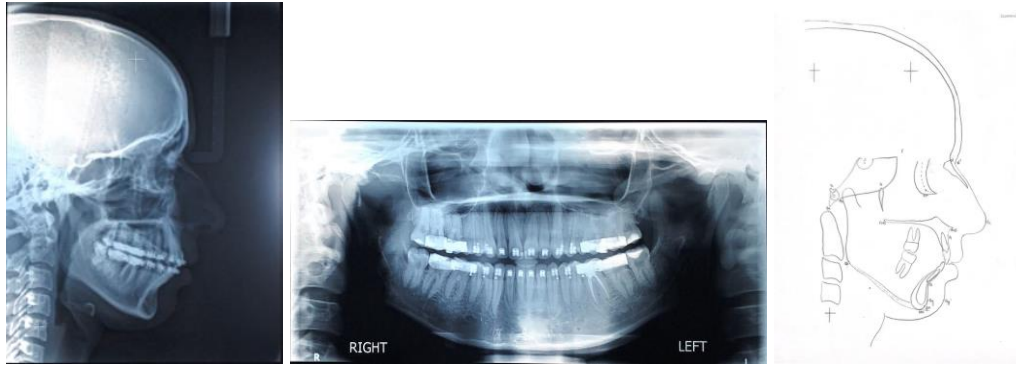


Figure 15: Post- Fixed Functional Radiographs

### RETENTION PLAN

After completion of treatment the patient was given Begg's wrap-around retainer with anterior inclined plan followed by fixed lingual retention in both maxillary and

mandibular arch to prevent relapse.(fig. 16,17,18). Post- treatment radiographs were taken and cephalometric tracing was done (fig 19).

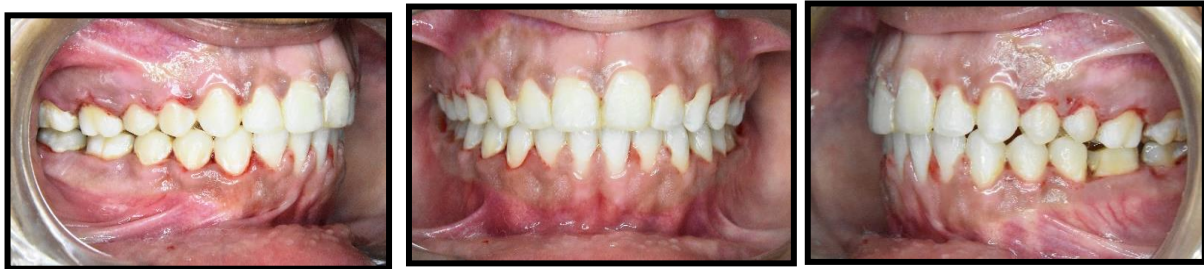

Figure 16: Post Treatment Intraoral Photographs

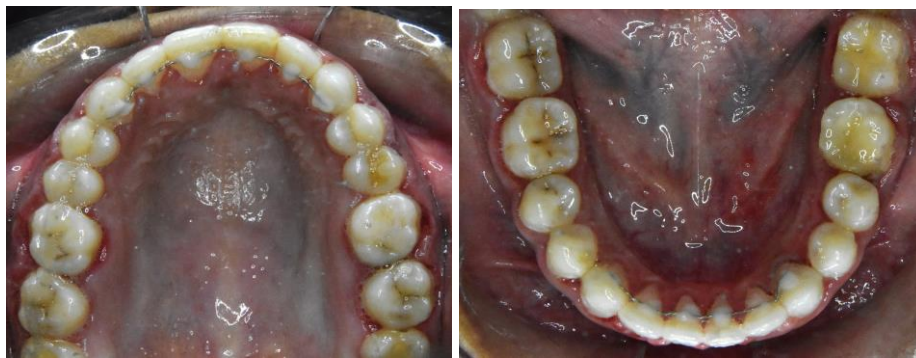

Figure 17: Post Treatment Occlusal Photographs

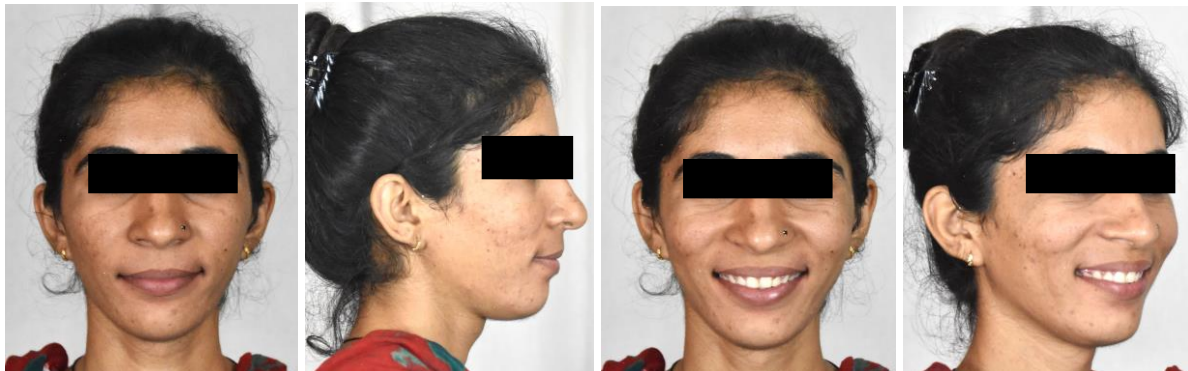

Figure 18: Post Treatment Extra Oral Photographs



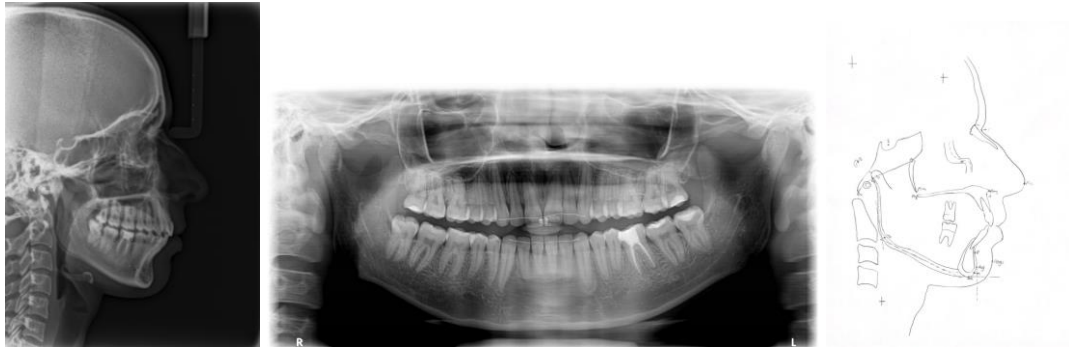


Figure 19: Post Treatment Radiographs

### TREATMENT RESULT

Evaluating with the pre-treatment records and post treatment records showcased improvement in facial profile and skeletal and dental problems were satisfied and resolved. (fig. 16,17,18) Overjet and overbite of 2mm was achieved, Angles Class I molar and canine relationship was

gained. Superimposition of Pre and Post lateral Cephalograms showed that the treatment goals and objective were achieved. (fig.20) The patient's prime concern regarding the aesthetics was satisfied. The patient was happy with the treatment outcome.

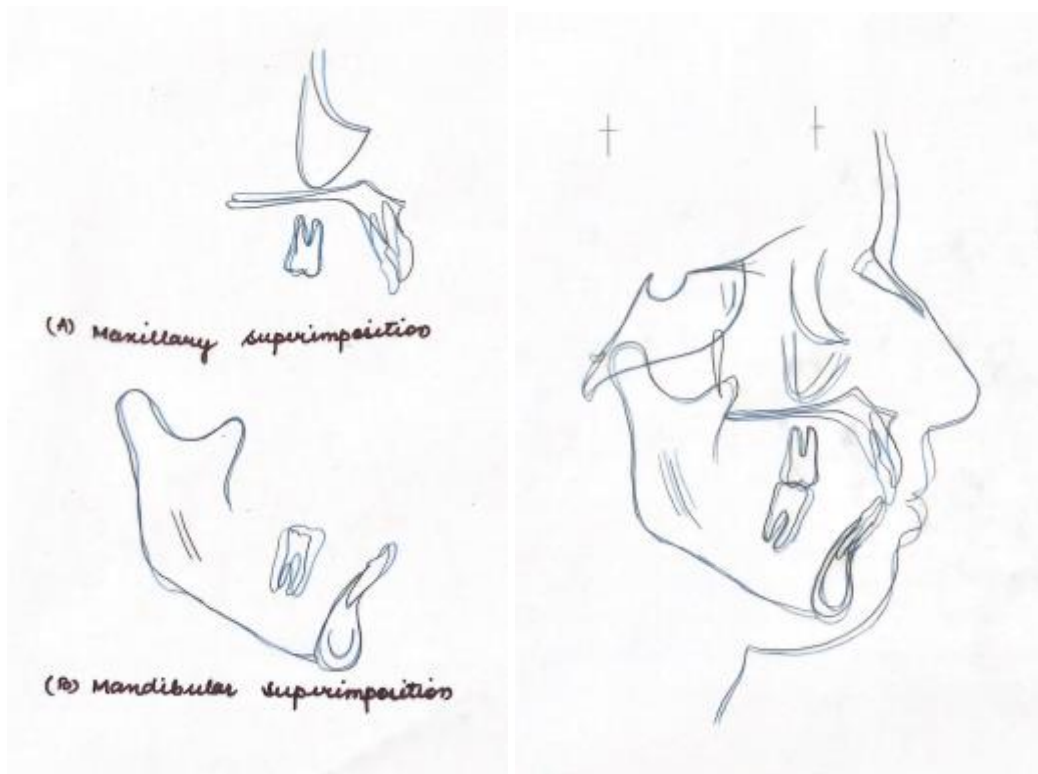


Figure 20: Superimposition of Pre and Post lateral Cephalograms

### DISCUSSION

Open bite and Class II malocclusion develops because of many etiologic factors, hereditary and environmental in nature. They are either self-correcting or respond readily to myofunctional treatment, fixed

functional mechanotherapy and orthognathic surgery.

In this case patient was non growing, during the cephalometric analysis patient showed skeletal class II deformity, retroclined upper incisors and normally inclined lower incisors (table 1). The VTO was Positive so

after Initial alignment and levelling and correction of dental Open Bite with the use of Reverse curve of spee wires, the case was re- evaluated because of the increased overjet, so to compensate with the Class II skeletal deformity FORSUS (Fixed Functional Appliance) was given. Due to auto-rotation of mandible skeletal correction was more (Table 1). Lingual torque was given to lower anteriors to avoid Proclination.

The case was completed within the 20 months. The aims of treatment objectives were accomplished, and the patient's concerns were addressed appropriately. Patient was notably pleased with the treatment outcome. Good occlusal and aesthetic results were achieved.

### CONCLUSION

- This case report presents that, fixed functional appliances have a significant role in the management of class II malocclusion due to auto rotation of the mandible, but also encouraging dento-alveolar changes once growth has completed. (fig. 16,17,18)
- Auto-Rotation of mandible and dento-alveolar correction both minimizes the necessity of extraction of permanent teeth and probably orthognathic surgery.
- With appropriate case selection and good patient cooperation, we can obtain a significant result with the Forsus Fixed appliance.

### Declaration by Authors

**Acknowledgement:** None

**Source of Funding:** None

**Conflict of Interest:** The authors declare no conflict of interest.

### REFERENCES

1. Sastri MR, Jain HA, Vakil KK, Nayak K. Management of Class II Malocclusion with Modification in Forsus Fatigue Resistance Device: A Case Report. IJSS. 2015 Jan;1(8):20.
2. Qamar Y, Maheshwari S, Pathak S. Non-Extraction Treatment of a Skeletal Class II Malocclusion Using 'Forsus' Appliance—A Case Report.
3. Ellis III E, McNamara Jr JA, Lawrence TM. Components of adult Class II open-bite malocclusion. Journal of Oral and Maxillofacial Surgery. 1985 Feb 1;43(2):92-105.
4. Hellman M. Open-bite. International Journal of Orthodontia, Oral Surgery and Radiography. 1931 May 1;17(5):421-44.
5. Alexander CD. Open bite, dental alveolar protrusion, class I malocclusion: A successful treatment result. American journal of orthodontics and dentofacial orthopedics. 1999 Nov 1;116(5):494-500.

How to cite this article: Gaurav Sharma, Vatsal Singhvi, Harsh Shah, Rashmi Puri, Rushali Gwalani. Class II anterior open bite malocclusion treated with fixed functional appliance: a case report. *Int J Health Sci Res.* 2024; 14(4):339-348. DOI: <https://doi.org/10.52403/ijhsr.20240445>

\*\*\*\*\*