

Non-Traumatic Hemothorax in a Child with Necrotizing Pneumonia: A Case Report

Bipesh Kumar Shah¹, Dheeraj Nagpal², Shankar Prasad Yadav³

¹Senior Resident, B.P. Koirala Institute of Health Sciences, Dharan, Sunsari, Nepal

²Junior Resident, B.P. Koirala Institute of Health Sciences, Dharan, Sunsari, Nepal

³Assistant Professor, B.P. Koirala Institute of Health Sciences, Dharan, Sunsari, Nepal

Corresponding author: Bipesh Kumar Shah

DOI: <https://doi.org/10.52403/ijhsr.20240127>

ABSTRACT

Acute necrotizing pneumonia has challenges in diagnosis and management involving a multidisciplinary team approach; pediatric medicine and surgery. The initiation and timely upgradation of antibiotics with drainage of collection (pus, blood) is the key to better outcomes. The imaging study should not be delayed for the diagnosis and to rule out other cavitory lesions. The virulence nature of staphylococcus aureus and streptococcus pneumonia makes them common aetiological agents. We present a case of a child who initially had symptoms of severe pneumonia, and later on was found to have hemothorax which improved with broad-spectrum antibiotics and chest tube drainage.

Keywords: child, hemothorax, pneumonia

INTRODUCTION

Acute necrotizing pneumonia is an uncommon entity leading to rapid destruction of lung parenchyma which pneumothorax, hemothorax, empyema, or bronchopleural fistula often complicate.¹ It is associated with high mortality as the intrapulmonary vessels are thrombosed leading to lung necrosis and abscess with poor penetration of antimicrobial therapy.² The causative organisms can be bacterial (Streptococcus pneumonia, Staphylococcus aureus, Klebsiella pneumoniae, Mycoplasma Pneumonia), viral (Influenza, Parainfluenza, Respiratory syncytial), and fungal (Aspergillus, candida, Histoplasma) with co-infection serving as a risk factor.³ Necrotizing pneumonia in children with hemothorax is less common and no such case from Nepal has been reported.

CASE REPORT

A previously healthy, immunized seven-year-old female presented with fever, cough, and respiratory distress in the form of tachypnea (50 breaths/min), oxygen saturation of 80% in room air, and suprasternal retraction requiring oxygen by face mask with reservoir. She was started on Ceftriaxone, vancomycin, and Azithromycin, intravenous fluids, and antipyretics. The chest x-ray showed left-sided effusion with minimal infiltrates on the right middle zone (figure 1). A pleural tap (figure 2) revealed red blood cells of 1050/cu mm, a total leukocyte of 80/cu mm, and ADA (Adenosine deaminase) of 29.50 U/L with normal glucose and protein, suggesting hemothorax (figure). The chest tube of size 24 was placed and 250 ml of blood in the pleural space was drained from the left hemithorax. The Hemogram showed anemia of 9. gm/dl, normal white

blood cells (7760/cu mm) and platelets (2.46 lacs/cu mm), prothrombin time and activated thromboplastin time were within normal range. Human immunodeficiency virus, hepatitis B, and C serologies were negative. In view of persisting distress, a CECT (contrast-enhanced computed tomography) chest was done which showed consolidation in the lower and middle

zone of the left lung suggesting necrotizing pneumonia (figure 3). The antibiotics were upgraded to piperacillin-tazobactam, linezolid, and cefepime. There was a symptomatic improvement in the form of a reduction in the number of fever spikes, and respiratory support requirement with tube drain decreased to 30-50 ml gradually over 10 days.

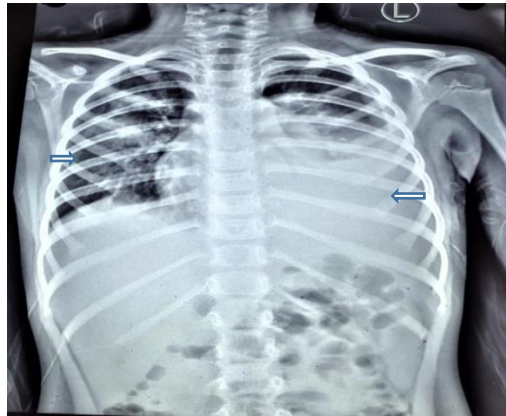


Figure 1: Chest x-ray showing left-sided opacity (hemothorax) with right middle zone infiltrates



Figure 2: Blood clots with serum drained from left pleural cavity

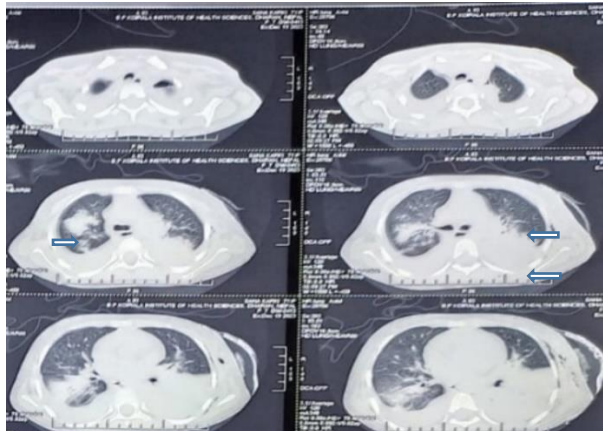


Figure 3: CT chest showing right middle zone opacity and left-sided opacity (hemothorax)

DISCUSSION

There is difficulty in differentiating consolidation and necrotizing pneumonia by chest radiograph initially as fluid-filled cavity in necrotizing pneumonia has same density as consolidation.⁴ The CT chest is required for early diagnosis of necrotizing pneumonia and also in ruling out other cavitory lesions like lung abscess, and aspergilloma. The PVL (Panton-valentine leukocidin) is the major cytotoxin involved in the pathogenesis of necrotizing pneumonia which causes tissue necrosis and destruction of leukocytes.

In a retrospective cohort study by Sharma et al, almost all cases of 272 patients with pneumonia had respiratory distress, two-thirds required inotropes and mechanical ventilation, only 6 cases had pneumothorax and pleural effusion and 2 cases developed bronchopleural fistula whereas no cases had hemothorax unlike our case. Staphylococcus aureus was the most common organism isolated in 40% of cases.⁵

The retrospective analysis by Manette et al in 2016 showed half of the patients with necrotizing pneumonia required chest tube drainage, while 6% required video-assisted thoracoscopic surgery.⁶ The most common organism identified in this study was streptococcus pneumonia (12.6%) followed by staphylococcus aureus (9.2%) which couldn't be isolated in our case which can be explained by upfront administration of antibiotics before admission.

The median age of children with necrotizing pneumonia was 3.2 years in an observational study conducted by Blanco-Iglesias et al where 49 of 51 patients presented with pleural effusion, the causative agent was isolated in two-thirds of cases and pneumococcus was the commonest. The surgical intervention was required in 3 cases in contrast to our case where child was managed with broad-spectrum antibiotics and tube thoracostomy alone.⁷

CONCLUSION

The management of necrotizing pneumonia is challenging in children and requires close respiratory and hemodynamic monitoring, broad-spectrum antibiotics with drainage of blood or empyema if any, and nutritional support. There is a need for multi-centre study on pediatric necrotizing pneumonia to formulate standard guidelines.

Declaration by Authors

Acknowledgement: A gratitude towards my family and staffs at the hospital.

Source of Funding: None

Conflict of Interest: The authors declare no conflict of interest.

REFERENCES

1. Masters IB, Isles AF, Grimwood K. Necrotizing pneumonia: an emerging problem in children? *Pneumonia*. 2017 Dec;9(1):11. doi: 10.1186/s41479-017-0035-0
2. Chatha N, Fortin D, Bosma KJ. Management of Necrotizing Pneumonia and Pulmonary Gangrene: A Case Series and Review of the Literature. *Can Respir J*. 2014;21(4):239–45. doi: 10.1093/tropej/fmaa027
3. Chen Y, Li L, Wang C, Zhang Y, Zhou Y. Necrotizing Pneumonia in Children: Early Recognition and Management. *J Clin Med*. 2023 Mar 14;12(6):2256. doi: 10.3390/jcm12062256
4. Ramgopal S, Ivan Y, Medsinghe A, Saladino RA. Pediatric Necrotizing Pneumonia: A Case Report and Review of the Literature. *Pediatr Emerg Care*. 2017 Feb;33(2):112–5. Doi: 10.1097/PEC.0000000000000585
5. Sharma PK, Vinayak N, Aggarwal GK, Srivastava RD, Aggarwal PK, Kushwaha AS. Severe Necrotizing Pneumonia in Children: A Challenge to Intensive Care Specialist. *J Trop Pediatr*. 2020 Dec 1;66(6):637–44. doi: 10.1093/tropej/fmaa027
6. Ness-Cochinwala M, Kobaitri K, Totapally BR. Characteristics and Outcomes of Children With Necrotizing Pneumonia. *Pediatr Crit Care Med*. 2021 Dec;22(12):e640–3. doi: 10.1097/PCC.0000000000002793

7. Blanco-Iglesias E, Oñoro G, Almodovar-Martín JL, García-Salido A, De Lama Caro-Patón G, Martínez De Azagra-Garde A, et al. Retrospective Study in Children with Necrotizing Pneumonia: Nine Years of Intensive Care Experience. *Pediatr Infect Dis J.* 2020 Jul;39(7):571–5. doi: 10.1097/INF.0000000000002633

How to cite this article: Bipesh Kumar Shah, Dheeraj Nagpal, Shankar Prasad Yadav. Non-Traumatic hemothorax in a child with necrotizing pneumonia: a case report. *Int J Health Sci Res.* 2024; 14(1):222-225.
DOI: <https://doi.org/10.52403/ijhsr.20240127>
