

Traumatic Scalp Myiasis in a Patient with Schizophrenia: A Rare Case Presentation

Dr Shradha Singh¹, Dr K. Geetha²

¹Senior Resident at All India Institute of Medical Sciences, Raebareli

²HOD & Associate Professor at All India Institute of Medical Sciences, Raebareli

Corresponding Author: Dr Shradha Singh

DOI: <https://doi.org/10.52403/ijhsr.20240113>

ABSTRACT

Traumatic myiasis or the invasion of live tissues by fly larvae, is a rare presentation in a healthy human being. It is an infestation caused by dipteran larvae, which feed on the host's necrotic tissue by entering neglected open wounds, which serves as a good source of nutrition. Psychiatric illness leads to physical inability to maintain good hygiene and promotes deposition of ova from the flies. We hereby report a case of severe scalp myiasis in a 32 year old female from a rural area of Raebareli, Uttar Pradesh. Illiteracy and ignorance to health care are key factors and should be vital in raising awareness in public health care and avoiding such rare complication.

Keywords: Traumatic Myiasis, Schizophrenia, public health

INTRODUCTION

The Greek word "myia," which means "fly," is where the name "myiasis" comes from. It describes the invasion of living vertebrate bodily tissues by Dipteran (maggot) larvae. (1). Although it is more frequently observed in animals, the syndrome can also occur in humans on occasion.(2) Ideal humidity and temperature, which allow the flies to breed, are present during this time, myiasis cases are more common in India from June to November. (3) Putrid discharges from sick tissues typically increase oviposition. Adenocarcinoma necrotic lesions, squamous cell carcinoma, diabetic patients' wounds, trauma, and surgical wounds are some other significant variables that predispose people to developing human myiasis. Additionally, it has been shown that patients with mental retardation or comatose states who are compromised are particularly vulnerable to myiasis (4). Table 1 briefly categorises myiasis on the basis of cutaneous manifestations and infesting species larvae.(5)

TABLES:

Table 1: Classification of myiasis on the basis of cutaneous manifestations and infesting species larvae.

Cutaneous manifestation	Species
Furuncular Myiasis	Dermatobia hominis
	Cordylobia
	Cuterebra species
	Wohlfahrtia vigil & Wohlfahrt opaca
Migratory Myiasis	Gasterophilus intestinal
	Hypodermic bovis & H. Lineatum
Wound Myiasis	Cochliomyia homnivorax
	Chrysomya bezziana
	Wohlfahrtia magnifier

CASE REPORT

A 32-year-old female from a rural district was brought to the emergency department with complaints of recurrent episodes of hallucination and self-mutilation. On enquiring with the family members, it was learned that the patient had suffered from these symptoms since last 10 years with an exacerbation in the symptoms since last 7 months.

On physical examination a longitudinal lacerated wound (approximately 4 cm) with

erythematous edges and greenish yellow discharge along with foul smell was noticed over the scalp (Fig1a& b). The manner of the injury was unknown to the relatives, which they perceived was because of self-mutilation. The duration of the inflicted wound was stated around 3-4 weeks. The wound was left open and no medical care was sought due to negligence and low socio-economic status.

On careful examination the wound was filled with numerous crawling fly larvae (maggots) with the depth extending till the skull bone. The haematological examination was normal and the patient was afebrile. However, the

blood sugar was slightly raised. MRI showed no intracranial extension or osteomyelitic changes (Fig2). After applying turpentine liniment, approximately 40 larvae were removed from the wound. Surgical debridement and daily dressing of the open wound was advised and a prophylactic course of antibiotics was started for two weeks. Unfortunately, the morphology and the species of the maggot could not be identified. The patients' relatives were educated regarding scalp care and personal hygiene. She was asked to come for review every 2 weeks at the dermatology outpatient clinic.

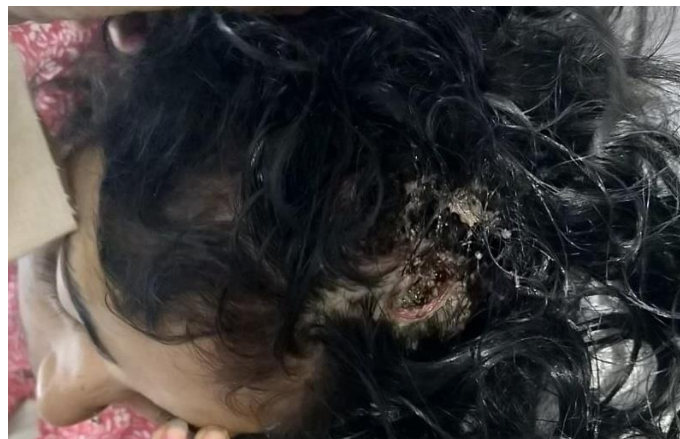

Fig. 1a&b)-shows lacerated scalp wound infested with multiple larvae.

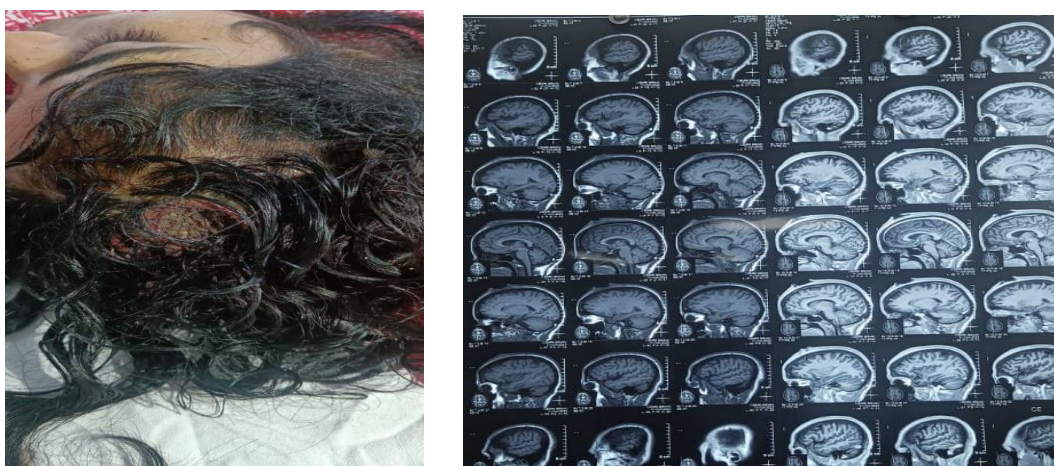


Fig. 2) shows MRI shows lacerated wound with normal brain parenchyma. FIG1b)

DISCUSSION

The *C. bezziana* larvae can infect a variety of mammals, both domesticated and wild, through wounds. In Africa, India, and the

Arabian Peninsula, the fly had been deemed a nuisance to domesticated livestock. Fly larvae typically infest people when conditions on the host are favourable for

larval growth, such as untreated wounds and bodily apertures that have an unpleasant odour.(6)

Because they are necessary parasites, the larvae cannot grow in decaying or dead organic substances. As a result, the fly must parasitize living creatures to complete its larval stage. Since the ideal humidity and temperature, which allow the flies to breed, are present during this time, myiasis cases are more common in India from June to November. (3)

The current study is a result of grossly neglected hygiene and public ignorance which causes myiasis. Keeping wounds clean and covered as well as managing fly populations are some of the most effective ways to prevent human myiasis in third-world nations. In the current case, the patient had a highly infected, pus-filled wound on her scalp that had developed a week prior to seeking medical assistance and had been completely disregarded and left exposed. Additionally, the patient's hygiene was not adequate as was suggested from matted hair and foul smell attributed mostly towards her low socioeconomic conditions and her ignorant behaviour owing to her mental illness.

Chrysomya bezziana being an obligatory parasite feed on living tissues. Their eggs moult into larvae within a few hours and in a few cases might penetrate deeper into tissues by invading the pericranium. The management by standard practices involves urgent removal of larvae followed by debridement of the infected wound. Most effective and commonly used technique is the application of suffocating agents like turpentine oil, petroleum jelly, 15 %chloroform, which kills the larvae and forces them to come out of the wound. Anti parasitic drugs like Ivermectin should be cautiously used as they can cause an inflammatory reaction because of clearing and killing up of larvae. A course of prophylactic antibiotics is usually given to

the patient to combat any secondary infection.

CONCLUSION

Public education about traumatic myiasis hazards and appropriate wound treatment is crucial, especially in rural regions. A long-term, untreated open wound creates an ideal environment for oviposition. The primary causes of myiasis in the above case report include poor living conditions in rural areas, mental illness leading to ignorant health seeking behaviour and restricted access to healthcare facilities.

Declaration by Authors

Acknowledgement: A heartfelt gratitude to my parents and my faculty for their support.

Source of Funding: None

Conflict of Interest: The authors declare no conflict of interest.

REFERENCES

1. cdc.gov/parasites/myiasis. Atlanta, GA: Centers for Disease Control and Prevention;
2. Singh, A., Singh, Z. Incidence of myiasis among humans—a review. *Parasitol Res* 114, 3183–3199 (2015).
3. Singh A, Singh D. Traumatic Myiasis of the Scalp in a 3-year-old Patient- A Case of Neglected Health Care. *Mal J Med Health Sci* 15(1): 89-91, Jan 2019
4. Singh A, Singh Z. Incidence of myiasis among humans- a review. *Parasitol. Res.*, 2015; 114: (9), 3183–3199. doi: 10.1007/s00436-015-4620-y.
5. McGraw TA, Turiansky GW. Cutaneous myiasis. *J Am Acad Dermatol.* 2008; 58:907–26
6. Spradbery JP. Screw-worm fly: A tale of two species. *Agri. Zool. Rev.*,1994; 6: 1-62

How to cite this article: Shradha Singh, K. Geetha. Traumatic scalp myiasis in a patient with schizophrenia: a rare case presentation. *Int J Health Sci Res.* 2024; 14(1):102-104. DOI: <https://doi.org/10.52403/ijhsr.20240113>
