

Evaluation of Point of Care Ultrasound as a Diagnostic Tool for the Diagnosis of Pneumonia in Emergency Department

Ganesha BS¹, Anup Banur², Mahesh Krishnamurthy³, Narendra SS⁴

¹Department of Emergency Medicine, Vydehi Institute of Medical Sciences and Research Center, Bangalore, India

²Department of Respiratory Medicine, SS Institute of Medical Sciences, Davanagere, Karnataka, India

³Department of Emergency Medicine, Institute of Gastroenterology & Organ Transplantation, Bangalore, India

⁴Department of Emergency Medicine, SS Institute of Medical Sciences, Davanagere, Karnataka, India

Corresponding Author: Ganesha BS

DOI: <https://doi.org/10.52403/ijhsr.20230828>

ABSTRACT

Introduction: Community-acquired pneumonia (CAP) is a common condition associated with significant morbidity and mortality worldwide. Bedside lung ultrasound has become an essential tool for the diagnosis of pleural effusions, thoracentesis and biopsy-guided procedures; however, it has recently been shown to be highly effective in evaluating pulmonary conditions such as pneumonia and pneumothorax.

Objectives: To investigate the utility of point of care ultrasound (POCUS) for the diagnosis of community-acquired pneumonia (CAP) in patients presenting to the Emergency Department (ED).

Methodology: This was a hospital based prospective observational study. 50 patients above the age of 18 years presenting to the emergency department with clinical suspicion of pneumonia were evaluated by chest x-ray, bedside lung ultrasound using portable ultrasound machine. Patients with inconclusive results underwent chest CT.

The sensitivity, specificity and accuracy of ultrasonography were compared with the chest X-ray.

Results: In our study, sensitivity of point of care ultrasound in diagnosing pneumonia was 89.13% whereas that of chest x-ray - 73.91%. The Negative Predicted value of ultrasound was 44.4% and chest x-ray had a negative predicted value 25%.

Conclusion: POCUS is a reliable tool for evaluation of lung parenchymal pathologies in the emergency department and is probably superior to bedside CXR as it may help emergency physicians in faster diagnosis and early initiation of appropriate treatment.

Keywords: POCUS, Community Acquired Pneumonia

INTRODUCTION

Community-acquired pneumonia (CAP) is a common condition associated with significant morbidity and mortality worldwide. The annual incidence of CAP varies from 5 to 11/1000 population with a higher incidence in the elderly. Around 20% of patients with CAP require hospitalization incurring significant economic burden on the society.¹

Chest radiography (CXR) is routinely recommended for the evaluation of patients with suspected CAP². The interpretation of CXR has high inter-observer variability among radiologists. The accuracy of chest x ray for the diagnosis of pneumonia is 65% when compared with computerised tomography (CT)³.

CT thorax is a very important tool for the diagnosis of pneumonia, but it has

limitations like unavailability, high radiation exposure, and it may not always be feasible in critically ill patients in the emergency department. Bedside ultrasonography (BUS) is increasingly being used as a valuable bedside method for the diagnosis of various thoracic conditions, including pleural or pericardial effusion, empyema, pneumothorax, pulmonary embolism and pneumonia⁴.

Lung ultrasound has become an essential tool for the diagnosis of pleural effusions, thoracentesis and biopsy-guided procedures; however, it has recently been shown to be highly effective in evaluating pulmonary conditions such as pneumonia and pneumothorax⁵.

The key to ultrasound visualization of pneumonia in the lungs is relative loss of aeration of a portion of the lung and a concomitant increase in the fluid content, which is seen in lung consolidation. Once this consolidation reaches the pleura, it can be seen with ultrasound. Current literature suggests that most pneumonias in critically ill patients (up to 98%) will contact the pleura⁶.

Till date, there are only a few studies which have investigated the role of point of care ultrasonography (POCUS) in the diagnosis of pneumonia in the emergency department (ED) or intensive care unit^{7,8}.

Objective:

The aim of this study was to investigate the utility of point of care ultrasound (POCUS) for the diagnosis of community-acquired pneumonia (CAP) in patients presenting to the emergency department (ED)

MATERIALS & METHODS

The study design was a hospital based prospective observational study. Adult patients presenting to the emergency room of SSIMS & RC with symptoms of fever, cough, and dyspnea were screened for the study. The study was conducted during December 2014 to May 2016.

Children (<16 years old), pregnant women, and patients who presented with other

respiratory illnesses like pulmonary tuberculosis, interstitial lung disease, malignancy were excluded from the study.

Ethical clearance was obtained for the study from internal ethical committee of the institute (S.S. Institute of Medical Sciences & Research Centre, Davanagere, Karnataka) prior to the commencement of the study. Of the screened patients, 50 patients were included for the study after obtaining informed consent.

Point of care ultrasound (POCUS) was carried out using portable ultrasound machine from GE healthcare, LOGIQ e. A curvilinear probe 4C-RS type 2- to 5.5-MHz and a linear probe 12L-RS type 5-13 MHz were used during the study.

Chest x ray (CXR) was performed in all patients after POCUS was completed to reduce the bias. Patients with inconclusive results underwent chest CT.

At bedside, the probe was set perpendicular, oblique, and parallel to the ribs in the anterior, lateral, and posterior (lower and upper) thorax. Sitting position and lateral decubitus were used to scan the posterior chest wall.

Each hemithorax was divided into 5 areas: 2 anterior, 2 lateral, and 1 posterior.

Anterior chest wall was marked off from parasternal line to anterior axillary line. This zone was split into an upper region (from collar bone to the second-third intercostal space) and a lower region (from the third intercostal space to diaphragm).

Lateral area from the anterior to the posterior axillary line, was divided into upper and lower halves.

Posterior zone was identified from the posterior axillary line to the paravertebral line.

The superficial layers of the thorax consist of subcutaneous tissue and muscles. The ribs, on longitudinal scan, appear as curvilinear structures associated with posterior acoustic shadowing.

In cases of healthy lungs, the ultrasound shows echoic pleural line, between two rib shadows, and its sliding with breathing. The aerated lungs prevent any visualisation

beyond this line. The wide acoustic impedance between the pleura and underlying aerated parenchyma creates typical horizontal artifacts defined as ‘A lines’⁹.

In the lung, vertical artifacts moving with lung sliding arise from the pleural line, reach the edge of the screen and erase A lines¹⁰. These vertical artifacts are called ‘B lines’ and are defined as an interstitial syndrome when exceeding three per longitudinal scan area. B lines correlate with extravascular lung water and with tomographic images of pulmonary edema¹¹. Interstitial syndrome may be focal (pneumonia, lung contusion) or diffuse (cardiogenic pulmonary oedema, acute lung injury (ALI)/acute respiratory distress syndrome (ARDS), pulmonary fibrosis);

history and clinical data, as well as the ultrasound pattern, can help in the differential diagnosis. In our study, the diagnosis of pneumonia was made in the presence of subpleural lung consolidation with tissular pattern. These consolidations could either contain dynamic air bronchograms (branching echogenic structures with centrifuge movement with breathing) or multiple hyperechogenic spots (air trapped in the small airway)¹². The presence of dynamic bronchogram does help in ruling out obstructive atelectasis¹³. The presence of focal interstitial syndrome was considered as indicative of pneumonia. Based on the ability of patients to stay upright, CXR was obtained in the supine or seated antero posterior view, or in the upright posterior anterior and lateral views.

Most Common Ultrasound Findings Associated with Pneumonia

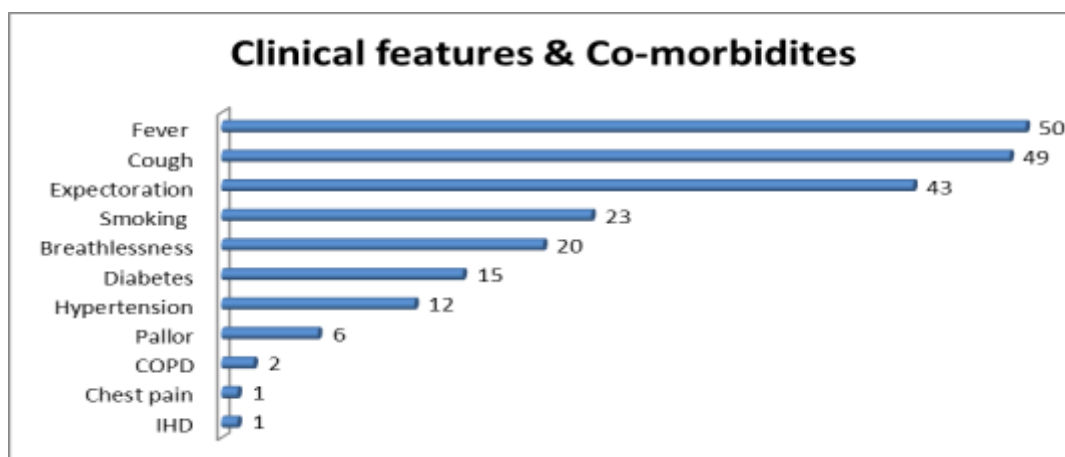
Hypoechoic areas of varying size and shape
Irregular and serrated margins
Heterogeneous echotexture
Air bronchograms
Dynamic air bronchograms
Pleural effusion
Vascular flow in consolidated lung on colour or power Doppler imaging
Hepatization of lung tissue similar to appearance of the liver

STATISTICAL ANALYSIS

The sensitivity, specificity, accuracy, positive predictive value, and negative predictive values of POCUS were calculated and analysed using SPSS version 15.0 ® (SPSS, Inc., Chicago, USA).

In our study, 50 patients were enrolled. Most of the patients were aged between 20 to 50 years and mean age was found to be 44.8 ± 6.2 years. 29 (58%) patients were males and 21 (42%) were females. Clinical features and comorbidities are outlined in graph 1.

RESULT



In our study, fever was the most common presenting complaint (100%), followed by cough (98%). Breathlessness was found in 40% patients. Diabetes was the most common co morbidity (30% of patients) and 24% of patients were found to have hypertension. Tachypnoea was present in all cases (100%) and most patients had respiratory rate between 20-30 breaths per minute, 34% patients had oxygen saturation of below 90% at presentation to ED and 56% had oxygen saturation between 90-95%.

Tracheal position was central in 94% patients, and deviated to left in 4% and towards right in 2% patients. Chest movements were symmetrical in 92% patients. Accessory muscle usage was found in 12% of patients and resonant note on percussion was found in 80% patients. 92% patients had bilateral equal air entry and on auscultation, crepitations were found in 98% patients and rhonchi in 52% patients. The results of CXR and lung ultrasound compared with the diagnosis at discharge are summarised in table 1.

Table 1: Comparison of CXR and lung ultrasound

		PNEUMONIA + (46)	PNEUMONIA -(04)
CXR	Positive	34	0
	Negative	12	0
Lung Ultrasound	Positive	41	0
	Negative	05	0

We considered discharge diagnosis as the reference standard. Pneumonia as final diagnosis was confirmed in 46 out of 50 patients. Bedside lung ultrasound showed a sensitivity of 89.13% (41/46 patients; 95% CI and a specificity of 100% (04/04 patients). The positive predictive value was 100%, and the negative predictive value was 44.44%. The false negative was a patient with both initial pulmonary oedema and pneumonia, for whom lung ultrasound showed only an alveolar interstitial syndrome. The patient was treated with diuretics, vasodilators and antibiotics with an excellent outcome. Chest radiography had a sensitivity of 67% (54/81; 95% CI 56.4% to 76.9%) and a specificity of 85% (33/39; 95% CI 73.3% to 95.9%). The positive likelihood ratio was 4.3 (95% CI 2.04 to 37.7), the negative likelihood ratio was 0.39 (95% CI 0.20 to 0.76).

Among 27 patients with a first non-diagnostic radiogram, a second CXR was performed within 72 hours in 17 cases and was diagnostic for pneumonia in 10 (total positive CXR in patients with pneumonia at discharge: 64/81). In seven patients with a repeatedly non-diagnostic CXR, pneumonia was diagnosed with a CT scan. (Table 2)

Table 2: Sensitivity, Specificity, Positive Predicted value and Negative Predicted value of POCUS and Chest X-ray

	POCUS	Chest X ray
Sensitivity	89.13%	73.91%
Specificity	100.00%	100.00%
Positive Predicted value	100.00%	100.00%
Negative Predicted value	44.44%	25.00%
Accuracy	90.00%	76.00%

DISCUSSION

In our study, mean age of the study population was 44.8 ± 6.2 years which suggests that our study population comprised a relatively younger population compared to the usual age group of patients with Community acquired pneumonia. In the study by Cortellaro F et al¹⁴, mean age was 69 ± 18 years. In our study, 29 (58%) patients were males and 21 (42%) were females, similar to Cortellaro F et al¹⁴ who had 64% males in their study population.

We found that sensitivity of POCUS in diagnosing pneumonia was 89.13% while that of conventional chest radiography was 73.91%. In a study by EE Unluer et al¹⁵, sensitivity of bedside ultrasound for the diagnosis of pneumonia was 96.4%, but there was no comparison between the sensitivity of chest x ray and ultrasound in

their study. Cortellaro F et al¹⁴ studied 120 patients and reported that sensitivity of ultrasound was 98%, whereas that of chest radiography was 68%.

The accuracy of POCUS for the diagnosis of pneumonia in our study was 90%, while chest x ray had an accuracy of 76%. Lichtenstein et al¹⁶ showed that diagnostic accuracy of lung ultrasonography was 97% and 75% with chest x ray for alveolar consolidation in their study on 32 patients.

In our study, the ultrasound operator was not blind to the clinical presentation of the patients as the emergency physician himself had taken the clinical history, supported by the pulmonologist. Our study suggests that POCUS is an important diagnostic tool for the initial evaluation of critically ill patients with underlying pneumonia.

CONCLUSION

POCUS is a reliable tool for evaluation of lung parenchymal pathologies in the emergency department and is probably superior to bedside CXR as it may help emergency physicians in the diagnosis of pneumonia in its early stages where CT is not feasible. It could help in faster diagnosis and early initiation of appropriate treatment.

Declaration by Authors

Acknowledgement: None

Source of Funding: None

Conflict of Interest: The authors declare no conflict of interest.

REFERENCES

1. Brar NK, Niederman MS: Management of community-acquired pneumonia: A review and update. *Ther Adv Respir Dis.* 2011, 5:61-78. 10.1177/1753465810381518
2. Albaum MN, Hill LC, Murphy M, et al.: Interobserver reliability of the chest radiograph in community acquired pneumonia. *Chest.* 1996, 110:343-50. 10.1378/chest.110.2.343
3. Syrjala H, Broas M, Suramo I, et al.: High-resolution computed tomography for the diagnosis of community-acquired pneumonia. *Clin Infect Dis.* 1998, 27:358-63.
4. Lichtenstein DA: Ultrasound in the management of thoracic disease. *Crit Care Med.* 2007, 35:250-61. 10.1097/01.CCM.0000260674.60761.85
5. Ding W, Shen Y, Yang J, He X, Zhang M: Diagnosis of pneumothorax by radiography and ultrasonography: a meta-analysis. *Chest.* 2011, 140:859-66. 10.1378/chest.10-2946
6. Kurian J, Levin TL, Han BK, Taragin BH, Weinstein S: Comparison of ultrasound and CT in the evaluation of pneumonia complicated by parapneumonic effusion in children. *AJR Am J.* 2009, 193:1648-54. 10.2214/AJR.09.2791
7. Bechk S, Bölskei PL, Lessnau KD: Real-time chest ultrasonography: a comprehensive review for the pulmonologist. *Chest.* 2002, 122:1759-73. 10.1183/18106838.0202.136
8. Mathis G: Thorax sonography--Part II: Peripheral pulmonary consolidation. *Ultrasound Med Biol.* 1997,23:1141-53. 10.1016/s0301-5629(97)00112-9
9. Lichtenstein D: Lung ultrasound in the critically ill. In: *Yearbook of intensive care and emergency medicine.* Heidelberg: Springer, 2004. 625:44.
10. Soldati G, Copetti R, Sher S: Sonographic interstitial syndrome: the sound of lung water. *J Ultrasound Med.* 2009, 28:163-74. 10.7863/jum.2009.28.2.163
11. Agricola E, Bove T, Opp zi M, et al.: Ultrasound comet-tail images: a marker of pulmonary edema: a comparative study with wedge pressure and extravascular lung water. *Chest.* 2005, 127:1690-5. 10.1378/chest.127.5.1690
12. Weinberg B, Diakoumakis EE, Kass EG, et al.: The air bronchogram: sonographic demonstration. *AJR Am J Roentgenol.* 1986, 147:593-5. 10.2214/ajr.147.3.593
13. Lichtenstein D, Mezie`re G, Seitz J: The dynamic air bronchogram. A lung ultrasound sign of alveolar consolidation ruling out atelectasis. *Chest.* 2009, 135:1421-5. 10.1378/chest.08-2281
14. Cortellaro F, Colombo S, Coen D, Duca PG: Lung ultrasound is an accurate diagnostic tool for the diagnosis of pneumonia in the emergency department. *Emerg Med.* 2012:19-23. 10.1136/emj.2010.101584
15. EE Unluer, A Karagoz, GO Senturk, M Karaman, KH Olow, S Bayata: Bedside lung ultrasonography for diagnosis of

- pneumonia. Hong Kong j.emerg.med. 2013, 21:98-104. 10.1177/102490791302000205
16. Lichtenstein D, Goldstein I, Mourgeon E, Cluzel P, Grenier P, Rouby J J: Comparative diagnostic performances of auscultation, chest radiography and lung ultrasonography in acute respiratory distress syndrome. *Anesthesiology*. 2004, 100:9-15. 10.1097/00000542-20040100000006

How to cite this article: Ganesha BS, Anup Banur, Mahesh Krishnamurthy, Narendra SS. Evaluation of point of care ultrasound as a diagnostic tool for the diagnosis of pneumonia in emergency department. *Int J Health Sci Res*. 2023; 13(8):204-209.
DOI: <https://doi.org/10.52403/ijhsr.20230828>
