

# Rare Entity of Clear Cell Carcinoma Arising from the Soft Palate: A Case Report

I.A. Ide Larassanthi Pratiwi<sup>1</sup>, Yully Prapyatiningsih<sup>2</sup>

<sup>1,2</sup>Department of Otorhinolaryngology, Head and Neck Surgery, Bali Mandara General Hospital, Denpasar, Bali, Indonesia

Corresponding Author: I.A. Ide Larassanthi Pratiwi

DOI: <https://doi.org/10.52403/ijhsr.20230120>

## ABSTRACT

Clear cell carcinoma (CCC) is a rare minor salivary gland carcinoma, comprise 0.2%–1% of all salivary gland tumors. This particularly occurs in the minor salivary glands of oral cavity and oropharynx, the palate was the most common location. CCCs are most commonly asymptomatic as an indolent, painless, submucosal mass. The prognosis of CCC is generally good, with low locoregional recurrence after primary surgical management and relatively limited metastatic potential. The recommended standard of CCC treatment is complete local resection of tumor with a 0.5 cm to 2 cm considered sufficient and curative in most cases. We report a case of a 38 years old Balinese woman presented with painless lump in the soft palate. The tumor measured around 2 × 2 cm in diameter and diagnosed as CCC of salivary glands which is a rare finding. Local resection of the tumor done with safety margin and no reconstruction post-surgery needed. The patient was followed up regularly with excellent prognosis and with no signs of recurrence.

**Keywords:** Clear Cell Carcinoma, Soft palate, Minor salivary gland

## INTRODUCTION

Clear cell carcinoma (CCC) is one of the minor salivary gland tumor which is exceedingly rare making up <1% of all salivary gland tumors<sup>1</sup>, made up of clear cells, cords, and nests in a hyalinized stroma. Clear cell carcinoma (CCC) also referred to as Hyalinizing clear cell carcinoma (HCCC), associated with an EWSR1-ATF1 gene fusion.<sup>2</sup> The majority of CCCs present as a mass inside the oral cavity and are presumed to arise from minor salivary glands.<sup>3</sup> A minority can present as major salivary glands, nasopharyngeal or laryngeal tumors.<sup>3,4</sup> The most common intraoral sites are palate and tongue.<sup>5</sup> The diagnoses of these malignancies need special concern as they give diagnostic dilemma and misinterpretation. It is important to differentiate this entity from other more aggressive CCCs including

acinic cell carcinoma, mucoepidermoid carcinoma, epithelial-myoepithelial carcinoma, clear cell oncocytoma, sebaceous carcinoma, malignant myoepithelioma, odontogenic tumors and metastatic renal cell carcinoma, and polymorphous low grade adenocarcinoma. The biologic behavior of this entity is not well characterized because of the limited reported cases and relatively short follow-up.<sup>6</sup>

Most CCCs are frequently asymptomatic like painless, firm, non-tender mass, and therefore attain a substantial size without causing much discomfort. Few cases present as swelling, mucosal ulceration, or dysphagia.<sup>6</sup> The diagnosis of CCCs can be confirmed by CT scans, laboratory examination, and chest X-rays. However still primarily based on the histopathological features and added immunological studies.

The use of Periodic Acid Schiff (PAS) and immunohistochemistry, along with histological examination of the tumor can help to make a correct diagnosis, for identifying the typical features found in CCC.<sup>7</sup> Histologically, such tumors are characterized by the presence of clear cytoplasm caused by glycogen and with or without fibrosis and hyalinization of the tumor stroma.<sup>8</sup> As of now, the prognosis of CCC is excellent, and the mortality is rare. Complete surgical excision with a wide clear margin is the primary treatment with or without radiotherapy.<sup>9</sup> Radiotherapy reserved for patients with aggressive features, or local metastasis.<sup>10</sup> But local recurrence, nodal and distant metastasis of CCC are rare.<sup>11</sup> Here, we report a rare case of a CCC on female, which occurred on the palate and illustrated an indolent but locally infiltrative nature, which gives a false impression of poorly differentiated carcinoma.

### CASE REPORT

A 38 years old woman came to the ENT outpatient department at Bali Mandara Hospital with the chief complaint of feeling a lump in the right soft palate. This complaint began to appear about 6 months ago. The lump is felt to be getting bigger as the time goes. Complaints of pain and difficulty when swallowing, halitosis, hoarseness, ear pain, fever, cough, runny nose was denied by the patient. There are no other complications such as shortness of breath due to airway obstruction, and no

weight loss stated by the patient. Physical examination demonstrated a well-developed and well-nourished woman in no distress and no lump felt in the area around the neck. Past medical history, such as diabetes mellitus, hypertension, and other immunodeficiencies were denied by the patient. The patient did not take any medication while experiencing complaints since those 6 months ago. The occupation as a housewife causing most of her daily activities are indoors. None of the patient's family suffers from similar complaints, or have a history of other cancers. This patient has no history of smoking and drinking alcohol. The results of the physical examination found the mass or lump on the right side of soft palate close to the peritonsillar area, an enlarged mass that was more red or erythematous in color than the surrounding oropharyngeal mucosa, smooth surface, not prone to bleeding, and no exudate. No palpable enlarged lymph nodes. Laboratory tests in the form of complete blood count, bleeding time (BT) and clotting time (CT), random blood glucose, liver function test (Serum Glutamic Oxaloacetic Transaminase and Serum Glutamic Pyruvic Transaminase), kidney function test (urea and serum creatinine) and electrolytes. X-ray supporting examinations in the form of a CT scan of the Coli region with contrast, and photos of the posterior anterior chest radiograph. After the excisional Biopsy is performed, the tissue is examined pathologically and anatomically.

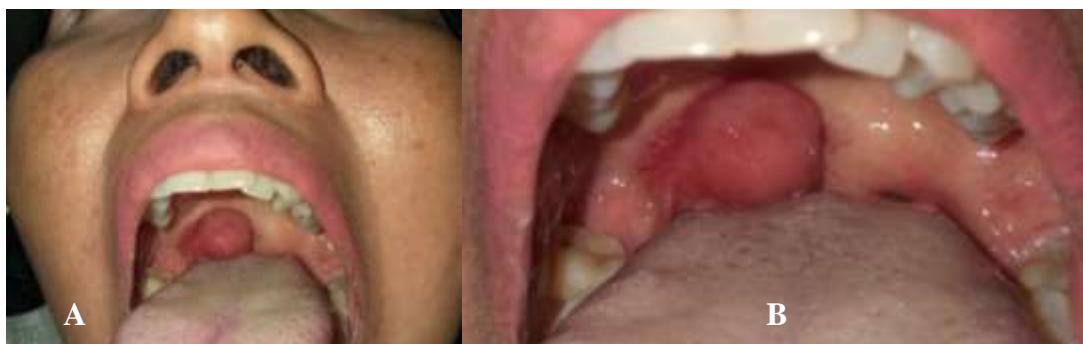

Figure 1. Pre-operative intra-oral clinical pictures. A) Revealed lesion in the right soft palate, B) The size of the lesion was around 2 × 2 cm

The laboratory examination showed no abnormalities were found from the results of the complete blood count, either from white blood cells, red blood cells, platelets (thrombocytes), hemoglobin and hematocrit, as well as other tests in the form of liver, kidney function test and electrolyte were still within normal limits. CT facial bones with contrast indicated a well defined focal lesion at the right side of the soft palate an inhomogeneous solid mass, clear

boundaries, relatively firm edges on the right soft palate, size ranges from 2.54 x 2.19 x 2.19 cm. There was no suspicious enlarged lymphnode in the right and left coli regions. No abnormality was seen in the brain parenchyma. The results of posterior anterior chest radiographs did not show any cancer cell metastases to the lungs and heart. Based on the clinical and radiological findings, a provisional diagnosis of a mass on the soft palate.

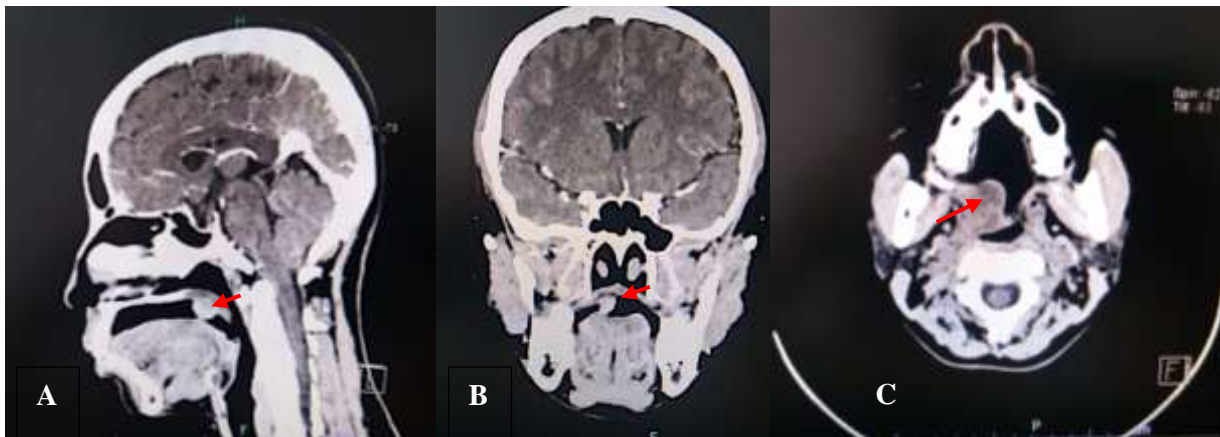


Figure 2. CT scan showed a mass of right soft palate in form of fullness of the right side with no signs of bony invasion. A) sagittal view, B) coronal view, C) axial view

An excisional biopsy was done under general anesthesia, as the wide local excision was meant to be diagnostic as well as therapeutic. The mass is located at the junction of soft palate and peritonsillar region, then the specimen was sent for histopathological investigation. Macroscopically, the tissue has been examined with 2.54 x 2.19 x 2.19 cm size, some surfaces are smooth and gray-brown. After the tissue is cut, the exposed surface

looks like a white mass fills the entire network in a definite margin. While in microscopic examination is a tissue that is partially covered by stratified squamous surface epithelium, some without surface epithelium. The tumor mass is surrounded by a fibrous connective tissue capsule, of varying thickness, composed of proliferating neoplastic cells that form solid, glandular-like, trabecular, and microcystic structures.

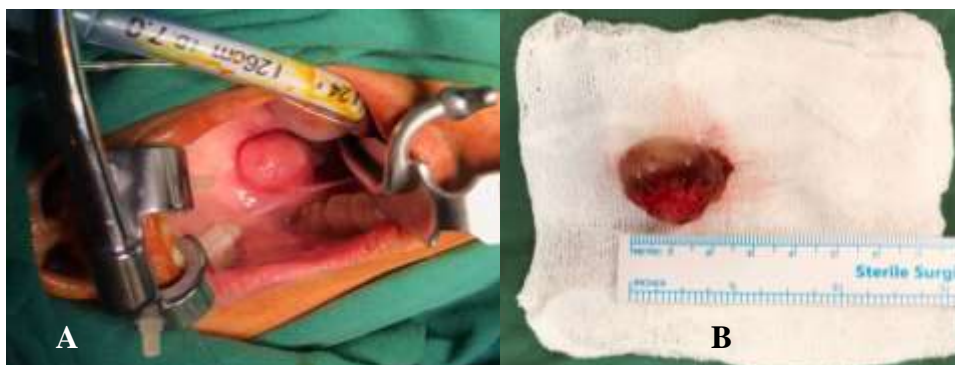

Fig 3. A) Intraoperative clinical pictures, B) The right soft palate mass size ranges from 2.54 x 2.19 x 2.19 cm

The microcystic structure contains thin eosinophilic amorphous material, some of which is visible between the more loosely arranged stroma. These neoplastic cells with round-oval morphology, some columnar, eosinophilic cytoplasm, pale, vacuolated, partially clear. The nucleus is round oval, relatively monotonous, with mild nuclear atypia, the nuclear membrane is irregular, some of the nuclei are visible. Some of these cell nuclei showed intranuclear inclusions. In one focus there was an invasion of the tumor mass through the capsule. Outside the tumor mass there is still a little remnant of lymphoid stroma and salivary glands.

Patient was followed regularly after the procedure with good postoperative results except for a little difficulty in producing voice but the voice improved significantly. The patient was seen in the first month postoperatively with good epithelization and fibrous band coverage. Despite the uvula deviation towards the surgical site which is due to the tissue pull during closure, the patient has no complains.

## **DISCUSSION**

Clear cell carcinoma (CCC) was first reported in 1994 by Milchgrub et al. as a rare minor salivary gland carcinoma.<sup>12</sup> The prevalence of minor salivary glands comprise 0.2%–1% of all salivary gland tumors.<sup>3</sup> Likewise, tumors of salivary gland are rare, represent 3-6% of all head and neck tumors, accounting for 0.3%-0.5% of all human malignancies. More than half of minor salivary gland tumors display malignant characteristics.<sup>13</sup> CCC is currently classified as a “clear cell adenocarcinoma” by AFIP fascicle and “clear cell carcinoma, not otherwise specified (NOS)” by the World Health Organization (WHO) “blue book” on head and neck tumors.<sup>2</sup> Females have been reported as the most common gender to have CCC, twice as often as men.<sup>3</sup> Based on the literature more than 60% of CCC occurs in middle aged women.<sup>14</sup> It is generally seen at fifth or sixth decades of life.<sup>5</sup>

This is particularly occurs in the minor salivary glands of the oral cavity and oropharynx.<sup>15</sup> A 2011 study reported that the palate is the most frequently affected site followed by the tongue and base of the tongue, then floor of the mouth. While the least encountered location is the buccal mucosa or vestibular mucosa.<sup>1</sup> A recent literature review on salivary gland CCC published between 1983 and 2020 also stated, from the 254 cases reported, the palate was the most common location.<sup>16</sup> In accordance to what the researchers found in this case report. CCCs are most commonly asymptomatic. The natural course of the lesion is an indolent, painless, submucosal mass.<sup>17,18</sup> However, some may present as swelling, mucosal ulceration, or dysphagia.<sup>9</sup> The prognosis of CCC is generally good, with low locoregional recurrence after primary surgical management, and relatively limited metastatic potential with low risk for distant metastasis. A careful observation and follow-up are needed, as an important factor to decide on the next treatment plan.<sup>9,19</sup> According to the reported cases in literature, CCCs has 17% recurrence rate after primary surgery and 21% metastatic rate.<sup>3,20</sup>

From the case we reported, the gender of the patient as well as the symptoms and visible manifestation of the tumor found were in accordance with the statements made by some literature. However, the age of the patient in this case did not match the epidemiology as reported from the findings of other cases. So this is a rare case for a young woman to be diagnosed with clear cell carcinoma of the soft palate.

Grossly, the tumor usually infiltrates into adjacent tissues, poorly circumscribed, and non-encapsulated. If it is being cut, then the surface area will have a white-tan to grey color with the average size ranging from 1.0 and 4.5 cm (mean 2.0–3.0 cm).<sup>2</sup> The microscopic diagnosis of CCC is very challenging because its microscopic appearance overlaps with that of salivary glands and other neoplasms which mostly show clear cells.<sup>18</sup> Histologically, CCCs can

be varied but tends to present as monotonous epithelial cells with variably clear cytoplasm arranged in thick trabeculae, nests, cords or solid sheets with a hyalinizing stroma.<sup>2,7</sup> The diagnosis of clear cell carcinoma is quite confusing in terms of clear cells which are similar to clear cell components in other neoplasms due to the lack of definite mucinous, squamous and myoepithelial differentiation. Differential diagnosis of CCC based on histopathology includes acinic cell carcinoma, mucoepidermoid carcinoma, epithelial-myoepithelial carcinoma, clear cell oncocytoma, sebaceous carcinoma, malignant myoepithelioma, odontogenic tumors and metastatic renal cell carcinoma, and polymorphous low grade adenocarcinoma. All of which show a significant proportion of clear cells.<sup>7,13</sup>

The use of special stains and immunohistochemistry, along with careful histological examination of the tumor, for identifying the typical features found in each of these neoplasms, help in arriving at a correct diagnosis. The special stain, PAS with and without diastase, shows variable amounts of PAS positive diastase sensitive material, representing glycogen polysaccharides and mucosubstances demonstrates polysaccharides, mucin, glycogen, glycoproteins and glycolipids, in the tissue of the tumor cells.<sup>7</sup> The tumor cells in acinic cell carcinoma are PAS positive, diastase resistant, and contain zymogen granules. The mucoepidermoid carcinoma characterized by intermediate and epidermoid cells, mucous, clear cell or oncocytoid features, which carcinoma's clear cell contain mucin in the cytoplasm and positive with mucicarmine stain. Neoplastic cells in epithelial-myoepithelial carcinoma express positive S-100 and smooth muscle antigen. clear cell oncocytoma express PAS positive which contain glycogen, while the oncocytic cells contain considerable mitochondria, with phosphotungstic acid hematoxylin stain. Sebaceous carcinoma shows clear cytoplasm and is demonstrated by fat stain

on frozen tissue. The odontogenic carcinoma with clear cells can be differentiated from CCC by biphasic growth pattern, also positive expression of cytokeratin and S-100.<sup>5,9</sup> Renal cell carcinoma have a high degree of vascularity and pronounced atypia in addition to the lack of prominent hyaline stroma.<sup>4,17</sup> Reciprocally, neoplastic cells in renal cell carcinoma co-express with cytokeratin and vimentin. Radiological imaging studies are also helpful in excluding the possibility of metastatic renal cell carcinoma. Based on the Immunohistochemistry of each neoplasia mentioned above, it is different from the results which are not found in CCC whereas neoplastic cells in CCC are negative for epithelial markers especially cytokeratins, vimentin, S-100 and smooth muscle antigen.<sup>12,21</sup>

Because these CCC tumors are rare, there is no clear, standardized treatment protocol. Even with inadequate data, surgical excision appears to be the treatment context for this tumor.<sup>22</sup> The recommended standard of CCC treatment is complete local resection of the tumor with a 0.5 cm safe margin.<sup>16</sup> However, other literatures suggests that wide local excision with a safe margin of 1 to 2 cm is considered sufficient and curative in most cases. There is still controversy both regarding the safe margin of appropriate surgery, as well as the role of radiotherapy and management of the neck.<sup>22</sup> The efficiency of chemotherapy and radiotherapy may be useful only in cases with postoperative recurrence, positive tumor resection margins or inaccessible surgical sites. In addition, cases of CCC located in palatal region, because of the proximity of the tumor to the maxillary sinus, floor of the nose and pharynx, reconstruction may be required after excision to prevent oral-nasal fistula or interference with voice, saliva production and swallowing. If a palatal hole occurs after excision of the tumor which creates a connection between the oral and nasal cavities, then reconstruction with buccal fat can be performed to close the defect and

restore the contour of the palatal area. Surgical flap reconstruction is not required. In this case report, the standard surgical treatment of complete local excision with safe margins of surgery was followed appropriately and no reconstruction was performed due to the absence of tissue reduction at the initial site of the tumor after surgery.

## CONCLUSION

Clear cell carcinoma (CCC) which is a rare salivary gland tumor and asymptomatic occurs generally more in female than male and in middle aged woman around fifth and sixth decades of life. The most common tumor location is the oral cavity, especially the palate and tongue. In this case report we declare a female patient in her late 30s with clear cell carcinoma on the soft palate. Based on gender, tumor specification and location in accordance with the studies conducted by other researchers. However, the patient's age which is relatively young compared to what is usually reported makes this case very rare, apart from the number of cases with CCC that are rarely found. The diagnosis is confirmed by biopsy results, CCC usually challenging as it can be clinically confused with other benign neoplasms, whereas histologically, there are several differential diagnoses. The treatment is complete excision of the tumor without continuing with flap reconstruction in the excision area. The tumor management is in line with the reported studies, where there is no standardized protocol. Postoperative radiotherapy was not performed, only if there is tumor recurrence.

## Declaration by Authors

**Acknowledgement:** None

**Source of Funding:** None

**Conflict of Interest:** The authors declare no conflict of interest.

## REFERENCES

1. Kauzman A, Tabet JC, Stiharu TI. Hyalinizing clear cell carcinoma: a case report and review of the literature. *Oral Surg Oral Med Oral Pathol Oral Radiol Endod.* 2011 Jul;112(1):e26-34.
2. Weinreb I. Hyalinizing Clear Cell Carcinoma of Salivary Gland: A Review and Update. *Head Neck Pathol.* 2013;7(SUPPL 1):20-9.
3. Jayasree L, Srinivasamurthy P, Jayalekshmi R, Bhat S. Clear cell carcinoma of hard palate: A rare case report. *J Indian Acad Oral Med Radiol.* 2016;28(3):324-8.
4. Masilamani S, Rao S, Chirakkal P, Kumar AR. Hyalinizing clear cell carcinoma of the base of tongue: a distinct and rare entity. *Indian J Pathol Microbiol.* 2011;54(1):167-9.
5. Yaşar M, Günerİ E, Karaman H, Aytekin A. Clear Cell Carcinoma at Soft Palate Yumuşak Damakta Şeffaf Hücreli Karsinom. 2016;24(1):13-6.
6. Rana S, Zeeba JS, Raina PK, Jetley S. Case Report Clear Cell Carcinoma of Minor Salivary Gland Origin : A Case of Mistaken Identity. (Figure 1):178-80.
7. Zahra AF, Amina B, Ali YM, Zenab A, Touria B, Khalid H. Hyalinizing clear cell carcinoma of tonsil: About a case report and review of the literature. *Onkol i Radioter.* 2019;46(1):64-8.
8. Chatterjee, Nimrat Walker G, Lucia MS HK and TJDC, et al Hyochol Ahn 2017. 乳鼠心肌提取 HHS Public Access. *Physiol Behav.* 2017;176(10):139-48.
9. O'Sullivan-Mejia ED, Massey HD, Faquin WC, Powers CN. Hyalinizing clear cell carcinoma: report of eight cases and a review of literature. *Head Neck Pathol.* 2009 Sep;3(3):179-85.
10. Su HK, Wang BY, Mannan AASR, Dewey EH, Alpert EH, Reis LL Dos, et al. Very delayed cervical lymph node metastases from hyalinizing clear cell carcinoma: report of 2 cases. *Head Neck.* 2015 Feb;37(2):E19-21.
11. Jin R, Craddock KJ, Irish JC, Perez-Ordóñez B, Weinreb I. Recurrent Hyalinizing Clear Cell Carcinoma of the Base of Tongue with High-Grade Transformation and EWSR1 Gene Rearrangement by FISH. *Head Neck Pathol [Internet].* 2012;6(3):389-94. Available from: <https://doi.org/10.1007/s12105-012-0338-7>
12. Milchgrub S, Gnepp DR, Vuitch F, Delgado R, Albores-Saavedra J. Hyalinizing clear

- cell carcinoma of salivary gland. *Am J Surg Pathol.* 1994 Jan;18(1):74–82.
13. Safuraa SI, Doi M, Adzman S, Sethu S. Hyalinizing clear cell carcinoma of the soft palate - A case report. *Malaysian J Med Heal Sci.* 2020;16(1):333–5.
  14. Alshehry S, Alnofaie H, Almusallam M, Alshuaibi H, Alodaini A. Clear cell carcinoma of soft palate in a young patient: A case report. *Oral Maxillofac Surg Cases [Internet].* 2022;8(3):100260. Available from: <https://doi.org/10.1016/j.omsc.2022.100260>
  15. Suzuki H, Katoh A, Udaka T, Shiomori T, Fujimura T, Fujimura K, et al. Hyalinizing clear cell carcinoma arising from the base of the tongue. *Acta Otolaryngol [Internet].* 2006 Jan 1;126(6):653–6. Available from: <https://doi.org/10.1080/00016480500452509>
  16. Desai A, Faquin WC, Iafrate AJ, Rivera MN, Jaquinet A, Troulis MJ. Clear cell carcinoma: a comprehensive literature review of 254 cases. *Int J Oral Maxillofac Surg.* 2022 Jun;51(6):705–12.
  17. Saleh KA, Nurishmah MI, Firouzeh GN, Goh BS. Primary clear cell carcinoma of minor salivary gland of the soft palate: a case report. *Med J Malaysia.* 2012 Jun;67(3):335–6.
  18. Bhamjee F, Jeftha A, Holmes H, Roberts R, Roberts T. Hyalinising clear cell carcinoma of the maxilla in a young adult female. *South African Dent J.* 2018;73:86–8.
  19. Solar AA, Schmidt BL, Jordan RCK. Hyalinizing clear cell carcinoma: case series and comprehensive review of the literature. *Cancer.* 2009 Jan;115(1):75–83.
  20. Agrawal J, Kumar YP, Damera DA, Kumar S. Clear cell carcinoma of minor salivary gland: A case of clinical dilemma. Vol. 5, *Contemporary clinical dentistry.* India; 2014. p. 389–92.
  21. Chao TK, Tsai CC, Yeh SY, Teh JEK. Hyalinizing clear cell carcinoma of the hard palate. *J Laryngol Otol.* 2004 May;118(5):382–4.
  22. O'Regan E, Shandilya M, Gnepp DR, Timon C, Toner M. Hyalinizing clear cell carcinoma of salivary gland: an aggressive variant. *Oral Oncol.* 2004 Mar;40(3):348–52.

How to cite this article: I.A. Ide Larassanthi Pratiwi, Yully Prapyatiningsih. Rare entity of clear cell carcinoma arising from the soft palate: a case report. *Int J Health Sci Res.* 2023; 13(1):142-148.  
DOI: <https://doi.org/10.52403/ijhsr.20230120>

\*\*\*\*\*